

Current Concepts in the Presentation, Diagnosis and Management of Primary Hyperparathyroidism

Amal Alhefdhi*

Department of Surgery, Section of Endocrine Surgery, University of Wisconsin, USA

Abstract

Background: Primary hyperparathyroidism (PHPT) is a common clinical endocrine disorder. It is the most common cause of hypercalcemia in the outpatient setting. This review presents a brief summary of the new trends of presentation, diagnosis and management PHPT.

Data Sources: PubMed (National Library of Medicine) articles, and Memorial Library archives of the University of Wisconsin System.

Conclusions: PHPT occurs at any age, but it is most commonly seen in people over the age of 50 years and postmenopausal women. The current presentation of PHPT shifts from the classical symptomatic form to the asymptomatic form; however, parathyroidectomy is still the treatment of choice for both symptomatic and asymptomatic forms. In the past, bilateral neck exploration and intraoperative identification of all 4 parathyroid glands was the standard of treatment, nevertheless, nowadays, with the introduction of the preoperative and intraoperative localization techniques, the minimally invasive parathyroidectomy has evolved.

Keywords: Primary Hyperparathyroidism; Presentation; Diagnosis; Management

Introduction

Primary hyperparathyroidism (PHPT) is defined by an abnormal increase in the intrinsic activity of the parathyroid gland(s) that result in elevated parathyroid hormone (PTH) levels [1,2]. It is one of the most common endocrine disorders and is the most common cause of hypercalcemia. PHPT is one of the most common endocrine disorders and is the most common cause of hypercalcemia, which increases morbidity and mortality that result from cardiovascular, renal, and musculoskeletal pathologies. PHPT affects 1 in 500 females and 1 in 2,000 males aged >40 years, with a peak incidence in post-menopausal women. In the US, Europe, and Australia, the reported estimated incidence rates range from 25 to 30 per 100,000 person years, and the prevalence range from 1 to 21 per 1,000 individuals [1-4].

PHPT has been a recognizable disease since the 1920s in both Europe and the US [5]. The first parathyroidectomy was performed in 1925 by Felix Mandl in Vienna, Austria; since then, the diagnosis and management of PHPT have progressed [5]. The purpose of this article is to review the current trends of PPT presentation, work-up, and management.

Anatomy and Physiology

Humans typically have four parathyroid glands located at the posterior capsule of the thyroid gland; in up to 15% of individuals have more than four and up to 3% have three identifiable glands [6]. The superior parathyroid glands arise from the IV pharyngeal pouch and migrate to the cephalad thyroid gland; they are usually located at the cricothyroid junction, 1 cm from the recurrent laryngeal nerve and the inferior thyroid artery. Inferior parathyroid glands arise from the III pharyngeal pouch and migrate caudally with the thymus; they are usually located on the posterolateral aspect of the inferior pole of the thyroid gland. Normal parathyroid glands are yellow or brown in color, oval in shape, 3–7 mm in length, and 30–40 mg in weight [7,8].

A parathyroid gland consists of chief cells, oxyphilic cells, a thin fibrous capsule, and a network of adipose tissue, blood vessels, and

glandular parenchyma [8]. Chief cells secrete PTH, which consists of 84 amino acid polypeptides. The normal serum PTH level range is 15–72 pg/mL, with a half-life of 2–4 min. Seventy percent of PTH metabolism occurs in the liver and 30% in the kidneys [9-11]. PTH is regulated by serum calcium, phosphorus, and vitamin D metabolites. The total normal calcium level should be 8.8–10.2 mg/dL (ionized calcium 2.2–2.6 mmol/L) to ensure optimum physiological functions [9-11]. PTH levels are inversely proportional to serum calcium levels, as high serum calcium levels decrease PTH release [5-7] and low serum calcium levels increase PTH secretion. This relationship enhances renal tubular calcium reabsorption, urinary phosphate excretion, osteoclast-mediated bone resorption, and the conversion of 25-hydroxyvitamin D3 into 1,25-hydroxyvitamin D3, which increases calcium absorption from the bowel [9-11].

Etiology

Ninety-five percent of PHPT cases are sporadic. Of these cases, 75–85% result from a single adenoma, 2–12% result from double adenomas, 10–15% result from multiple gland hyperplasia, and <1% result from parathyroid carcinoma [12-14]. Patients with multigland disease tend to have PTH levels of <100 pg/mL, a negative preoperative localization, or several neurocognitive symptoms [15,16]. Serum calcium levels of >14 mg/dL (3.5 mmol/L) or a palpable neck mass with elevated PTH may indicate parathyroid carcinoma [17]. Familial endocrine disorders occur in approximately 5% of PHPT cases and

***Corresponding author:** Amal Alhefdhi, Section of Endocrine Surgery, Department of Surgery, 3028 Wisconsin Institutes of Medical Research University of Wisconsin, 1111 Highland Avenue, Madison, WI 53705, USA, Tel: +1 608-263-1387; Fax: +1 608-252-0912; E-mail: alhefdhi@surgery.wisc.edu

Received July 31, 2014; **Accepted** December 31, 2014; **Published** January 04, 2015

Citation: Alhefdhi A. Current Concepts in the Presentation, Diagnosis and Management of Primary Hyperparathyroidism. Journal of Surgery [Jurnalul de chirurgie] 2015; 11(1): 305-312 DOI: [10.7438/1584-9341-11-1-1](https://doi.org/10.7438/1584-9341-11-1-1)

Copyright: © 2015 Alhefdhi A. This is an open-access article distributed under the terms of the Creative Commons Attribution License, which permits unrestricted use, distribution, and reproduction in any medium, provided the original author and source are credited.

frequently present in younger populations with a positive family history of neuroendocrine tumors or hypercalcemia (Table 1). Patients with inherited hyperparathyroidism and multigland disease have a higher risk of persistent and recurrent disease [14].

Head and neck radiation increase the risk of developing PHPT by two- to three-fold [18]. Additionally, the use of thiazides may lead to mild hypercalcemia by reducing urinary calcium excretion, and the use of lithium may lead to increased serum calcium and PTH by decreasing the sensitivity of the calcium-sensing receptor to calcium [19,20]. Although the pathogenesis of PHPT is not well known, studies have shown that gene mutations, growth factors, calcium-sensing receptor antibodies, and chronic vitamin D deficiency are possible underlying pathologies [20].

Presentation and Clinical Forms

Patients may present with symptoms of hypercalcemia or PTH excess or they may be asymptomatic; however, the severity of hypercalcemia is not directly linked to the severity of symptoms [21]. Symptomatic PHPT has been linked to the classic aphorism of “stones, bones, groans, and psychiatric overtones.” However, asymptomatic PHPT is linked to high serum calcium levels in routine biochemical evaluation, in which patients present in early stages before the development of classic symptoms of PHPT [12]. The most common presentations of PHPT are hypercalciuria, which are seen in almost 40% of PHPT patients, and kidney stones, which have an incidence of 15–20%. Other renal presentations of PHPT include nephrocalcinosis, polyuria, and reduced creatinine clearance (CrCl) [22,23]. Additionally, patients may have low bone mineral density (BMD) in their cortical bones. Almost 15% of patients have vertebral osteopenia and 2% have osteitis fibrosa cystica. PHPT may be associated with rheumatic conditions, such as gout and pseudogout [24,25].

Patients may develop gastrointestinal symptoms, such as nausea, constipation, peptic ulcers, and pancreatitis [26], or neuropsychiatric symptoms, such as depression, dementia, confusion, lethargy, social function impairment, psychosis, and coma [27]. Patients with PHPT have a higher prevalence of hypertension, cardiac and coronary artery calcification, left ventricular hypertrophy, conduction abnormalities, glucose intolerance, endothelial dysfunction, and abnormalities in the coagulation and fibrinolysis pathways [28,29]. In pregnant women, PHPT increases the risk of preeclampsia and fetal defects, such as intrauterine growth retardation, low birth weight, preterm delivery, intrauterine fetal death, neonatal tetany, and permanent hypoparathyroidism [30]. Because of the routine use of screening tests and BMD measurements, 80% of PHPT cases are asymptomatic or present with nonspecific symptoms, such as fatigue, mild depression, bone pain, weakness, memory loss, decreased concentration, and sleep problems [12].

Several clinical forms of PHPT exist, according to severity. Classic PHPT is characterized by the elevation of both calcium and PTH, and patients usually have typical symptoms [1,12]. Mild PHPT is characterized by elevated PTH or calcium in isolation, mild elevations in both, or asymptomatic disease, and is associated with smaller adenomas and a higher incidence of multigland disease. Normocalcaemic PHPT is characterized by elevated PTH and normal serum calcium [12,31,32].

Differential Diagnosis and Work-up

Hypercalcemia has several causes (Table 2), but malignancy is the second most common cause [19]. The diagnosis of PHPT is usually made biochemically, based on serum calcium, PTH, and phosphate levels. Elevated levels of serum calcium and PTH are associated with a 95% risk of a diagnosis for classic PHPT; however, patients may have normal levels of phosphate, calcium or PTH. Serum calcium levels

should be repeated and all cofactors should be controlled. Normal ionized serum calcium, elevated PTH levels, and no signs of secondary hyperparathyroidism are consistent with normocalcemic PHPT [31-36]. Undetectable PTH levels rule out PHPT, but raise the possibility of cancer-associated hypercalcemia, while elevated PTH levels in a patient with a malignant condition suggest concomitant PHPT (Figures 1 and 2). Administration of oral calcium will suppress PTH in patients with secondary hyperparathyroidism [32-36].

In addition, serum 25-hydroxyvitamin D, CrCl, chloride, protein electrophoretic pattern, alkaline phosphatase, creatinine, uric acid and urea nitrogen, urinary calcium, blood hematocrit, serum magnesium, and erythrocyte sedimentation rate are valuable for diagnosis [36]. Elevated serum chloride is found in approximately 50% of patients with PHPT because PTH decreases the resorption of bicarbonate in the proximal renal tubule, thus increasing the resorption of chloride [36]. Plain-film radiography of the skeleton is not recommended; however, BMD should be evaluated by a dual-energy X-ray absorptiometry scan of the lumbar spine, hip, and distal radius [37]. Moreover, renal ultrasonography or computed tomography (CT) scanning is recommended if the history suggests nephrolithiasis [32-35]. Genetic testing should be considered only in patients with recurrent disease, multiple gland involvement, a young age, a family history of PHPT or multiple endocrine neoplasia (MEN), or other features of MEN, to rule out genetic disorders [32-35]. Furthermore, according to the National Institutes of Health (NIH) guidelines, a 24-h urine collection to measure calcium and creatinine is no longer required for all patients, although it should be obtained if a concern for familial hypercalcemic hypocalciuria (FHH) exists, as these patients do not benefit from parathyroidectomy [33-35]. Patients with FHH are typically asymptomatic and have mild hypercalcemia and a positive family history of hypercalcemia [38]. A 24-h urine calcium of less than 100 mg/L or a calcium-to-CrCl ratio of 0.01 is consistent with FHH [39]. Calcium Sensing Receptor (CASR) DNA sequencing test can be considered to confirm or rule out a suspected diagnosis of FHH [40].

Localization Techniques

Preoperative localization techniques should not be used to confirm the diagnosis of PHPT, but should be considered to guide the endocrine surgeon intraoperatively, to evaluate for ectopic glands, and to assist in the planning of minimally invasive parathyroidectomy (MIP) [40]. Nuclear (sestamibi) imaging using 99m technetium (99mTc) is considered to be the standard technique for preoperative imaging of parathyroid glands. In a dual-phase technique with 99mTc sestamibi imaging, both the thyroid tissue and abnormal parathyroid tissue incorporate 99mTc sestamibi quickly after intravenous administration. Hyperactive parathyroid tissue has a slower washout rate compared with thyroid tissue. Recently, 99mTc tetrofosmin was introduced, with similar imaging protocols as 99mTc sestamibi, but with a slightly different mechanism of accumulation in tissues. The 99mTc sestamibi protocol has a sensitivity of 70–90%, and is may be affected by underlying biochemistry, vitamin D deficiency, pedunculated adenomas, mobile adenomas, superiorly located adenomas, thyroid nodules, the small adenomas, and thyroid suppression before imaging [41-43].

Several retrospective studies found that sestamibi scans are a useful preoperative localization tool for PHPT, especially in cases caused by a single adenoma. These studies reported that surgeon interpretation and radiology experience increased the likelihood of localization [44,45-47]. The authors recommend that sestamibi scans be reviewed by experienced parathyroid surgeons, rather than relying on radiological interpretation alone [45-47]. Anderson et al. reported 62% sensitivity and 83% specificity of radiological interpretations [45]. Chen et al. reported that the sensitivity of the surgeon (93%) was higher than both high-volume (83%) and low-volume (72%) radiologists [46]. Neychev

Table I: Genetic Mutations of Familial Hyperparathyroidism Disorders

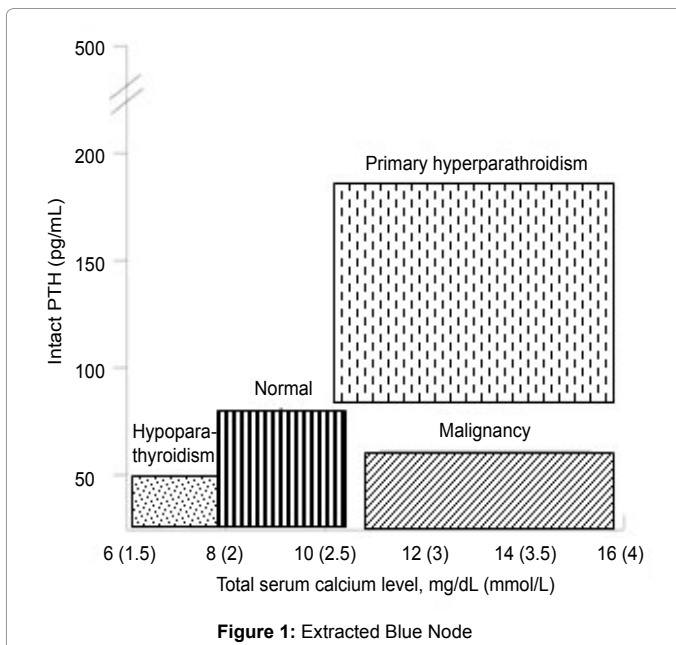
Disorder	Type of inheritance	Gene	Chromosomal Location	Protein
MEN1	AD	MEN1	11q13	Menin
MEN1- variant	AD	CDKN1B/p27	12p 12-13	
MEN2A	AD	RET	10q2110q11.2	Receptor tyrosine Kinas
HPT-JT	AD	HRPT2	1q21-q321q25	Parafibromin
FIHPT	AD	HRPT2 MEN1	1q21-q3211q132p13.3-14	Parafibromin
ADMH	AD	CASR	3q13-21	Calcium-sensing receptor
FHH	AD	CASR	3q13-21	Calcium-sensing receptor
NSHPT	AR/AD	CASR	3q13-21	Calcium-sensing receptor

Abbreviations: MEN1, multiple endocrine neoplasia type 1 gene; MEN2A, multiple endocrine neoplasia type 2 gene; HPT-JT, hyperparathyroidism-jaw tumor syndrome; FIHPT, familial isolated hyperparathyroidism; ADMH, autosomal dominant moderate hyperparathyroidism; FHH, familial hypocalciuric hypercalcemia; NSHPT, neonatal severe hyperparathyroidism; AD, autosomal dominant; AR, autosomal recessive; CDKN1B/p27, cyclin-dependent kinase inhibitor 1B (p27Kip1); RET, RET proto-oncogene; HRPT2, hyperparathyroidism 2 gene; CASR, calcium-sensing receptor gene.

Table II: Causes of Hypercalcemia

Category	Disorder	Comments
Parathyroid Dependent	Primary hyperparathyroidism	Sporadic, or familial
	Tertiary hyperparathyroidism	Chronic renal failure or vitamin D deficiency
PTH Independent	Vitamin intoxication	Vitamin A or D intoxication
	Granulomatous disease	Sarcoidosis, berylliosis, tuberculosis
	Malignancy	Humoral hypercalcemia of malignancy mediated by PTHrP, especially lung, head, and neck squamous cancers, and renal cell tumors
		Local osteolysis, mediated by cytokines like multiple myeloma, and breast cancer
		Hodgkin's lymphoma
	Medications	Thiazide diuretics, or lithium
		Calcium antacids (Milk-alkali syndrome)
	Other hormone-related	Hyperthyroidism, adrenal insufficiency, acromegaly, or pheochromocytoma
	Genetic disorders	Familial hypocalciuric hypercalcemia
	Other	Immobilization, with high bone turnover, Paget's disease, bedridden child
Recovery phase of rhabdomyolysis		
	Parenteral nutrition	

Abbreviations: PTHrP, parathormone related peptide



et al. reported a sensitivity of 58.6% for nuclear medicine physicians, compared with 81.9% for both a surgeon and a nuclear medicine physician [47].

Parathyroid ultrasonography is an accessible, inexpensive, and noninvasive test. Using a linear ultrasound transducer with a frequency of 7.5–10 MHz, it localizes enlarged parathyroid glands and evaluates

the thyroid gland to rule out any synchronous thyroid disease. Normal parathyroid glands cannot be visualized by ultrasonography, but parathyroid adenomas appear as hypoechoic or anechoic, discrete, and oval homogenous hypervascular solid masses. Larger adenomas may show cystic changes, lobulations, occasional calcifications, and increased echogenicity because of fat deposition. However, the sensitivity of ultrasonography fluctuates between 22% and 80%, because it is user dependent and limited in its ability to localize retroesophageal, retrotracheal, retrosternal, intrathyroidal, mediastinal, small, and deep cervical glands [41,48,49]. Vitetta et al. found that sonography performed by an expert was associated with an appreciably superior diagnostic yield than 99mTc sestamibi [50]. Thus, ultrasound can be used as the main method for preoperative localization of pathological parathyroid tissues [50].

Classic CT is limited in imaging parathyroid adenomas, but four-dimensional parathyroid CT (4DCT), in which four phases are used to identify parathyroid lesions, can provide anatomical and functional information on the parathyroid gland. CT scans identify parathyroid adenomas in 90% of the cases. While false-positive findings can be seen for thyroid nodule, tortuous vessel, or laterally displaced esophagus, false-negative results can be seen in cases of small or ectopic adenomas or distorted neck anatomy due to previous surgery. However, ionizing radiation is a limitation of 4DCT for routine localization of parathyroid disease; thus, it should be used selectively in patients whose parathyroid glands are not localized on routine imaging. Single-photon emission CT (SPECT) can help to differentiate the parathyroid gland from thyroid tissue, with a sensitivity of 87% for solitary adenomas, 30% for double adenomas, and 44% for multigland disease. Research shows that a combination of SPECT and CT with various dual-phase imaging can boost the accuracy of localization [43,51,52].

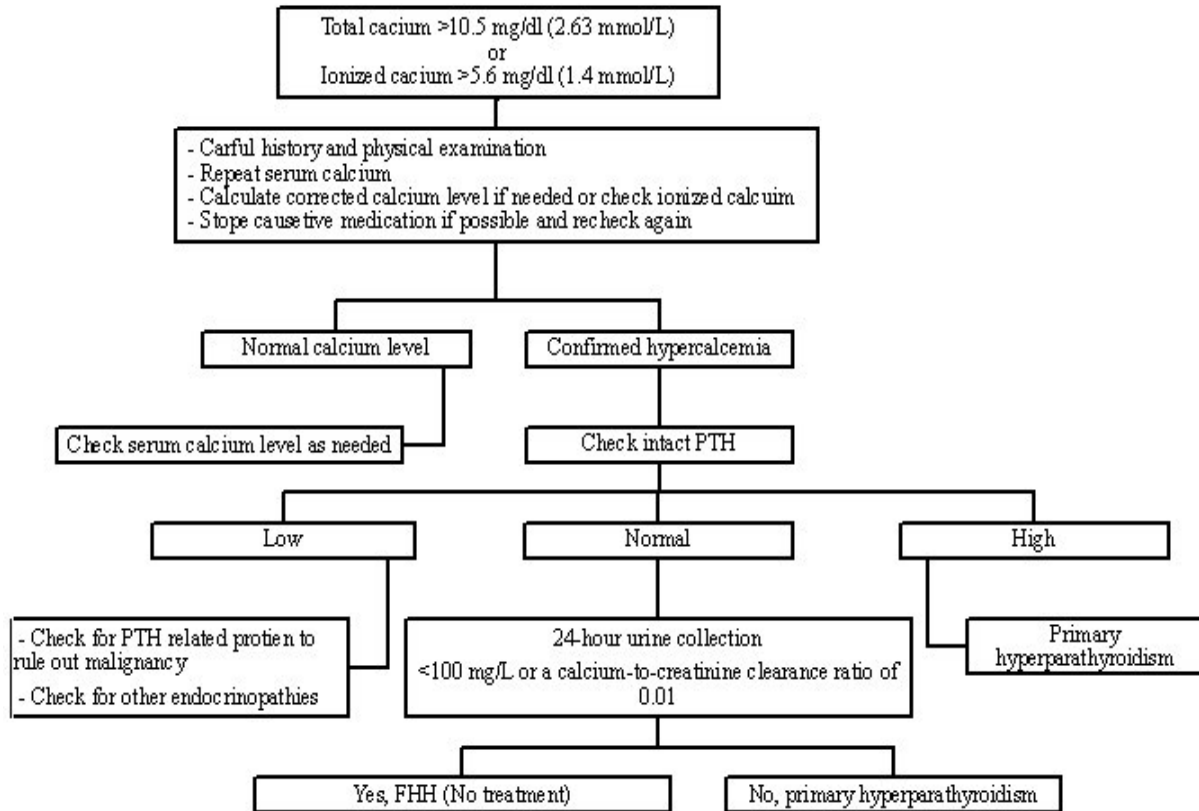


Figure 2: Evaluation of Hypercalcemia

Magnetic resonance imaging (MRI) is a good choice for imaging if there is a possible concern for radiation exposure or nephrotoxicity. Typical MRIs involve axial images of the neck and mediastinum. While normal parathyroids are usually not detected on MRI images, parathyroid adenomas are seen as soft-tissue masses, with low-to-medium signal intensity on T1-weighted images and high signal intensity on T2-weighted images. After gadolinium contrast administration, abnormal parathyroid glands show a strong enhancement on T1-weighted images that are similar to conventional T2-weighted imaging [42].

Parathyroid arteriography and parathyroid venous sampling are invasive tests that should be offered only when the results of noninvasive methods are negative. On angiograms, parathyroid adenomas appear as hypervascular oval lesions with smooth margins. Selective PTH venous sampling can be drawn to localize the hyperactive parathyroid gland. A gradient of at least two-fold in PTH levels confirms the location of hyperactive parathyroid tissue. Intraoperatively, a similar selective technique can be performed to localize the hypersecreting parathyroid gland and/or confirm curative surgical resection [53-55].

The IoPTH assay is used to determine the appropriateness of a parathyroid tissue resection [56,57]. Numerous criteria have been suggested to confirm the sufficiency of parathyroid resections [58]; however, the most widely accepted is the Miami criterion. With a 97% accuracy rate, IoPTH is measured based on a 50% drop from an initial PTH level reading to the level measured 10 min after gland excision. When PTH levels remain elevated after an excision of the suspected gland, a bilateral neck exploration may be necessary to locate the remaining hypersecreting tissue [56,57]. The IoPTH test is also reliable in mild cases, even if PTH is not elevated [59].

Management

Patients with serum calcium levels of 12.14 mg/dL (3.35 mmol/L)

may not require immediate treatment if this elevation is chronically well tolerated. However, an acute rise in calcium levels may lead to dehydration or cardiovascular or neurologic complications, which require more aggressive measures. In addition, patients with serum calcium levels of >14 mg/dL (3.5 mmol/L) require treatment, regardless of symptoms. Thus, patients with severe hyperparathyroidism-induced hypercalcemia should be hospitalized, and urinary catheterization and central venous pressure monitoring should be considered. Initial treatment should include intravenous saline solution to gradually replace lost fluids and increase urinary calcium excretion [2,33,34,40,60,61]. Once fluid repletion is accomplished, loop diuretics may be used to decrease renal calcium reabsorption and promote urinary excretion. Calcitonin 200 IU once every 8 h may help to decrease albumin-adjusted calcium. Bisphosphonates, corticosteroids, calcium chelators, or dialysis are occasionally indicated in severe cases [2,33,34,40,60,61]. Patients must be closely monitored for complications caused by aggressive diuresis, including hypokalemia, hypomagnesemia, and acute renal insufficiency [2,33,34]. However, parathyroidectomy is the only curative therapy, with a success rate of 95-98% [40,41]. To prevent the progression of systemic complications of PHPT, parathyroidectomy should be performed as soon as the patient is diagnosed. Parathyroid surgery is successful if calcium levels remain normal after 6 months [2,33,34,40,60,61].

All patients with symptomatic PHPT, significantly elevated calcium levels, kidney or bone disease, or parathyroid cancer should be considered for surgery [33,34,40,60]. In asymptomatic PHPT, parathyroidectomy is a suitable treatment for patients with no contraindications to surgery. However, the NIH's 2008 modified guidelines recommend surgery for asymptomatic patients who have a serum calcium that is >1.0 mg/dL (0.25 mmol/L) above the upper limit of normal, a CrCl of <60 mL/min, a T-score of ≤ 2.5 at any site, a previous low-trauma fracture, or an age of <50 years [2,33,34,40,59]. Conversely, Macfarlane et al. [62]

discussed the guidelines' consequences and reviewed the available data showing that patients with normocalcemic hyperparathyroidism have a low risk of progression to overt disease; however, the patients' long-term risks were not well defined. In fact, the authors found that studies to suggest that asymptomatic PHPT patients have a higher incidence of cardiovascular morbidity and mortality, which might be predicted by PTH levels. Furthermore, the authors proposed that surgery decreases fracture risk and can improve neuropsychological symptoms, and concluded that long-term, randomized, controlled trials are needed to support the safety of medical surveillance are needed to support the safety of medical surveillance and some patients' progress with time [62].

Surgical options

Either general or local anesthesia can be used for patients undergoing parathyroidectomy. Local anesthesia, via a subcutaneous injection of 1% lidocaine over the intended incision and along the anterior and the posterior borders of the sternocleidomastoid muscle, ipsilateral or bilateral, is used for patient preference or comorbidities. For complications such as technical complications or toxic reactions to lidocaine, unexpected findings, or patient discomfort, general anesthesia should be considered [40-42,60,63].

Parathyroidectomy may be performed using different techniques, and either general or local anesthesia can be used. The standard procedure for PHPT is bilateral neck exploration, performed under general anesthesia, which is the best choice for patients with inherited hyperparathyroidism or multigland disease. Subtotal parathyroidectomy (i.e., removal of 3.5 glands) or total parathyroidectomy with autotransplantation of parathyroid tissue at a distant site (e.g., the forearm or sternocleidomastoid muscle) may be performed. A transverse incision of 2-4 cm in length above the sternal notch is made, following the skin lines across the anterior neck. The tracheoesophageal groove, the paraesophageal area, the carotid sheath, and the thymus should be explored if a gland is missing. Cervical thymectomy can be performed if a gland is missing in the first surgery, but mediastinum exploration should only be performed in patients who have a gland clearly localized to the mediastinum [40,60,64].

MIP allows patients to undergo focused parathyroidectomy and has the benefits of a smaller incision, a shorter operation duration, a shorter length of hospital stay, and fewer complications; it is also more cost-effective than the standard four-gland exploration [40,43,47]. A small incision is usually made ipsilateral to the preoperative localized adenoma. MIP surgery can be performed through central or lateral neck incisions and has a 97% success rate with minimal morbidity and no procedure-specific complications. Preoperative localization is critical in this situation, because most of the neck is not explored, given the focused nature of the procedure [40,43,64-66].

In radioguided parathyroidectomy, ^{99m}Tc sestamibi is used as a radiotracer and the parathyroid adenoma is localized based on detection of the radiotracer. For intraoperative gamma detection, patients are injected intravenously with a low dose of 10 mCi ^{99m}Tc sestamibi approximately 1-2 h before the operation. For patients who receive a 20 mCi dose of ^{99m}Tc sestamibi for preoperative localization, surgery should be postponed for at least 3 days. Intraoperatively, the gamma probe can be inserted through the incision to perform radionuclide and in vivo counts based on the background count. An in vivo-to-background percentage of >150% strongly suggests a parathyroid adenoma. After excision of the identified parathyroid gland, the gland counts are measured by the top of the gamma probe while directed away from the patient to determine ex vivo counts; a count of >20% of the background suggests a parathyroid adenoma, based on the "20% rule" [66-69].

Video-guided (endoscopic) parathyroidectomy is comparable to MIP in operative success, incision length, postoperative pain, cosmetic

results, and complication rates. This approach facilitates recognition of recurrent laryngeal nerve and blood vessels surrounding the parathyroid glands, but it is slower. It is contraindicated in patients with previous neck surgery, negative preoperative localization, or a large goiter, or in patients who need local anesthesia [65,69]. Video-guided parathyroidectomy can be performed by using several techniques. The anterior approach permits bilateral exploration and does not need gas insufflation [70,71]. Camera and endoscopic instruments can be used through a 10-15-mm incision just above the sternal notch [40,60,70]. The lateral approach uses camera and endoscopic instruments through one 5-mm and two 2-mm incisions near the sternocleidomastoid muscle, allowing the surgeon to visualize the glands located posteriorly in the tracheoesophageal groove. The lateral approach requires low pressures of gas insufflation of the neck to avoid significant subcutaneous emphysema [40,71]. Though technically challenging, the best approach for patients who want to avoid having neck scars is the transaxillary approach [72].

Postparathyroidectomy management

It is vital to ensure that there is no expanding hematoma in the surgical wound. Antiemetics should be used to limit nausea and vomiting, which can lead to suture dislodgement. The majority of endocrine surgeons prescribe oral calcium supplements for a few weeks or vitamin D supplements in patients with very low postoperative PTH or a high risk of postoperative hungry bone syndrome. Patients should be re-evaluated 1-2 weeks after discharge to check the surgical site and serum calcium and PTH levels. Serum calcium and PTH levels should be reassessed after 6 months to confirm cure, and then annually to ensure that they remain normal and that abnormal tissue has not regrown. A follow-up bone density test is suggested at 1 year after surgery to guide the treatment of bone loss [2,13,15,33,34,40,60].

Complications

Despite a low incidence rate of 1%, bleeding and hematoma formation are fatal complications of neck surgery, as a rapidly expanding hematoma can lead to venous congestion and airway compromise. Careful intraoperative hemostasis is vital, as well as immediate bedside evacuation with subsequent exploration and closure [73]. Temporary or permanent recurrent laryngeal nerve injury and hoarseness are caused mainly by errors surrounding the varied anatomy of the recurrent laryngeal nerve and its relationship to the thyroid gland. Although intraoperative recurrent laryngeal nerve monitoring devices may help the surgeon to identify the nerve, there are no clear data to support that the use of such devices reduces the rate of nerve injury during parathyroid surgery [74].

Transient or permanent hypoparathyroidism and hypocalcemia occur frequently after subtotal or total parathyroidectomy because of ischemic injury to healthy parathyroid gland(s). Preservation of one gland is sufficient to maintain normocalcemia. The immediate primary treatment of postoperative biochemical hypocalcemia is calcium and/or vitamin D supplementation. Appropriate patient education on the symptoms of hypocalcemia and the liberal use of calcium replacement therapy is necessary prior to discharge [75]. Parathyroid cryopreservation can be used in patients who have a high risk of severe postoperative hypocalcemia [76].

Persistent or recurrent disease has an incidence ranging from 1% to 10% [77]. Following parathyroidectomy, hypercalcemia within 6 months is defined as persistent disease and hypercalcemia after 6 months is defined as recurrent disease. Persistent or recurrent disease may be caused by surgeon inexperience, incomplete exploration, or supernumerary glands. Preoperative parathyroid surgery in these cases presents a challenge, as dense scar tissue and distorted tissue planes obscure intraoperative localization [78-80].

Special conditions in parathyroid surgery

In persistent or recurrent cases, cure rates decrease as the number of previous neck operations increases [78-80]. Thus, numerous protocols have been suggested to improve surgical outcomes in patients who require reoperation. While one proposal includes mandatory ^{99m}Tc sestamibi scanning and cervical ultrasound before the operation [78], other protocols recommend a series of CTs, MRIs, and selective venous sampling until localization is achieved [79]. Many groups have reported appropriate, safe, and effective outcomes if both accurate preoperative imaging and IoPTH are used [78]. Medial cervical incision is the standard approach, as it allows bilateral cervical exploration, although some surgeons prefer to use the lateral approach to avoid scar tissues and achieve better posterior access to the thyroid bed [78,79]. In addition, several surgeons recommend radioguided parathyroidectomy in the reoperative setting [67-69]. A video-assisted thoracic approach, median sternotomy, or partial sternal split may be needed in some cases [70,81].

In parathyroid carcinoma, the most common surgical approach is aggressive en bloc tumor resection, which includes an ipsilateral thyroid lobectomy and resection of adjacent soft tissues, perhaps including the recurrent laryngeal nerve, esophageal wall, or strap muscles if the tumor is adherent [17]. In pediatric patients, the standard of care is bilateral neck exploration; however, because data were primarily obtained from patients with PHPT resulting from single adenomas, focused parathyroidectomy is ideal to minimize scarring and postoperative complications [82,83]. In the elderly, surgery has a high cure rate, low morbidity, no mortality, and a short length of hospital stay. Surgery was found to be optimal relative to medical management when life expectancy reached 5 years for outpatients and 6.5 years for inpatients [84,85]. Finally, in pregnant women, a cervical ultrasound can be used for preoperative localization, and surgery is the treatment of choice during the second trimester [30].

Medical therapy options

In patients who are not candidates for surgery or those unwilling to undergo parathyroidectomy, treatment recommendations include annual serum calcium and creatinine testing and BMD measurement every 1–2 years. Patients should be encouraged to maintain a normal intake of calcium. Medical management includes: 1) bisphosphonates and hormone replacement therapy to decrease bone turnover and improve BMD, although they do not decrease serum calcium or PTH levels; 2) cinacalcet to reduce serum calcium and PTH levels and raises serum phosphorus levels, although it does not reduce bone turnover or improve BMD [79]. Cinacalcet reduces PTH secretion by binding the calcium-sensing receptor (CaR) of parathyroid cells [86]. In a multicenter, randomized, double-blind study evaluated the effect of cinacalcet on PHPT patients found that there were no significant changes in BMD. However, after 52 weeks of treatment normal serum calcium levels were achieved in 73% of patients, and serum PTH decreased by only 7.6% [87]. 3) Vitamin D should be measured and replaced if the pre-parathyroidectomy vitamin D level is <20 ng/mL or <50 nmol/L [88].

Ultrasound-Guided Ethanol Ablation

Ultrasound-guided ethanol ablation is an alternative therapy for PHPT in patients with MEN type 1, recurrent disease, or extreme morbidity who cannot receive surgical or medical treatment. The parathyroid tumor is localized by ultrasound and the tumor is percutaneously injected with ethanol; however, this method has a very low cure rate, requiring close follow-up of serum calcium and possibly repeat treatments [89]. Moreover, Harman et al. and Karstrup et al. reported recurrent laryngeal nerve injury in 5.6–7.1% of patients with PHPT who underwent percutaneous alcohol ablation [89,90].

Conclusion

PHPT is the most common cause of outpatient hypercalcemia. Currently, PHPT is being identified during the asymptomatic stages, due to the widespread use of screening tests; however, it is associated with high mortality due to its systemic complications. Hypercalcemia should be evaluated carefully to confirm the diagnosis, identify the cause, and rule out hereditary disorders. Many advances have been made in the diagnosis and management of this condition, but PHPT in all of its variants remains a surgically managed disease. Recurrent and persistent diseases are uncommon, but present numerous challenges. Future research is needed to identify the best treatment, minimize complications, and improve quality of life.

Acknowledgement

Financial Support: Ministry of higher education of Saudi Arabia, and King Faisal Hospital & Research Center (KFSH&RC), Riyadh, Saudi Arabia scholarship.

References

1. Fisher S, Wishart G (2007) Hyperparathyroidism and hypocalcemia. *Surgery* 25: 487-491.
2. Fraser WD (2009) Hyperparathyroidism. *Lancet* 374: 145-158.
3. Wermers RA, Khosla S, Atkinson EJ, Achenbach SJ, Oberg AL, et al. (2006) Incidence of primary hyperparathyroidism in Rochester, Minnesota, 1993-2001: an update on the changing epidemiology of the disease. *J Bone Miner Res* 21: 171-177.
4. Yu N, Donnan PT, Leese GP (2011) A record linkage study of outcomes in patients with mild primary hyperparathyroidism: The Parathyroid Epidemiology and Audit Research Study (PEARS). *Clin Endocrinol (Oxf)* 75: 169-176.
5. MANDL F (1947) Hyperparathyroidism; a review of historical developments and the present state of knowledge on the subject. *Surgery* 21: 394-440.
6. Gomes EM, Nunes RC, Lacativa PG, Almeida MH, Franco FM, et al. (2007) Ectopic and extranumerary parathyroid glands location in patients with hyperparathyroidism secondary to end stage renal disease. *Acta Cir Bras* 22: 105-109.
7. Akerström G, Malmaeus J, Bergström R (1984) Surgical anatomy of human parathyroid glands. *Surgery* 95: 14-21.
8. Heffess CS (2008) Embryology, anatomy, and histology In: Wenig B, ed. *Atlas of Head and Neck Pathology*. (2nd edn), Saunders Elsevier, China.
9. Kronenberg H, Williams RH (2008) *Williams Textbook of Endocrinology*. (11th edn), Saunders/Elsevier, Philadelphia.
10. Kumar R, Thompson JR (2011) The regulation of parathyroid hormone secretion and synthesis. *J Am Soc Nephrol* 22: 216-224.
11. Seethala RR, Virji MA, Ogilvie JB (2009) Pathology of the parathyroid glands. In: Barnes L, ed. *Surgical Pathology of the Head and Neck*. (3rd edn), Informa Health Care, New York.
12. Silverberg SJ, Lewiecki EM, Mosekilde L, Peacock M, Rubin MR (2009) Presentation of asymptomatic primary hyperparathyroidism: Proceedings of the third international workshop. *J Clin Endocrinol Metab* 94: 351-365.
13. Ruda JM, Hollenbeak CS, Stack BC Jr (2005) A systematic review of the diagnosis and treatment of primary hyperparathyroidism from 1995 to 2003. *Otolaryngol Head Neck Surg* 132: 359-372.
14. Pepe J, Cipriani C, Pilotto R, De Lucia F, Castro C, et al. (2011) Sporadic and hereditary primary hyperparathyroidism. *J Endocrinol Invest* 34: 40-44.
15. Clark MJ, Pellitteri PK (2009) Assessing the impact of low baseline parathyroid hormone levels on surgical treatment of primary hyperparathyroidism. *Laryngoscope* 119: 1100-1105.
16. Repplinger D, Schaefer S, Chen H, Sippel RS (2009) Neurocognitive dysfunction: a predictor of parathyroid hyperplasia. *Surgery* 146: 1138-1143.
17. Shane E (2001) Clinical review 122: Parathyroid carcinoma. *J Clin Endocrinol Metab* 86: 485-493.
18. Beard CM, Heath H 3rd, O'Fallon WM, Anderson JA, Earle JD, et al. (1989) Therapeutic radiation and hyperparathyroidism. A case-control study in Rochester, Minn. *Arch Intern Med* 149: 1887-1890.
19. Jacobs TP, Bilezikian JP (2005) Clinical review: Rare causes of hypercalcemia. *J Clin Endocrinol Metab* 90: 6316-6322.

20. Cetani F, Pardi E, Borsari S, Marcocci C (2011) Molecular pathogenesis of primary hyperparathyroidism. *J Endocrinol Invest* 34: 35-39.
21. Mundy GR, Cove DH, Fiskens R (1980) Primary hyperparathyroidism: changes in the pattern of clinical presentation. *Lancet* 1: 1317-1320.
22. Mollerup CL, Vestergaard P, Frokjaer VG, Mosekilde L, Christiansen P, et al. (2002) Risk of renal stone events in primary hyperparathyroidism before and after parathyroid surgery: Controlled retrospective follow up study. *BMJ* 325: 807.
23. Rejnmark L, Vestergaard P, Mosekilde L (2011) Nephrolithiasis and renal calcifications in primary hyperparathyroidism. *J Clin Endocrinol Metab* 96: 2377-2385.
24. Silverberg SJ, Shane E, de la Cruz L, Dempster DW, Feldman F, et al. (1989) Skeletal disease in primary hyperparathyroidism. *J Bone Miner Res* 4: 283-291.
25. VanderWalde LH, Liu IL, Haigh PI (2009) Effect of bone mineral density and parathyroidectomy on fracture risk in primary hyperparathyroidism. *World J Surg* 33: 406-411.
26. Ebert EC (2010) The parathyroids and the gut. *J Clin Gastroenterol* 44: 479-482.
27. Roman SA, Sosa JA, Mayes L, Desmond E, Boudourakis L, et al. (2005) Parathyroidectomy improves neurocognitive deficits in patients with primary hyperparathyroidism. *Surgery* 138: 1121-1129.
28. Walker MD, Silverberg SJ (2008) Cardiovascular aspects of primary hyperparathyroidism. *J Endocrinol Invest* 31: 925-931.
29. Ekmekci A, Abaci N, Colak Ozbey N, Agayev A, Aksakal N, et al. (2009) Endothelial function and endothelial nitric oxide synthase intron 4a/b polymorphism in primary hyperparathyroidism. *J Endocrinol Invest* 32: 611-616.
30. Pothiwala P, Levine SN (2009) Parathyroid surgery in pregnancy: review of the literature and localization by aspiration for parathyroid hormone levels. *J Perinatol* 29: 779-784.
31. Carneiro-Pla D, Solorzano C (2012) A summary of the new phenomenon of normocalcemic hyperparathyroidism and appropriate management. *Curr Opin Oncol* 24: 42-45.
32. Cusano NE, Silverberg SJ, Bilezikian JP (2013) Normocalcemic primary hyperparathyroidism. *J Clin Densitom* 16: 33-39.
33. Bilezikian JP, Khan AA, Potts JT Jr, Third International Workshop on the Management of Asymptomatic Primary Hyperthyroidism (2009) Guidelines for the management of asymptomatic primary hyperparathyroidism: summary statement from the third international workshop. *J Clin Endocrinol Metab* 94: 335-339.
34. AACE/AAES Task Force on Primary Hyperparathyroidism (2005) The American Association of Clinical Endocrinologists and the American Association of Endocrine Surgeons position statement on the diagnosis and management of primary hyperparathyroidism. *Endocr Pract* 11: 49-54.
35. Eastell R, Arnold A, Brandi ML, Brown EM, D'Amour P, et al. (2009) Diagnosis of asymptomatic primary hyperparathyroidism: proceedings of the third international workshop. *J Clin Endocrinol Metab* 94: 340-350.
36. Norman J, Goodman A, Politz D (2011) Calcium, parathyroid hormone, and vitamin D in patients with primary hyperparathyroidism: normograms developed from 10,000 cases. *Endocr Pract* 17: 384-394.
37. Mshelia DS, Hatutale AN, Mokgoro NP, Nchabaleng ME, Buscombe JR, et al. (2012) Correlation between serum calcium levels and dual-phase (99m)Tc-sestamibi parathyroid scintigraphy in primary hyperparathyroidism. *Clin Physiol Funct Imaging* 32: 19-24.
38. Shinall MC Jr, Dahir KM, Broome JT (2013) Differentiating familial hypocalciuric hypercalcemia from primary hyperparathyroidism. *Endocr Pract* 19: 697-702.
39. Kent GN, Bhagat CI, Garcia-Webb P, Gutteridge DH (1987) Tubular maximum for calcium reabsorption: lack of diagnostic usefulness in primary hyperparathyroidism and familial hypocalciuric hypercalcaemia. *Clin Chim Acta* 166: 155-161.
40. Suliburk JW, Perrier ND (2007) Primary hyperparathyroidism. *Oncologist* 12: 644-653.
41. Chen H, Mack E, Starling JR (2005) A comprehensive evaluation of perioperative adjuncts during minimally invasive parathyroidectomy: Which is most reliable? *Ann Surg* 242: 375-380.
42. Ishibashi M, Nishida H, Hiromatsu Y, Kojima K, Tabuchi E, et al. (1998) Comparison of technetium-99m-MIBI, technetium-99m-tetrofosmin, ultrasound and MRI for localization of abnormal parathyroid glands. *J Nucl Med* 39: 320-324.
43. Chen H, Sokoll LJ, Udelsman R (1999) Outpatient minimally invasive parathyroidectomy: A combination of sestamibi-SPECT localization, cervical block anesthesia, and intraoperative parathyroid hormone assay. *Surgery* 126:1016-1022.
44. Khalid AN, Hollenbeck CS, Higginbotham BW, Stack BC Jr (2009) Accuracy and definitive interpretation of preoperative technetium 99m sestamibi imaging based on the discipline of the reader. *Head Neck* 31: 576-582.
45. Anderson SR, Vaughn A, Karakla D, Wadsworth JT (2008) Effectiveness of surgeon interpretation of technetium tc 99m sestamibi scans in localizing parathyroid adenomas. *Arch Otolaryngol Head Neck Surg* 134: 953-957.
46. Zia S, Sippel RS, Chen H (2012) Sestamibi imaging for primary hyperparathyroidism: the impact of surgeon interpretation and radiologist volume. *Ann Surg Oncol* 19: 3827-3831.
47. Neychev VK, Kouniavsky G, Shiue Z, Udall DN, Somervell H, et al. (2011) Chasing "shadows": discovering the subtleties of sestamibi scans to facilitate minimally invasive parathyroidectomy. *World J Surg* 35: 140-146.
48. Gilat H, Cohen M, Feinmesser R, Benzion J, Shvero J, et al. (2005) Minimally invasive procedure for resection of a parathyroid adenoma: the role of preoperative high-resolution ultrasonography. *J Clin Ultrasound* 33: 283-287.
49. Bentrem DJ, Angelos P, Talamonti MS, Nayar R (2002) Is preoperative investigation of the thyroid justified in patients undergoing parathyroidectomy for hyperparathyroidism? *Thyroid* 12: 1109-1112.
50. Vitetta GM, Neri P, Chiecchio A, Carriero A, Cirillo S, et al. (2014) Role of ultrasonography in the management of patients with primary hyperparathyroidism: Retrospective comparison with technetium-99m sestamibi scintigraphy. *J Ultrasound* 17: 1-12.
51. Rodgers SE, Hunter GJ, Hamberg LM, Schellingerhout D, Doherty DB, et al. (2006) Improved preoperative planning for directed parathyroidectomy with 4-dimensional computed tomography. *Surgery* 140: 932-940.
52. Mahajan A, Starker LF, Ghita M, Udelsman R, Brink JA, et al. (2012) Parathyroid four-dimensional computed tomography: Evaluation of radiation dose exposure during preoperative localization of parathyroid tumors in primary hyperparathyroidism. *World J Surg* 36: 1335-1339.
53. Reidel MA, Schilling T, Graf S, Hinz U, Nawroth P, et al. (2006) Localization of hyperfunctioning parathyroid glands by selective venous sampling in reoperation for primary or secondary hyperparathyroidism. *Surgery* 140: 907-913.
54. Ogilvie CM, Brown PL, Matson M, Dacie J, Reznick RH, et al. (2006) Selective parathyroid venous sampling in patients with complicated hyperparathyroidism. *Eur J Endocrinol* 155: 813-821.
55. Ito F, Sippel R, Lederman J, Chen H (2007) The utility of intraoperative bilateral internal jugular venous sampling with rapid parathyroid hormone testing. *Ann Surg* 245: 959-963.
56. Irvin GL III, Solorzano CC, Carneiro DM (2004) Quick intraoperative parathyroid hormone assay: Surgical adjunct to allow limited parathyroidectomy, improve success rate, and predict outcome. *World J Surg* 28: 1287-1292.
57. Carneiro DM, Solorzano CC, Nader MC, Ramirez M, Irvin GL 3rd (2003) Comparison of intraoperative iPTH assay (QPTH) criteria in guiding parathyroidectomy: which criterion is the most accurate? *Surgery* 134: 973-979.
58. Barczynski M, Konturek A, Hubalewska-Dydejczyk A, Cichon S, Nowak W (2009) Evaluation of Halle, Miami, Rome, and Vienna intraoperative iPTH assay criteria in guiding minimally invasive parathyroidectomy. *Langenbecks Arch Surg* 394: 843-849.
59. Alhfeldi A, Pinchot SN, Davis R, Sippel RS, Chen H (2011) The necessity and reliability of intraoperative parathyroid hormone (PTH) testing in patients with mild hyperparathyroidism and PTH levels in the normal range. *World J Surg* 35: 2006-2009.
60. Eigelberger MS, Clark OH (2000) Surgical approaches to primary hyperparathyroidism. *Endocrinol Metab Clin North Am* 29:479-502.
61. Hosking DJ, Cowley A, Bucknall CA (1981) Rehydration in the treatment of severe hypercalcaemia. *Q J Med* 50: 473-481.
62. Macfarlane DP, Yu N, Leese GP (2013) Subclinical and asymptomatic parathyroid disease: implications of emerging data. *Lancet Diabetes Endocrinol* 1: 329-340.
63. Padmanabhan H (2011) Outpatient management of primary hyperparathyroidism. *Am J Med* 124: 911-914.
64. Lorenz K, Nguyen-Thanh P, Dralle H (2000) Unilateral open and minimally invasive procedures for primary hyperparathyroidism: a review of selective approaches. *Langenbecks Arch Surg* 385: 106-117.
65. Palazzo FF, Delbridge LW (2004) Minimal-access/minimally invasive parathyroidectomy for primary hyperparathyroidism. *Surg Clin North Am* 84: 717-734.

66. Terris DJ, Stack BC Jr, Gourin CG (2007) Contemporary parathyroidectomy: exploiting technology. *Am J Otolaryngol* 28: 408-414.
67. Placzkowski K, Christian R, Chen H (2007) Radioguided parathyroidectomy for recurrent parathyroid cancer. *Clin Nucl Med* 32: 358-360.
68. Ardito G, Revelli L, Giustozzi E, Giordano A (2012) Radioguided parathyroidectomy in forearm graft for recurrent hyperparathyroidism. *Br J Radiol* 85: e1-e3.
69. Wineland A, Siegel E, Stack BC Jr (2008) Reexamining normative radiation data for radioguided parathyroid surgery. *Arch Otolaryngol Head Neck Surg* 134: 1209-1213.
70. Henry JF, Iacobone M, Mirallie E, Deveze A, Pili S (2001) Indications and results of video-assisted parathyroidectomy by a lateral approach in patients with primary hyperparathyroidism. *Surgery* 130: 999-1004.
71. Miccoli P, Bendinelli C, Conte M, Pinchera A, Marcocci C (1998) Endoscopic parathyroidectomy by a gasless approach. *J Laparoendosc Adv Surg Tech A* 8: 189-194.
72. Ikeda Y, Takami H, Sasaki Y, Kan S, Niimi M (2000) Endoscopic neck surgery by the axillary approach. *J Am Coll Surg* 191: 336-340.
73. Abbas G, Dubner S, Heller KS (2001) Re-operation for bleeding after thyroidectomy and parathyroidectomy. *Head Neck* 23: 544-546.
74. Moley JF, Lairmore TC, Doherty GM, Brunt LM, DeBenedetti MK (1999) Preservation of the recurrent laryngeal nerves in thyroid and parathyroid reoperations. *Surgery* 126: 673-677.
75. Westerdahl J, Lindblom P, Valdemarsson S, Tibblin S, Bergenfelz A (2000) Risk factors for postoperative hypocalcemia after surgery for primary hyperparathyroidism. *Arch Surg* 135: 142-147.
76. Shepet K, Alhefthi A, Usedom R, Sippel R, Chen H (2013) Parathyroid cryopreservation after parathyroidectomy: a worthwhile practice? *Ann Surg Oncol* 20: 2256-2260.
77. Alhefthi A, Schneider DF, Sippel R, Chen H (2014) Recurrent and persistence primary hyperparathyroidism occurs more frequently in patients with double adenomas. *J Surg Res* 190: 198-202.
78. Richards ML, Thompson GB, Farley DR, Grant CS (2008) Reoperative parathyroidectomy in 228 patients during the era of minimal-access surgery and intraoperative parathyroid hormone monitoring. *Am J Surg* 196: 937-942.
79. Caron NR, Sturgeon C, Clark OH (2004) Persistent and recurrent hyperparathyroidism. *Curr Treat Options Oncol* 5: 335-345.
80. Yen TW, Wang TS, Doffek KM, Krzywdka EA, Wilson SD (2008) Reoperative parathyroidectomy: An algorithm for imaging and monitoring of intraoperative parathyroid hormone levels that results in a successful focused approach. *Surgery* 144: 611-621.
81. Chae AW, Perricone A, Brumund KT, Bouvet M (2008) Outpatient video-assisted thoracoscopic surgery (VATS) for ectopic mediastinal parathyroid adenoma: a case report and review of the literature. *J Laparoendosc Adv Surg Tech A* 18: 383-390.
82. Kollars J, Zarroug AE, van Heerden J, Lteif A, Stavlo P, et al. (2005) Primary hyperparathyroidism in pediatric patients. *Pediatrics* 115: 974-980.
83. Adam LA, Smith BJ, Calva-Cerqueira D, Howe JR, Lal G (2008) Role for limited neck exploration in young adults with apparently sporadic primary hyperparathyroidism. *World J Surg* 32: 1518-1524.
84. Egan KR, Adler JT, Olson JE, Chen H (2007) Parathyroidectomy for primary hyperparathyroidism in octogenarians and nonagenarians: a risk-benefit analysis. *J Surg Res* 140: 194-198.
85. Morris GS, Grubbs EG, Hearon CM, Gantela S, Lee JE (2010) Parathyroidectomy improves functional capacity in "asymptomatic" older patients with primary hyperparathyroidism: A randomized control trial. *Ann Surg* 251: 832-837.
86. Bollerslev J, Marcocci C, Sosa M, Nordenström J, Bouillon R, et al. (2011) Current evidence for recommendation of surgery, medical treatment and vitamin D repletion in mild primary hyperparathyroidism. *Eur J Endocrinol* 165: 851-864.
87. Peacock M, Bilezikian JP, Klassen PS, Guo MD, Turner SA, et al. (2005) Cinacalcet hydrochloride maintains long-term normocalcemia in patients with primary hyperparathyroidism. *J Clin Endocrinol Metab* 90: 135-141.
88. Khan A, Grey A, Shoback D (2009) Medical management of asymptomatic primary hyperparathyroidism: proceedings of the third international workshop. *J Clin Endocrinol Metab* 94: 373-381.
89. Harman C, Grant C, Hay I, Hurley DL, van Heerden JA, et al. (1998) Indications, technique, and efficacy of alcohol injection of enlarged parathyroid glands in patients with primary hyperparathyroidism. *Surgery* 124: 1011-1020.
90. Karstrup S, Hegedüs L, Holm HH (1993) Ultrasonically guided chemical parathyroidectomy in patients with primary hyperparathyroidism: a follow-up study. *Clin Endocrinol (Oxf)* 38: 523-530.