

Craniosynostosis: Surgical Treatment and Safety 16 years Experience

Franco Agustin Rinaudo Marini¹, Daniel Gustavo Velazquez Quintar, Campana Javier Dario, Federico Ignacio Garavaglia and Enrique Jose Herrera

Department of Neurosurgery Service, Sanatorio Allende, Cordoba, Argentina

Abstract

Introduction: Craniosynostosis is defined as the early and pathological closure of one or several skull sutures which limits brain growth and development. It has an incidence of 1 over 2000-2500 live births. Main concerns about its surgical management refers to the preoperative study, surgical timing and technique.

Methods: For this study we retrospectively review medical records of patients surgically treated in our institution between January 2006 and December 2021. We studied variety, sex and age distribution, surgical technic and complications.

Results: During the period of study 84 children were surgically treated, 69% were males (58 patients) with a mean age of 6 months, the follow-up period was between 1-180 months. The variety distribution of non syndromic craniosynostosis was scaphocephaly (51;61%) trigonocephaly (14;16.5%) anterior plagiocephaly (8;9.5%), brachycephaly (3;3.5%) posterior plagiocephaly (2;2.5%) and one case of oxycephaly (1%), we described 5 syndromic cases (6%). There were 4 complications and no mortality in our series.

Discussion: In our series of 84 patients we had a sex and variety distribution similar to other reports. Our incidence and type of complications was also similar to those described by other authors.

Conclusion: Craniosynostosis is a rare entity in the general population but usual in pediatric neurosurgery, it's early recognition and adequate referral to a specialized unit gives the better chances of good esthetic and functional results for the patient.

Keywords: Craniosynostosis • Scaphocephaly • Trigonocephaly • Brachycephaly • Plagiocephaly • Craniofacial Syndromes

Introduction

Craniosynostosis is defined as the pathological fusion of one or several skull sutures, this condition limits brain growth and development. It's incidence is 1 in 2000-2500 live births [1-12].

Historically craniosynostosis has been classified as syndromic or not syndromic. 17,20 Most of the non syndromic cases than compromise one suture can be easily diagnosed by simple inspection and palpation, using plain radiographs for confirmation [13-18].

There's still controversy regarding the utility of computed tomography exams (CT) during the study of non syndromic patients. One prospective multicenter study demonstrates that a single suture craniosynostosis could be diagnosed by clinical examination with the same efficacy as CT imagenes.

Nevertheless advanced image methods could be useful in cases where the diagnosis is in doubt or for surgical planning. Some authors have reported the use of invasive intracranial pressure monitoring, fundoscopic examination or electroencephalography during the preoperative study [19-24].

Address for Correspondence: Franco Agustin Rinaudo Marini, Department of Neurosurgery Service, Sanatorio Allende, Cordoba, Argentina, Email: rinaudomarini@gmail.com

Copyright: © 2022 Rinaudo Marini FA et al. This is an open-access article distributed under the terms of the creative commons attribution license which permits unrestricted use, distribution and reproduction in any medium, provided the original author and source are credited.

Received: 04-April-2022, Manuscript No. jnd-22-61949; **Editor assigned:** 06-April-2022, PreQC No. P-61949 (PQ); **Reviewed:** 20-April-2022; QC No. Q-61949; **Revised:** 25-April-2022, Manuscript No. R-61949; **Published:** 02-May-2022, DOI: 10.4172/2329-6895.10.4.488

There is no unified theory to explain how craniosynostosis affects brain development. It has been associated with raised intracranial pressure, focal brain hypoperfusion and deformation of neuroanatomical structures [25-28].

Raised intracranial pressure has been recorded in all ways of craniosynostosis and is greater in syndromic cases or patients with multiple suture involvement, it is also higher in patients older than 1 year. There is an inverse correlation between raised intracranial pressure and intellectual coefficient.

Main doubts about surgical management refer to the surgical technique and timing. Although comprehensive vault reconstruction techniques immediately restore cranial morphology they are associated with greater hospital stay and blood loss. However several studies have demonstrated better results in open surgery than endoscopic approaches. Also, patients operated before age of 6 months had better neurocognitive results than those older than that age.

The most feared complications in craniosynostosis surgery are those associated with blood loss, air embolism and infection. Skin infiltration and prophylactic tranexamic acid administration are recommended in association with intensive hemodynamic and hematologic monitoring. Intraoperative hemostasis and postoperative monitoring are recommended to prevent hemorrhagic complications. Hydrocephalus, more common in syndromic cases, is a frequent concern.

Methods

For this study we review retrospectively clinical records of all patients treated for craniosynostosis in our institution between January 2006 and December 2022. The protocol was approved by the ethics committee of our institution and parental consent was obtained.

We included all patients diagnosed and treated in our institution regardless of the variety. We also include imaging studies (plain radiographs, computed tomography, magnetic resonance images) used in the preoperative

period and follow up. All patients received during the preoperative period a cardiovascular check-up and basic hemostasis parameters analysis (Prothrombin time, Platelets, Partial Thromboplastin Time), in cases of abnormalities we proceed with a specialized analysis. Electroencephalogram and fundoscopic examination is not routinely indicated by our team.

All patients were operated in our institution and the surgical technique varied depending on the type of craniosynostosis, transfusions were indicated during the operative or postoperative time, also hemostasis and hemodynamic monitoring. Postoperative follow up was in the pediatric intensive care unit.

We reviewed complications and interventions during the postoperative period, follow up was done at the institution or by phone according to the case.

Perioperative management

Independently of the variety of craniosynostosis all patients received general anesthesia with orotracheal intubation, several high caliber venous lines and invasive arterial pressure monitoring were used for infusion of drugs and blood derivatives. Urinary catheter and skin infiltration with anesthetics and vasoconstrictors is used routinely. In general practice in our institution the use of tranexamic acid during induction and maintenance during surgery. We do not start surgery without blood derivatives in the operative room.

During the postoperative period the patient stays at the pediatric intensive care unit for hemodynamic, neurological and hemostasis monitoring. Hospital discharge usually occurs between 4-5 postoperative days once we achieve hemostasis and hemodynamic stability, pain management and oral tolerance.

Results

Between January 2006 and December 2021 84 patients were surgically treated for craniosynostosis, 69% were males (58 patients). The mean age at surgery was 6 months (4-60 months). We present 6 patients operated over the age of 1, all males of which 4 were escaphocephaly (16,16,24,60 months), 1 trigonocephaly (20 months) and 1 brachycephaly (25 months).

We report 5 syndromic patients (6%) of which 4 were Crouzon's Syndrome (2 males and 2 females) and one Apert Syndrome (1 female).

The distribution of non syndromic craniosynostosis was scaphocephaly (51;61%) trigonocephaly (14;16.5%), anterior plagiocephaly (8;9.5%), brachycephaly (3;3.5%) posterior plagiocephaly (2;2.5%) and one case of oxicefalia (1%). Distribution by variety and sex is presented in **Table 1**.

Table 1. Distribution by sex and variety.

Variety	N°Patients	Male/Female
Escafocheplay	51 (61%)	40/11 (78%M)
Trigonocephaly	14 (15%)	13/1(92%M)
Anterior Plagiocephaly	8 (9.5%)	2/6 (25%M)
Brachycephaly	3 (3.5%)	1/2 (33%M)
Posterior Plagiocephaly	2 (2%)	0/2 (0%M)
Oxycephaly	1 (1%)	0/1 (0%M)
Syndromic	5 (6%)	2/3 (40%M)

The most common consult was skull shape deformation which was present in all patients, only one was referred to us for seizures and intracranial hypertension in a case of scafocefalia of a 5 year old male.

All patients were studied with plain radiographs where there was evidence of premature closure of at least one skull suture, in 39 cases (45%) study

was completed with CT and in 2 with MRI (2%) (**Figure 1**).

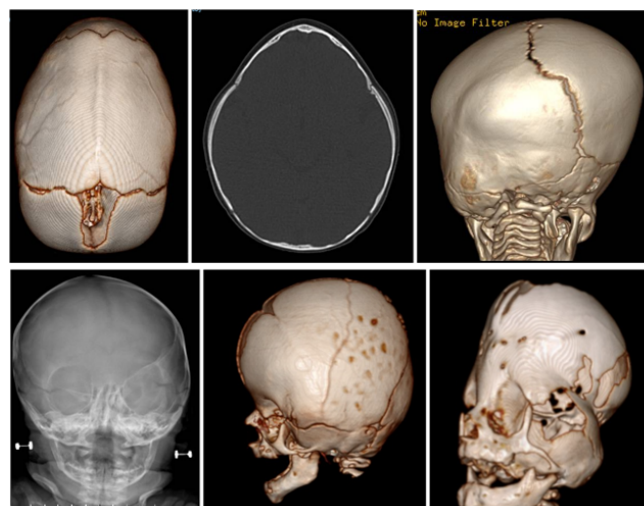


Figure 1. From left to right. CT showing absence of sagittal suture and dolichocephalic skull configuration. Axial CT of patients with trigonocephaly. Posterior CT view with evidence of premature closure of left parieto-occipital suture. Plain radiograph of anterior plagiocephaly. Brachycephaly in patients with Crouzon's Syndrome. CT of patients with oxycephaly and multiple closed sutures.

Surgical technique varied according to the type of craniosynostosis, for scaphocephaly we use 3 techniques, vertex craniectomy for 27 patients, vertex craniectomy with sagittal cranioplasty in 20 patients and multiple cranial fragmentation in patients older than 1 year. For the cases of trigonocephaly, anterior plagiocephaly and brachycephaly different types of orbito-frontal advanced techniques with resorbable fixation devices. In patients with posterior plagiocephaly occipital reconstruction with absorbable fixation devices was performed and in the case of oxocelhaia comprehensive cranial vault reconstruction was performed.

The follow-up time ranged between 1-180 months (mean 50 months), during this period we presented 1 case of re-intervention (1.1%) in a patients with Crouzon's Syndrome and closure of multiple sutures, he was intervened 19 months later of the first operation for presenting signs of turriccephaly (**Figure 2**).

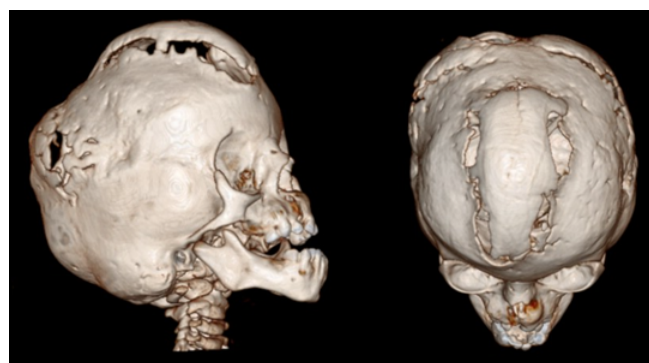


Figure 2. Patients con Crouzon's Syndrome who required re-intervention 19 months later to firs surgery for presenting signs of turriccephaly.

There were a total of 4 complications (4.7%), 2 were hemorrhagic complications secondary to hematological disorders unknown prior to surgery associated with massive bleeding during skin incision, both cases could be compensated with blood derivatives, 1 patient presented with acute hydrocephalus which required emergency EVD placement and evolved with chronic hydrocephalus and 1 case of leptomenigeal cyst secondary to dural tear during craniotomy (**Figure 3**). Of the 84 patients 2 evolved with

chronic hydrocephalus and need for shunt placement (2%). There were no cases of mortality in our series.

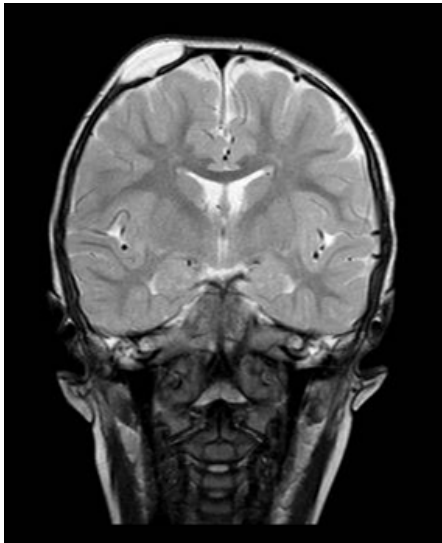


Figure 3. Parietal leptomeningeal cyst secondary to dural tear during craniotomy in a 5 months female with scaphocephaly.

Discussion

Our objective was to study evolution and characterized patients surgically treated for craniosynostosis with open surgery. In our 84 patients sex and variety distribution was similar to those reported in other series. Syndromic forms also had a similar distribution of other reports.

The preoperative study with plain radiograph is widely accepted, the use of advanced imaging methods like CT or MRI is still matter of discussion, in our experience the use of CT favors a correct diagnosis, facilitates surgical planning and helps in detecting skeletal malformations (Eg Ventriculomegaly or Chiari I Malformation) that could have implications in neurodevelopmental prognosis, it also helps parent comprehension about the pathology. Funduscopic examination, electroencephalography and invasive monitoring of ICO is not performed as a routine preoperative study as is described by other authors, we request them in case of epileptic seizures or clinical findings that suggest intracranial hypertension

We believe that best results are achieved planning surgical intervention around 6 months, bone flexibility allows adequate skull modeling and there is less risk associated with hemodynamic complication than in smaller patients, this is similar to other reports (Figure 4).

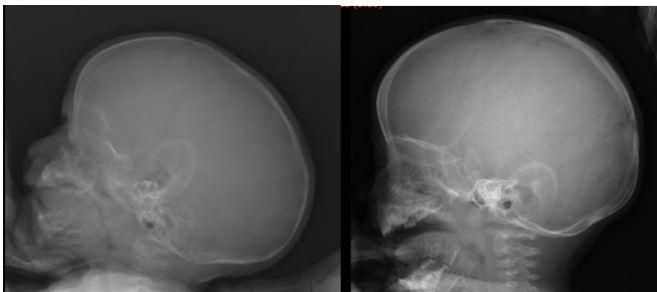

Figure 4. Preoperative and postoperative lateral view of plain radiograph of patient operated at 6 months for scaphocephaly.

During the follow period we presented 4 complications, all of them described in multiple reports as the most common. In our series we presented 2 cases of hydrocephalus (2%) and no mortality, this results are just below other publications.

Conclusion

Craniosynostosis is a rare entity in the general population but usual in pediatric neurosurgery, its early recognition and adequate referral to a specialized unit gives the better chances of good esthetic and functional results for the patient.

Owing to the complexity of its management surgical approaches to this patient should be carried on in specialized centers with human and technological resources to manage its complications. Surgical expertise, anesthesiologist used to management of pediatric patients and prepared intensive care unit pediatricians are essential. With these conditions given and adequate preoperative study surgical management of craniosynostosis can be considered a safe and efficient procedure with low complications and mortality.

Ethics Approval and Consent to Participate

Ethical approval was waived by the local Ethics Committee of Sanatorio Allende, in view of the retrospective nature of the study and all the procedures being performed were part of the routine care. The study was conducted in accordance with the declaration of Helsinki.

Consent for Publication

Parental consent for publication was obtained.

Availability of Data and Materials

Raw data were generated at Sanatorio Allende. Derived data supporting the findings of this study are available from the corresponding author (Rinaudo Marini F A) on request.

Competing Interests

No potential competing interest was reported by the authors.

Funding

The author(s) received no financial support for the research, authorship, and/or publication of this article.

Author's Contributions

Rinaudo Marini F A is the main author of the article with collaboration of FJ Pueyrredon and EJ Herrera who were part of the surgical teams involved in the management of these patients. All authors reviewed the manuscript.

Acknowledgements

Not applicable

Author's Information

Not applicable

References

1. Albright, L, Pollack I and Adelson P. "Principles and practice of pediatric neuro surgery." *Thieme New York* 19(2015):237-148.

2. Arnaud, E, Renier D and Marchac D. "Prognosis for mental function in scaphocephaly." *J Neurosurg* 83(1995):476-479.
3. Brenner, DJ and Hall EJ. "Computed tomography- an increasing source of radiation exposure." *N Engl J Med* 29(2007):2277-2284.
4. Chieffo, D, Tamburrini G, Massimi L and Di Giovanni S, et al. "Long-term neuropsychological development in single-suture craniosynostosis treated early." *J Neurosurg Pediatr* 5(2010):232-237.
5. Cinalli, G, Sainte RC, Kollar EM and Zerah M, et al. "Hydrocephalus and craniosynostosis." *J Neurosurg* 88(1998):209-214.
6. Collmann, H, Sorensen N and Krauss J. "Hydrocephalus in craniosynostosis: A review." *Childs Nerv Syst* 21(2005):902-912.
7. Delashaw, JB, Persing JA, Broaddus WC and Jane JA. "Cranial vault growth in craniosynostosis." *J Neurosurg* 70(1989):159-165.
8. Esparza, J and Hinojosa J. "Complications in the surgical treatment of craniosynostosis and craniofacial syndromes: Apropos of 306 transcranial procedures." *Childs Nerv Syst* 24(2008):1421-1430.
9. Esparza, J, Hinojosa J, Garcia RI and Romance A, et al. "Surgical treatment of isolated and syndromic craniosynostosis. Results and complications in 283 consecutive cases." *Neurocirugia Astur* 19(2008):509-529.
10. Fearon, JA, Singh DJ, Beals SP and Yu JC. "The diagnosis and treatment of single-sutural synostosis: Are computed tomographic scans necessary?" *Plast Reconstr Surg* 120(2007):1327-1331.
11. Fearon, JA, Yu J, Bartlett SP and Munro IR, et al. "Infections in craniofacial surgery: A combined report of 567 procedures from two centers." *Plast Reconstr Surg* 100(1997):862-868.
12. Flaherty, K, Singh N and Richtsmeier JT. "Understanding craniosynostosis as a growth disorder." *Wiley Interdiscip Rev Dev Biol* 5(2016):429-459.
13. Goodrich, JT. "Neurosurgical Operative Atlas." *Thieme Medical Publisher* (2008).
14. Harris, MM, Strafford MA, Rowe RW and Sanders SP, et al. "Venous air embolism and cardiac arrest during craniectomy in a supine infant." *Anesthesiology* 65(1986):547-550.
15. Hashim, PW, Patel A, Yang JF and Travieso R, et al. "The effects of whole-vault cranioplasty versus strip craniectomy on long-term neuropsychological outcomes in sagittal craniosynostosis." *Plast Reconstr Surg* 134(2014):491-501.
16. Magge, KT, Magge SN, Keating RF and Myseros JS, et al. "Incidental findings on preoperative computed tomography for nonsyndromic single suture craniosynostosis." *J Craniofac Surg* 25(2014):1327-1330.
17. Marsh, JL and Vannier MW. "Cranial base changes following surgical treatment of craniosynostosis." *Cleft Palate J* 23(1986):9-18.
18. Matson, D. "Neurosurgery of infancy and childhood. Craniosynostosis Charles C." *Thomas Publisher* 8(1969):122-167.
19. Patel, A, Yang JF, Hashim PW and Travieso R, et al. "The impact of age at surgery on long-term neuropsychological outcomes in sagittal craniosynostosis." *Plast Reconstr Surg* 134(2014):608e-617e.
20. Proctor, MR and Meara JG. "A review of the management of single-suture craniosynostosis, past, present, and future." *J Neurosurg Pediatr* 24(2019):622-631.
21. Renier, D, Sainte RC, Marchac D and Hirsch JF. "Intracranial pressure in craniostenosis." *J Neurosurg* 57(1982):370-7.
22. Schmidek, S. "Sweet operative neurosurgical techniques: Indications, methods and results. Methods for cranial vault reconstruction in craniosynostosis." *El Sevier Philadelphia* 65(2012):768-790.
23. Suarez, JC, Viano JC, Herrera EJ and Marcovecchio A. "Surgical treatment of scaphocephalies." *Neurol Argentina* 31(1991):89-92.
24. Tamburrini, G, Caldarelli M, Massimi L and Santini P, et al. "Intracranial pressure monitoring in children with single suture and complex craniosynostosis: A review." *Childs Nerv Syst* 21(2005):913-21.
25. Thompson, DN, Malcolm GP, Jones BM and Harkness WJ, et al. "Intracranial pressure in single-suture craniosynostosis." *Pediatr Neurosurg* 22(1995):235-40.
26. Whittle, IR, Johnston IH and Besser M. "Intracranial pressure changes in craniostenosis." *Surg Neurol* 21(1984):367-72.
27. Wilkie, AO. "Epidemiology and genetics of craniosynostosis." *Am J Med Genet* 90(2000):82-4.
28. Youmas, S and Winn D. "Neurological Surgery." *Elsevier Philadelphia* 192(2017):2909-2963.

How to cite this article: Rinaudo, Marini FA, Velazquez Quintar DG, Campana JD and Garavaglia FI, et al. "Craniosynostosis: Surgical Treatment and Safety 16 years Experience" *J Neurol Disord* 10(2022):488.