

Craniofacial Plexiform Neurofibroma with Neurofibromatosis Type 1

Dinesh Singh Chauhan R¹ and Yadavalli Guruprasad^{2*}

¹Reader, Department of Oral & Maxillofacial Surgery, AME'S Dental College Hospital & Research Centre, Raichur-584103, Karnataka, India

²Assistant Professor, Department of Oral & Maxillofacial Surgery, AME'S Dental College Hospital & Research Centre, Raichur-584103, Karnataka, India

Abstract

Plexiform neurofibroma is a relatively common but potentially devastating tumor of peripheral nerve sheath and is a manifestation of neurofibromatosis type 1 (NF-1). A substantial number of plexiform neurofibroma causes morbidity. The diffuse and soft nature of plexiform neurofibroma is often difficult to differentiate between a vascular malformation and other similar lesions thus requiring thorough clinical, radiological and histopathological examination of the lesion. We report a case of plexiform neurofibroma in an 18 year female patient.

Keywords: Neurofibromatosis Type 1 (NF-1); Plexiform neurofibroma; Craniofacial

Introduction

Neurofibromatosis Type 1 (Von Recklinghausen's disease) and Neurofibromatosis Type 2 (bilateral acoustic neurofibromatosis) are autosomal dominant disorders in which affected individuals are at an increased risk for developing both benign and malignant tumors. Plexiform neurofibromas (PNs) are one of several types of neurofibroma that occur in NF-1[1]. They are characterized histologically by a proliferation of Schwann cells in the nerve sheath across the length of a nerve, involving multiple fascicles and also can involve multiple nerves. These convoluted masses are classically described by a "bag of worms" appearance [1,2]. PNs are locally invasive, nonmetastasizing, and generally categorized by location. Tumors of the head, neck, and face are most common, followed by lesions of the spine, extremities, mediastinum, and abdomen. PNs can remain silent for many years and may be revealed only by imaging studies [3]. Neurofibromas occasionally cause pain or progressive loss of function from nerve compression. Surgical management of craniofacial plexiform neurofibroma is especially challenging because of the infiltrating nature of these tumors, inherent operative morbidity and tendency for regrowth [3,4]. We report a case of craniofacial plexiform neurofibroma in an 18 year old female with specific emphasis on its clinical, radiological and histopathological features.

Case Report

An 18 year old female patient was referred to department of oral and maxillofacial surgery with a chief complaint of swelling on the left upper part of the face and around the left eye region from past 8 years which gradually drooped to cover the eye and the swelling was insidious in onset which had grown to attain the present size. On further evaluation a diffuse swelling was present on the left zygomatico-temporal and periorbital region measuring around 6.5 x 5cm in size and had indistinct borders (Figures 1 and 2). There was no history of regression or rapid growth in the size of the swelling or any changes in the vision. Further physical examination led to presence of brownish white café-au-lait macules on the trunk measuring from few millimeters to around 4.5-5 cm in diameter which she admitted were present since birth and there was no history of similar lesions in the family and intraoral findings were not significant. There was no presence of Lisch nodules and axillary freckling. Based on the history and clinical findings of café-au-lait spots, a provisional diagnosis of neurofibromatosis type 1 was given. CT scan was advised which revealed a large lobulated mass in the left infratemporal fossa extending into the left orbit causing destruction of the floor of the orbit and extending into the lateral aspect of the orbit. The mass is extended into the middle cranial fossa reaching close to left cavernous sinus (Figures 2, 3 and 4). The patient was then advised

for incisional biopsy which was done under general anesthesia at the region of left upper eyelid region and histopathological examination revealed a section composed of bundles of nerve fibres arranged in concentric manner with Schwann cells and fibroblasts with presence of endoneurial matrix material, resulting in wide separation of the small nerve fascicles suggestive of plexiform neurofibroma (Figures 5 and 6).

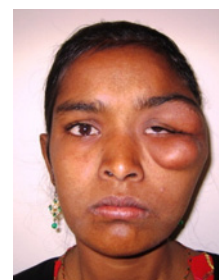

Figure 1: Frontal view showing swelling over the left periorbital and zygomatico-temporal region.

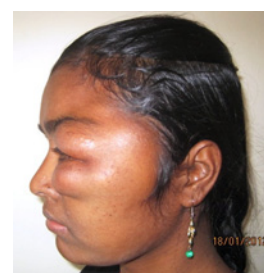

Figure 2: Left lateral view showing diffuse swelling over the zygomatico-temporal region.

***Corresponding author:** Yadavalli Guruprasad, Assistant Professor, Department of Oral & Maxillofacial Surgery, AME'S Dental College Hospital & Research Centre, Raichur-584103, Karnataka, India, Tel: 08532- 240718; E-mail: guru_omfs@yahoo.com

Received February 08, 2012; **Accepted** March 22, 2012; **Published** March 30, 2012

Citation: Dinesh Singh Chauhan R, Guruprasad Y (2012) Craniofacial Plexiform Neurofibroma with Neurofibromatosis Type 1. J Clinic Case Reports 2:119. doi:10.4172/2165-7920.1000119

Copyright: © 2012 Dinesh Singh Chauhan R et al. This is an open-access article distributed under the terms of the Creative Commons Attribution License, which permits unrestricted use, distribution, and reproduction in any medium, provided the original author and source are credited.

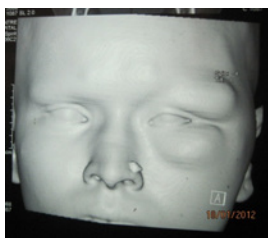

Figure 3: 3D CT scan showing swelling over the left periorbital and zygomatico-temporal region.

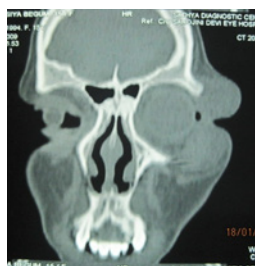

Figure 4: CT coronal view showing lobulated mass in the periorbital region destructing the floor and lateral wall of the orbit.

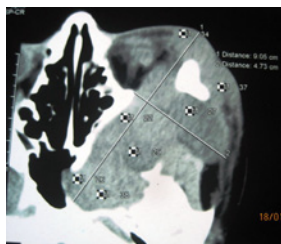


Figure 5: CT Axial view showing lobulated mass in the left infratemporal fossa extending into the middle cranial fossa lateral to left cavernous sinus.

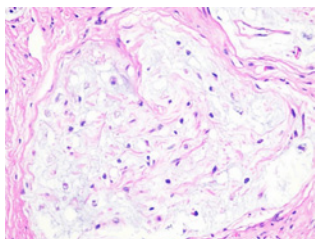


Figure 6: Photomicrograph demonstrates plexiform neurofibroma showing bundles of nerve fibres arranged in concentric manner with Schwann cells and fibroblasts with presence of endoneurial matrix material (Hemotoxylin and Eosin Stain, 40 x magnification).

Discussion

Neurofibromatosis is the most common neurocutaneous syndrome. It is divided into two genetic variants, type-1 and type 2. NF-1 occurs in 1 in 4000 births [3,4]. It is dominant with 100% penetrance. The gene is located on chromosome 17, which codes for the tumor suppressor protein neurofibromin [4]. PNs are slow-growing tumors, which may be present at birth or may become apparent later in life. Their incidence

in patients with neurofibromatosis has not been well established, but they probably occur in anywhere between 25 and 50% of patients, with most series suggesting an incidence of 25–30%. These tumors arise in various regions of the body, including the trunk, limbs, head, and neck. In all of these areas, they can cause dysfunction, including cosmetic abnormalities, pain, and functional deficits. PNs can remain silent for many years and may be revealed only by imaging studies [4,5]. Two types of plexiform neurofibromas have been recognized (1) Diffuse type/neurofibromatosa and (2) nodular type. They can arise anywhere along a nerve and have poorly defined margins. They may appear on the face, legs, or spinal cord and frequently involve the cranial and upper cervical nerves. The cranial nerves most commonly involved in plexiform neurofibromas are fifth, ninth and tenth nerves. They can be quite disfiguring and hemifacial hypertrophy can occur secondary to a plexiform tumor involvement. The consistency of the lesion has been compared to 'bag of worms' because of the presence of soft areas interspersed with firm nodular areas and this consistency was well appreciable in the lesion seen in our patient [4,5].

Neurofibromas are composed of Schwann cells, fibroblasts, mast cells and vascular components. They are characterized histologically by a proliferation of Schwann cells in the nerve sheath across the length of a nerve, involving multiple fascicles and multiple nerves. They consist of poorly organized mixture of nerve fibrils with extensive interlacing of the nerve tissues. These distorted masses of myxomatous peripheral nerve are contained within perineurium and surrounded by neurofibroma [5,6].

Though surgery is the main stay of treatment for solitary neurofibromas, in case of plexiform neurofibromas this is not a cure, because of the invasive nature and location of the tumors, which prevent complete resection [6]. Plexiform neurofibroma is usually entwined with normal tissues and presents problems for the surgeon. Moreover, surgery is not undertaken unless the tumor turns symptomatic or disfiguring leading to an aesthetic problem. In patient with NF-1 there is a propensity for the neurofibromas very rarely to undergo malignant transformation and is especially true for plexiform neurofibromas [7].

Conclusion

Although characteristically benign, plexiform neurofibromas can cause pain, disfigurement and functional changes and more importantly may turn very rarely to malignancy which makes difficult to predict the prognosis of the disease. One salient feature found in all cases of NF-1 is its progressive nature and proceeds towards the worse condition of the disease thus entailing long term follow up of such patients. The indication and timing of surgery or other modalities of treatment in these patients needs to be carefully weighed against the physical and psychological consequences of treatment.

References

1. Gutmann DH, Aylsworth A, Carey JC, Korf B, Marks J, et al. (1997) The diagnostic evaluation and multidisciplinary management of neurofibromatosis 1 and neurofibromatosis 2. *JAMA* 278: 51–57.
2. Havlik RJ, Boaz J (1998) Cranio-orbital-temporal neurofibromatosis; are we treating the whole problem? *J Craniofac Surg* 9: 529-535.
3. Jacquemin C, Bosley TM, Svedberg H (2003) Orbit Deformities in Craniofacial Neurofibromatosis Type 1. *AJNR Am J Neuroradiol* 24: 1678-1682.
4. Jacquemin C, Bosley TM, Liu D, Syedberg H, Buhalinga A (2002) Reassessment of sphenoid dysplasia associated with Neurofibromatosis type 1. *AJNR Am J Neuroradiol* 23: 644-648.
5. George RA, Godara SC, Som PP (2004) Cranio-orbital-temporal

-
- neurofibromatosis : A case report and review of literature. Indian J Radiol Imaging 14: 317-319.
6. Tongsgard JH (2006) Clinical manifestation and management of neurofibromatosis type 1. Semin Pediatr Neurol 13: 2-7.
 7. Patil K, Mahima VG, Shetty SK, Lahari K (2007) Facial plexiform neurofibroma in a child with neurofibromatosis type 1: A case report. J Indian Soc Pedod Prev Dent 25: 30-35.