

Co-Occurrence of Pink1 and Prkn Mutations in a Family: From Isolated Action Tremor to Early Onset Parkinsonism

Anna De R*, Silvio P, Fiore M, Giovanna De M, Leonilda B, Francesco S, Chiara C and Giuseppe De M

Department of Neurosciences and Reproductive and Odontostomatological Sciences, Federico II University, via Pansini 5, Naples, Italy

Abstract

PRKN and PINK1 genes mutations represent the most common cause of autosomal recessive early onset Parkinson's disease (EOPD). We describe coexistence of both genes mutations and apparently dominant Parkinsonism in a family. Two sisters, presenting parental consanguinity and EOPD, carried a homozygous PINK1 deletion and a heterozygous missense PRKN mutation. Their father had late onset PD and resulted compound heterozygous for both mutations. The mother presented action tremor and harbored only one PINK1 deletion. Late onset Parkinsonism in the father could be related to the combination of heterozygous variants in both genes that might lower the threshold of the disease.

Keywords: Parkinson's disease; PRKN; PINK1; Pseudo-dominant inheritance, Digenic mutations

Introduction

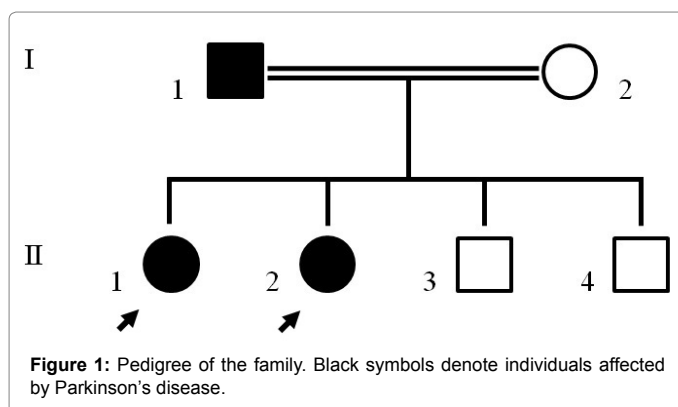
PARK2 and PARK6 represent the most common forms of autosomal recessive Parkinson's disease (PD). PARK2 is linked to mutations in parkin (PRKN) gene and is characterized by early onset PD (EOPD), slow disease progression, good and sustained response to l-dopa [1]. Mutations in PINK1 gene (PARK6) are the second most common cause of EOPD. The clinical phenotype is similar to that of PARK2. Here, we describe a family with apparently dominant Parkinsonism carrying both a PINK1 gene deletion and a PRKN missense mutation.

Case Report

We examined two sisters with EOPD and their first cousins parents (Figure 1). Clinical features are summarized in the Table 1. After obtaining a written informed consent, Sanger sequencing and Multiple Ligation Probe Amplification were performed for the coding exons and exon-intron boundaries of the following genes: PRKN, PINK1, DJ-1 and GBA. We also analyzed LRRK2 gene exons 31 and 41 to test for the most common mutations (R1441C/G/H, G2019S, and I2020T). Both siblings harbored a heterozygous PRKN gene mutation (R402T) and a PINK1 gene deletion (c.1252-2-1272del) in homozygous state (Figure 1). We detected the same PINK1 deletion in heterozygous state in both parents, whereas the heterozygous PRKN mutation was carried only by the father (Figure 1). Two healthy siblings refused to participate in the study.

Case II-1

This 51 year old woman presented mood depression, panic attacks



	Case II-1	Case II-2	Case I-1	Case I-2
Age/gender	51/f	46/f	81/m	67/f
Diagnosis	Pd	Pd	Pd	At
Age at Onset	37	37	78	65
Updrs-iii/HY	17/2	21/2	43/4	-
Asymmetric Onset	Yes	No	No	No
Psychiatric Disorders	Yes	Yes	Yes	Yes
Cognitive Impairment	No	No	Yes	No
Nms	Yes	Yes	Yes	No
Rbd	No	No	No	No
Olfactory Dysfunction	Yes	Yes	Na	Na
PINK1 Gene Mutation	Ex6-7del/ ex6-7del	Ex6-7del/ ex6-7del	Ex6-7del	Ex6-7del
PRKN Gene Mutation	R402t	R402t	R402t	-

Abbreviations: Pd: Parkinson's Disease; AT: Action Tremor; UPDRS-iii: section iii of the Unified Parkinson's Disease Rating Scale; HY: Hohen & Yahr scale; NMS: Non-Motor Symptoms; RBD: Rem Behaviour Disorders; NA: Not Assessed

Nms were evaluated using the non-motor symptoms questionnaire (nmsquest), rbd using the mayo sleep questionnaire, olfactory dysfunction using the university of pennsylvania smell identification test (upsit)

Table 1: Demographic and clinical data.

and resting tremor in the left lower limb at the age of 37 years. At the age of 45 years, the neurological examination showed resting tremor in the lower limbs, mild rigidity and moderate bradykinesia more evident on the left side. Brain MRI showed focal gliosis at the level of the internal capsules and basal ganglia and [¹²³I]-FP-CIT SPECT scan bilateral reduction of the DAT density in the caudate and putamen. Nerve conduction studies resulted normal. After four years, she complained of drooling, excessive sweating, diffuse pains, and constipation. MIBG scintigraphy was normal. Ropinirole, amantadine and rasagiline were

*Corresponding author: Anna De R, Department of Neurosciences, Federico II University Via Pansini, 580131, Italy, Tel: +39-081/7463711; Fax: +39-081/5463663; E-mail: anna_derosa@libero.it; anna.derosa1@unina.it

Received September 17, 2017; Accepted October 09, 2017; Published October 11, 2017

Citation: De RA, Silvio P, Fiore M, De MG, Leonilda B, et al. (2017) Co-Occurrence of Pink1 and Prkn Mutations in a Family: From Isolated Action Tremor to Early Onset Parkinsonism. J Clin Neurol Neurosurg 1: 102.

Copyright: © 2017 De RA, et al. This is an open-access article distributed under the terms of the Creative Commons Attribution License, which permits unrestricted use, distribution, and reproduction in any medium, provided the original author and source are credited.

prescribed. After six years of follow-up, the neurological signs and the UPDRS-III score were substantially unchanged and the benefit from the treatment preserved.

Case II-2

This 47 year old woman, suffering from bipolar disorder, presented resting tremor, pain and numbness at the lower limbs at the age of 37 years. At the age of 41 years, the neurological evaluation was similar to that observed in her sister, but reduced deep tendon reflexes and vibration sense were present. Brain MRI was normal, whereas the SPECT study revealed bilateral decrease of radioligand uptake in the whole striatum, more marked in the right putamen. Nerve conduction studies showed a sensory axonal neuropathy. At cardiac MIBG scintigraphy, early H/M ratio was reduced whereas late H/M ratio and WR resulted normal. She benefited from dopaminergic treatment, but after four years she developed gambling and hobbyism. She complained of dry mouth and snoring. The disease course was slow and after six years of follow-up the clinical picture only slightly worsened.

Case I-1

The 81 year old probands' father presented with slowness of movements, inconstant tremor at upper limbs and gait disorder at the age of 78 years. At the age of 79, he had an ischemic stroke with mild right hemiparesis. Brain CT showed cortical atrophy, white matter diffuse gliosis and a left ventral pontine infarct. After two years, the neurological examination showed difficulty in walking with need for bilateral support, hypomimia, hypophonia, severe symmetric rigidity and bradykinesia, mild cognitive impairment. The response to l-dopa treatment was good. He presented loss of interest, anxiety, depression, drooling, autonomic and sensorial disorders. He refused [¹²³I]-FP-CIT SPECT.

Case I-2

The mother of the two probands was a 70 year old obese woman who has been complained of mood depression and slowness of movements for five years. Neurological examination showed mild postural and kinetic tremor in the upper limbs, but not bradykinesia. Brain MRI showed chronic vascular gliosis in subcortical white matter and cerebral cortical atrophy [¹²³I]-FP-CIT SPECT was normal.

Discussion

We report the coexistence of PRKN and PINK1 variants in two siblings with a mild, slowly progressive EOPD. Olfaction impairment and NMS were present, whereas RBD was denied. Both patients had severe psychiatric disorders and Case II-2 developed impulsive control disorders (ICD) after dopaminergic treatment. NMS and ICD have been reported in a series of PINK1 patients [2].

The Parkinsonism resulted apparently dominantly inherited: the father, which harbored both PINK1 and PRKN genes mutations in heterozygous state, developed late onset Parkinsonism; the mother carried a heterozygous PINK1 gene mutation and presented action tremor, but not other parkinsonian features. The 23 bp PINK1 deletion (c.1252-2_1272del) has been reported in a compound heterozygous patient with a deletion of the entire gene on the other allele [3]. The deletion, affecting the junction between intron 6 and exon 7, causes abnormal RNA splicing. The R402C PRKN mutation has been reported in several EOPD patients, although its pathogenic role is still debated [4].

We already reported pseudo-dominant Parkinsonism in PARK6 [5]. The proband carried the homozygous mutation W437X in PINK1

gene and the mother was heterozygous for the same mutation. Both patients also carried two new missense homoplasmic mutations of mtDNA [6].

Furthermore PARK2-PARK6 digenic cases have been also described [7]. It has been suggested that the combination of PRKN and PINK1 mutations may affect the disease phenotype and clinical course and that it is more often associated with psychiatric disorders [8].

The role of single, heterozygous PRKN and PINK1 genes mutations as causative or susceptibility factor for PD development is still matter of debate. Most research showed that frequencies of heterozygous PRKN and PINK1 mutations are not significantly higher in PD cases than in controls [9]. On the other hand, decreased [¹⁸F]-Fluorodopa-uptake by PET and hyperechogenicity of the substantia nigra have been widely reported in asymptomatic carriers of heterozygous PRKN and PINK1 genes mutations, suggesting that these subjects may be at risk to develop PD [10-13].

It is likely that heterozygous mutations might be not sufficient to cause a clinically evident disease, but, resulting in a subclinical nigrostriatal dysregulation and a lower threshold of the disease, may lead to symptomatic disease when associated with other environmental and/or genetic factors. In fact, parkin and PINK1 share a common biological pathway and interact to regulate several cellular activities, in particular mitochondrial dynamics, transport, and autophagy, and parkin is phosphorylated into its active form by PINK1.

Conclusion

In conclusion, we can speculate that pseudo-dominant inheritance in this family may be explained by digenic PINK and PRKN mutations in the father, although a possible pathogenic role of his cerebrovascular disease cannot be excluded. The occurrence of three mutations in the siblings was not associated with a clinical picture more severe than previously observed in cases with PINK1 gene mutations. However, one of the two probands also presented a sensory neuropathy not related to other known causes. This finding may be found in PARK2 but has not been previously reported in PARK6. The relationship between isolated action tremor and a single PINK1 mutation in the mother is difficult to define, however postural and kinetic tremor mimicking essential tremor has been described in heterozygous carriers of PRKN mutations [14].

References

1. Ricciardi L, Petrucci S, Guidubaldi A, Ialongo T, Serra L, et al. (2014) Phenotypic variability of pink1 expression: 12 years' clinical follow-up of two italian families. *Mov Disord* 29: 1561-1566.
2. Marongiu R, Brancati F, Antonini A, Ialongo T, Ceccarini C, et al. (2007) Whole gene deletion and splicing mutations expand the pink1 genotypic spectrum. *Hum Mutat* 28: 98.
3. Fokkema IF, Taschner PE, Schaafsma GC, Celli J, JF Laros, et al. (2011) LOVD v.2.0: The next generation in gene variant databases. *Hum Mutat* 32: 557-563.
4. Criscuolo C, Volpe G, De Rosa A, Varrone A, Marongiu R, et al. (2006) Pink1 homozygous w437x mutation in a patient with apparent dominant transmission of parkinsonism. *Mov Disord* 21: 1265-1267.
5. Piccoli P, Ripoli M, Quarato G, Scrima R, Boffoli D, et al. (2008) Coexistence of mutations in pink1 and mitochondrial dna in early onset parkinsonism. *J Med Genet* 45: 596-602.
6. Monroy-Jaramillo N, Guerrero-Camacho JL, Rodríguez-Violante M, Coehrlen M, Yescas-Gómez P, et al. (2014) Genetic mutations in early-onset parkinson's disease mexican patients: Molecular testing implications. *Am J Med Genet B Neuropsychiatr Genet* 165: 235-244.
7. Funayama M, Li Y, Tsoi TH, Lam CW, Ohi T, et al. (2006) Familial parkinsonism with digenic parkin and pink1 mutations. *Mov Disord* 21: 1265-1267.

8. Brooks J, Ding J, Simon-Sanche J, Paisan-Ruiz C, Singleton AB, et al. (2009) Parkin and pink1 mutations in early-onset parkinson's disease: comprehensive screening in publicly available cases and control. *J Med Genet* 46: 375-381.
9. Hilker R, Klein C, Ghaemi M, Kis B, Strotmann T, et al. (2011) Positron emission tomographic analysis of the nigrostriatal dopaminergic system in familial parkinsonism associated with mutations in the parkin gene. *Ann Neurol* 49: 367-376.
10. Eggers C, Schmidt A, Hagenah J, Brüggemann N, Klein JC, et al. (2010) Progression of subtle motor signs in pink1 mutation carriers with mild dopaminergic deficit. *Neurology* 74: 1798-1805.
11. Hagenah JM, König IR, Becker B, Hilker R, Kasten M, et al. (2007) Substantia nigra hyperechogenicity correlates with clinical status and number of parkin mutated alleles. *J Neurol* 254: 1407-1413.
12. Hagenah JM, Becker B, Brüggemann N, Djarmati A, Lohmann K, et al. (2008) Transcranial sonography findings in a large family with homozygous and heterozygous pink1 mutations. *J Neurol Neurosurg Psychiatry* 79: 1071-1074.
13. Pellecchia MT, Varrone A, Annesi G, Amboni M, Cicarelli G, et al. (2007) Parkinsonism and essential tremor in a family with pseudo-dominant inheritance of park2: An FP-CIT SPECT study. *Mov Disord* 22: 559-563.