

Case Report

Open Access

Contribution of Manual Fusion in a Multiple Bone Metastasis Breast Carcinoma Patient: Clinical Case

Agolti Mariela*, Bioing Solari Lucrecia and Aruga Camila

Nuclear Medicine Service, Model Clinic, Paraná. Between Rivers, Argentine Republic

*Corresponding author: Agolti Mariela, Nuclear Medicine Service, Model Clinic, Paraná. Between Rivers, Argentine Republic, E-mail: marielsmednuc@hotmail.com

Received date: June 24, 2018; Accepted date: July 28, 2018; Published date: July 30, 2018

Copyright: ©2018 Mariela A, et al. This is an open-access article distributed under the terms of the Creative Commons Attribution License, which permits unrestricted use, distribution, and reproduction in any medium, provided the original author and source are credited.

Abstract

Background and Introduction: The total bone scintigraphies remains an important technique in the detection and follow up of bone metastases in breast cancer for making a therapeutic decision. We started to fuse images since 2016 and we think software fusion is a very useful tool in some selected patients.

Keywords: Breast Carcinoma; Scintigraphies; Bone metastasis

Clinical Case

This is female 63 years old patient followed up during January 2016 to August 2017 in which we found multiple blastic bone metastasis, and in CT a bone angioma in Lumbar 1 vertebrae. During the follow up this image changed since the CT of January 2016 to August 2017 (Figure 1), turning into a cold image to a hot image in bone scintigraphy (Figure 2). Breast Carcinoma

Comparing both morphological and metabolic figures we can see in the last SPECT fused with CT (Figures 3 and 4) a new blastic image in the first lumbar vertebrae that it is corregristrated with a new blastic image over the previous angioma.

The SPECT acquisition was done three hours after 26 mCi of 99m-Tc Methylene Diphosphonate administration the planar bone scintigraphy and SPECT acquisition were done un a unique head adquisition System (Cámara Gamma Alfa Nuclear R91, Upgrade de Starcam®-GE Healthcare) with a low energy high resolution colimator, 20 second/projection; 64 projections over 360 degrees with uniformity correction and an iterative reconstruction The acquisition of computerized axial tomography with 16-channel Multislice tomograph, Brightspeed General Electric® model.

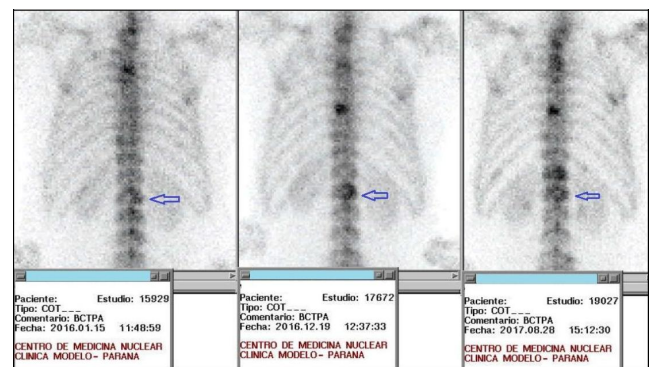


Figure 2: Posterior planar bone scan evolution from January 2016 to August.

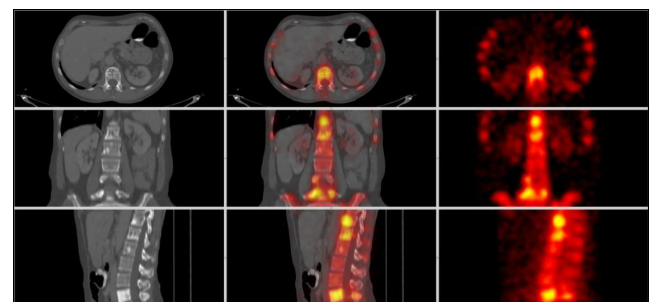


Figure 3: SPECT fused with CT of August 2017.

It was performed in the same clinic, in different services. A bone window was used for the interpretation of the images with WW 1500 UH and WL 250 UH. All the images used were acquired and processed in DICOM format.

The fusion was performed in a manual way guided only by anatomical referents, in a work station, making use of the Horos Project® software.

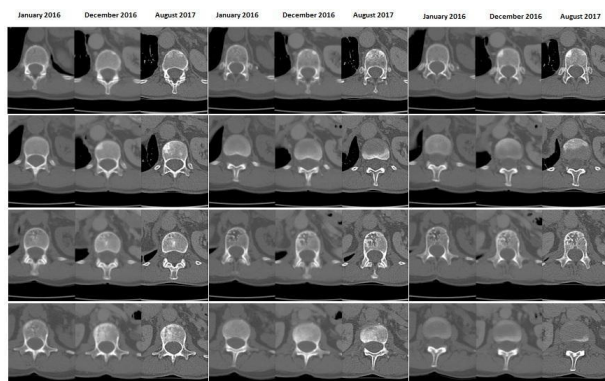


Figure 1: Comparative CT series axial images January 2016, December 2016 and August 2017 (follow up).

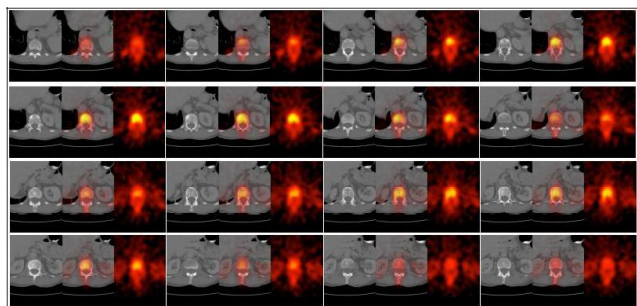


Figure 4: Series SPECT fused with CT of August 2017.

Discussion

Hemangioma of spine usually presents as an asymptomatic condition. Its appearance in planar bone scintigraphy varies from normal in most cases [1,2], to photopenic image [3] and in some cases Hypermetabolism, the reason for this could be related to calcification in old Hemangiomas or sclerotic changes in involved bone, in this case the first suspicious was this last condition, moreover considering that the only image with higher uptake was in the 1st lumbar vertebrae, however in the fusion image with CT the bone window showed blastic progressive image. As in many bibliographies the fusion is more

specific than the Bone scintigraphy or the CT alone. Also it is important for us that even we don't have hybrid equipment, using free software we were able to get the best of these two techniques, and allowed us to report a Progressive disease.

Conclusion

The response evaluation is a very important tool for making decisions, moreover in cancer treated patients. There are many new options in advanced disease, particularly in breast cancer; only a good diagnosis allows a good treatment, in this case the manual fusion was a very important tool for the diagnosis of a new bone metastasis and in this particular case we show how without an hybrid equipment, we were able to do a good diagnosis. We believe in every patient with suspicious images, manual fusion is more specific in stadification and re stadification in bone lesions.

References

1. Love C (2003) Radionuclide Bone Imaging: An Illustrative Review. Radiographics 23: 341-358.
2. Han BK (1995) Bone SPECT imaging of vertebral hemangioma correlation with MR imaging and symptoms. Clinical Nuclear Medicine 20: 916-921.
3. Gerard PS, Wilck E (1992) Spinal hemangioma: An unusual photopenic presentation on bone scan. Spine 17: 607-610.