

Confocal Microscopy in Diagnosis and Management of Melasma: Review of Literature

Dimitris Sgouros^{1*}, Giovanni Pellacani², Alexandros Katoulis¹, Dimitris Rigopoulos¹ and Caterina Longo³

¹2nd Department of Dermatology, "ATTIKON" University Hospital of Athens, Athens, Greece

²Department of Dermatology, University of Modena and Reggio Emilia, Modena, Italy

³Dermatology and Skin Cancer Unit, First Medical Department, Arcispedale Santa Maria Nuova, IRCCS, Reggio Emilia, Italy

Abstract

Background: Melasma is a common acquired disorder of hyperpigmentation mainly located on the face. Classification and clinical evaluation of melasma is the first step of any therapeutic strategy. Reflectance Confocal Microscopy (RCM) is a novel, non-invasive technique that offers an in vivo analysis of the skin layers at a cellular level resolution.

Objective: To assess the efficacy of the application of RCM in the diagnosis and management of melasma.

Methods: A search of all the available literature concerning the use of RCM in melasma was performed on Pubmed Medline. In total ten papers were selected and reviewed.

Results: Melasma seems to exhibit a specific pattern in RCM analysis. Correlation of histopathology and RCM revealed common findings among the relevant studies. Epidermal hyperpigmentation – a hallmark of melasma – is represented as a honeycombed pattern, mottled pigmentation and strongly visible papillary rings around the dermal papillae, composed by a sequence of brighter cellular structures at the level of the dermo-epidermal junction. Dermal melanin has the appearance of plump bright particles corresponding to melanophages. RCM reveals an epidermal portion in all melasma lesions rendering obsolete the up to present classification of the disease, which is based on Wood's lamp examination. Even clinically undetectable changes during melasma treatment can be detected by means of RCM analysis introducing the technique as a highly sensitive tool for the monitoring and evaluation of treatment.

Conclusion: RCM emerges as a reliable adjuvant technique for the classification, diagnosis and overall management of melasma. Further studies need to be conducted in order to investigate the prospective of in vivo RCM in melasma.

Keywords: Melasma; Chloasma; Reflectance confocal microscopy

Introduction

Melasma is an acquired disorder of light – to – dark-brown hyperpigmentation that affects millions of people worldwide. It occurs most frequently in women with Fitzpatrick skin phototypes III through V. It is commonly found on the face and occasionally on other sun-exposed areas (neck, forearms etc). The exact pathogenesis of melasma remains unknown but the role of intense UV light exposure and sexual hormones during pregnancy is crucial for the triggering or exacerbation of the disorder [1,2].

Treatment of melasma is challenging and requires a multimodal approach including photoprotection, topical depigmenting formulations, chemical peels, lasers and light sources [3]. Although treating melasma can be considered of aesthetic value, therapy of the so-called "mask of pregnancy" can be an economical and emotional burden for the patient. A long period of time and a combination of therapeutic options are often required, in order to achieve the desired result.

The first step of any therapeutic strategy is the accurate clinical evaluation of the patient. Parameters to consider are the anatomical site of the hyperpigmentation, gender, age, phototype and medical history (drugs etc.). Melasma history is also important, since duration of lesions, pattern of onset, previous treatments or even the nature of the disease itself (first episode or recurrent) can influence the selection of treatment [4,5].

Apart from the aforementioned characteristics, the leading factor determining the therapeutic regimen of melasma is the exact assessment of the distribution and depth of melanin of the lesion [5]. Up until today the Wood's lamp examination has been used for both the classification of melasma and monitoring of therapy, herein

categorizing melasma into three clinical types; epidermal (melanin present within epidermis layers), dermal (melanin and melanophages in the dermis) and mixed type (combination of the first two types) [6].

Recent studies have shown a poor correlation between Wood's lamp classification and histological features of melasma [7,8] accentuating the need for a more standardized and precise method of in vivo evaluation for the diagnosis and therapeutic response of melasma.

In vivo Reflectance Confocal Microscopy (RCM) is a relatively novel, innovative technique that allows the non-invasive imaging of epidermis and upper dermis at a cellular level resolution, interpreting the light reflectance indexes of several skin structures [5,9]. RCM is widely used for the diagnosis of pigmented tumors [10,11] and several inflammatory skin diseases [12-17] offering an excellent correlation with histologic findings. Since melanin is the strongest endogenous contrast of the skin, cutaneous disorders with abnormal amounts of melanin seem to be the most suitable candidates for RCM examination [9]. Specifically, RCM can precisely detect melanocytes, pigmented keratinocytes and melanophages within epidermis and superficial dermis, thus emerging as a valid tool for the overall management of

***Corresponding author:** Dimitris Sgouros, 2nd Department of Dermatology, "ATTIKON" University Hospital of Athens, Rimini 1, 12462, Chaidari, Athens, Greece, Tel: 00306974816025; Fax: 00302105832396; E-mail: disgo79@gmail.com

Received: October 20, 2014; **Accepted:** October 22, 2014; **Published:** October 25, 2014

Citation: Sgouros D, Pellacani G, Katoulis A, Rigopoulos D, Longo C (2014) Confocal Microscopy in Diagnosis and Management of Melasma: Review of Literature. *Pigmentary Disorders* S1:004. doi: [10.4172/JPD.S1-005](https://doi.org/10.4172/JPD.S1-005)

Copyright: © 2014 Sgouros D et al. The terms of the Creative Commons Attribution License, which permits unrestricted use, distribution, and reproduction in any medium, provided the original author and source are credited.

melasma [5,18,19]. The purpose of this review is to assess the value of confocal microscopy in the diagnosis, treatment and follow-up of melasma.

Material and Methods

A search of all the available literature was performed on Pubmed Medline during the years 2009-2014. The following keywords were searched: reflectance confocal microscopy, melasma, chloasma. A total of 10 papers were selected for the review. Specifically, the papers concerned studies correlating clinical and histopathologic features of melasma with confocal microscopy findings (2 papers), assessment of the efficiency of treatment modalities in terms of confocal microscopy features (5 papers), case reports (2 studies) and letters to the editor (1 correspondence).

Results

Despite the small number of publications concerning the use of reflectance confocal microscopy (RCM) in melasma, useful preliminary results can be already recorded [5,9,20-27]. Correlation of histopathology and RCM in melasma revealed common findings among the relevant studies [9,20]. Specifically 2 out of 9 studies attempted to correlate histological findings of biopsied skin specimens with RCM features.

Kang HY et al. recruited twenty-six patients with facial hyperpigmentation. RCM examination of melasma lesions and the adjacent skin was performed and RCM images were acquired at three levels; suprabasal layer, dermo-epidermal junction (DEJ) and dermis. Biopsies were obtained from eight patients.

RCM features of melasma in the epidermis revealed hyperrefractile cobblestone pattern in the basal cell layer and occasionally in the lower stratum spinosum, compared to the normal perilesional area. Histology confirmed the correlation of this pattern with increased amounts of melanin in epidermis. Most of the patients also showed an abrupt transition from stratum spinosum to papillary dermis in the RCM examination, corresponding to flattened rete ridges in all of the biopsy specimens. Five out of twenty-six patients with preserved rete ridges appeared with brighter papillary rings in melasma lesions. In six out of twenty-six patients, RCM revealed only in the lesional skin bright dendritic cells at the level of DEJ. These cells were immunohistochemically identified as activated melanocytes and not as Langerhans cells. RCM imaging of the upper dermis showed plump bright cells in nine of 26 patients, which corresponded to melanophages, a finding that was confirmed by histopathology studies. In four out of these nine patients, scattered melanophages were detected, partly explaining the uneven distribution of melanin in a given melasma region. RCM features of ragged, less refractile, lacy structures corresponded to increased solar elastosis of lesional skin, compared with normal adjacent skin. Finally, increased number of vessels in melasma appeared as dark, round or tubular structures within papillary dermis in RCM imaging [9].

Liu et al. enrolled 210 patients with facial melasma. In ten of these patients, skin biopsies were performed at the same site of RCM examination. RCM image-blocks were taken at four levels; stratum spinosum, basal cell layer, DEJ and dermis. All biopsy specimens showed increased amount of melanin in epidermis compared to perilesional skin. The hyperpigmentation of epidermis corresponded to highly refractile keratinocytes distributed in the spinous layer. RCM examination of the DEJ revealed strongly visible papillary rings around the dermal papillae, composed by a sequence of bright cellular

structures or hyperrefractile cobblestone pattern in the flattened basal cell layer, mostly seen on the forehead and upper lips. In general, a significant increase of highly refractile melanin in all the layers of epidermis was seen by means of RCM. Some RCM images showed an abrupt transition from stratum spinosum to papillary dermis, corresponding to flattened rete ridges, especially on the cheeks.

At the level of superficial dermis, an abnormal presence of round or polygonal refractile structures within dermal collagen bundles was detected. Activated melanocytes had the form of dendritic or polymorphic RCM structures. Notably, all specimens showed increased melanin in all the epidermal layers and few had melanin in the dermis, enhancing the allegation that actually there is no true dermal type of melasma [20]. RCM examination has been also used for the evaluation of treatment response in melasma.

Ardigò et al. conducted a study in order to investigate RCM features of melasma within epidermis and upper dermis and assess the usefulness of the technique in the monitoring of therapy. Researchers enrolled fifteen patients with facial melasma and matched them with a control group of 10 patients. Concerning the distribution of pigment within skin layers their findings were almost in accordance with the results extracted in the aforementioned studies. Specifically, increased degree of epidermal pigment was seen as highly refractile keratinocytes with prominent nuclei at the level of stratum spinosum. Activated melanocytes and junctional keratinocytes receiving packed melanosomes were detected at the DEJ, appearing as strongly visible papillary rings around the dermal papillae composed by sequence of brighter cellular structures. In the upper dermis abnormal presence of fuzzy, round or polygonal refractile structures within collagen bundles prevailed, corresponding to melanophages originating in the DEJ, which followed an extremely variable distribution. The role of possible Langerhans cells was proposed for dendritic cellular structures found in the spinous layer in five out of 15 patients, without, however, any pathologic confirmation. Authors highlight the fact that in this study there was no correlation between pigment distribution assessed by both RCM and Wood's lamp [5].

Monitoring treatment response, a statistically significant decrease in brightness, mainly at the epidermis and the DEJ, was recorded in the total of five patients who were treated with a combination of a chemical peel of pyruvic acid 50% and a topical application of Kligman's formula containing 2% hydroquinone. Specifically, RCM revealed a reduction of pigmented bright keratinocytes within epidermis and a major decrease in brightness around dermal papillae in 2 out of 5 patients, while the rest of them had a significant clinical improvement, but still showed small traces of pigment. Concerning dermal depigmentation, the results were less enthusiastic with a partial reduction in the number of bright polygonal structures in the upper dermis, which corresponded to melanophages as previously mentioned. Noteworthy were the RCM findings in the three remaining patients receiving hydroquinone treatment who presented with clinically obvious light erythema; the findings were consistent with inflammation, including vasodilatation in the upper dermis, associated with dermal infiltration of bright, round cells corresponding to inflammatory cells [5].

Longo et al. studied the efficacy of low-energy Q-switched laser treatment of melasma by means of RCM. Eight female patients with facial melasma were recruited and were subjected to low-energy Q-switched Nd:YAG laser (1,064 nm) treatment. In total, nine laser sessions were performed. Confocal examination took place at baseline, after 5 and after 9 sessions. Clinically, all patients improved and RCM

confirmed the efficacy of this type of laser treatment for melasma. In particular, baseline RCM features corresponding to epidermal hyperpigmentation included honeycombed pattern as well as a mottled pigmentation of a cluster of bright keratinocytes in three cases (3/8). Bright dendritic peri-follicular cells were detected in one case. At the DEJ, all cases showed bright polycyclic contours and bright hair follicles/rings, which correspond to the pigmented keratinocytes and melanin-rich melanocytes located at the basal and suprabasal layers of an elongated rete ridge. Authors highlight these findings as a biologic response of the skin to the UV injury that plays an important role in the development and maintenance of melasma. In the superficial dermis no RCM features of melasma were observed.

After nine laser sessions, neither mottled pigmentation, nor polycyclic papillary contours were detected confirming the obvious clinical improvement. However, 3 cases showed dendritic-shaped cells with a bright body cell and peripheral branching structures focally distributed around hair follicles, and interestingly, these were the cases presenting with a relapse of melasma after 3 months of follow-up [21].

Goberdhan et al assessed the efficacy of a superficial chemical peel combined with a multimodal, hydroquinone-free brightener, using RCM in three patients, thus also confirming the reliability of confocal analysis for the evaluation of treatment in melasma [22]. Tsilika et al. conducted a clinical trial in ten patients assessing a non-hydroquinone topical bleaching agent, by means of RCM. Authors report a discrepancy between Wood's lamp and RCM classification of melasma at treatment baseline. After one month of treatment, there was concordance between clinical improvement and RCM findings, particularly a substantial decrease of hyper-refractile cobblestoning basal cells associated with a decrease in the number of pigmented keratinocytes as well. Partial clinical response was reported for patients with melanophages observed within dermis by means of RCM [23]. Costa et al. reported a case of melasma presenting bright dendritic cells within the epidermis and bright irregularly shaped structures among bundles of collagen in the superficial dermis, corresponding to activated melanocytes and melanophages, respectively [24]. Similar RCM findings were reported in a case of melasma by Funasaka et al. [25]. Zhou et al. performed RCM examination in six out of fifty melasma patients who were treated by Q-switched Nd:YAG laser (1,064 nm). RCM findings were in accordance with previous studies, confirming the usefulness of in vivo confocal analysis in the evaluation of melasma treatment [26] (Figures 1 and 2).

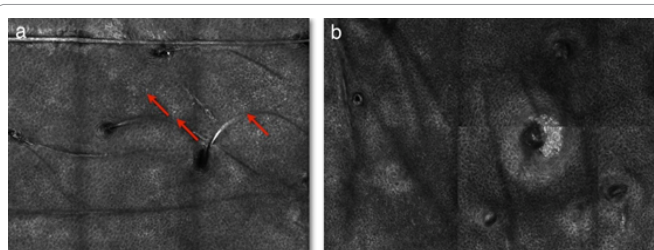


Figure 1: RCM findings of melasma in epidermis before and after Q-switched laser treatment.

a. Image at the level of the stratum spinosum at the baseline of treatment (T0). Pattern of mottled pigmentation composed of clusters of bright keratinocytes (red arrows).

b. The epidermis at the same level after 10 laser sessions (T10). No mottled pigmentation is detected. Regular keratinocytes composing a normal honeycombed pattern.

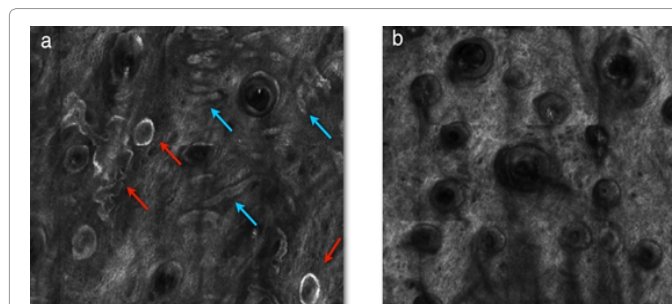


Figure 2: RCM findings of melasma at the dermo-epidermal junction (DEJ) before and after Q-switched laser treatment.

a. Image at the level of the DEJ at baseline (T0). RCM image reveals bright rings (red arrows) and bright polycyclic papillary contours (blue arrows) due to pigmented keratinocytes and melanin-rich melanocytes.

b. RCM findings at T10. Absence of brightness (i.e. pigment) and a regular DEJ is seen after 10 laser sessions (T10).

Discussion

Reflectance Confocal Microscopy emerges as a novel, non-invasive tool for the in vivo evaluation of several skin diseases, beyond pigmented skin tumors [12-17]. The technique is based on the endogenous contrast provided by several particles of the skin, i.e. melanin, keratin, hemoglobin, cellular organelles etc. [5]. Since melanin is the strongest source of contrast, RCM seems to emerge as an optimal tool for the evaluation of melasma. However, up to present a limited number of studies have been conducted investigating the role of RCM in melasma.

The traditional classification of melasma into epidermal, dermal and mixed type, based on the enhancement of hyperpigmentation on Wood's lamp examination [6], has been challenged by later studies [7,8]. Ardigo et al., Kang et al. and Liu et al. reported an epidermal portion in all the melasma lesions investigated by means of RCM, reviewing the notion of the existence of a true dermal type of melasma [5,9,20]. Thus, a new classification of melasma is proposed with two categories according to the depth of melanin in a given melasma lesion; epidermal and mixed type.

RCM findings provide a consistent profile of melasma confocal characteristics, which are in accordance with histopathology features. Epidermal hyperpigmentation, a hallmark of melasma in histological studies, [9] is observed as a honeycombed pattern, mottled pigmentation and strongly visible papillary rings around the dermal papillae, composed by a sequence of brighter cellular structures at the level of the DEJ [5,21]. The presence of pigment within dermis has the stereotypical appearance of plump bright particles corresponding to melanophages [9], which are larger than inflammatory cells and smaller than neoplastic melanocytes when presenting dendritic features [27,28]. Of note, are the confocal findings of the irregularly shaped dermal papillae and the ragged, less refractile lacy structures, corresponding to elongated rete ridges and marked solar elastosis respectively, both strong signs of UV-damage [5,9,20]. The role of UV injury in melasma pathogenesis is well-established [2] but RCM opens a new insight into the UV-induced cellular changes occurring in lesions of melasma that has to be further investigated. Post-inflammatory hyperpigmentation presents frequently as a problem in the differential diagnosis of melasma. RCM offers a reliable tool for the precise differentiation of the two pigmentary disorders. Although the clinical background is of definite diagnostic value, RCM can give the answer especially in ambiguous cases. In contrast to melasma, RCM of post-inflammatory hyperpigmentation exhibits strongly bright rims at the level of DEJ while epidermis is less prominently involved and the

cobblestone pattern is less frequently encountered than in melasma. Another characteristic feature on RCM, is the absence of bright melanophages in the dermis, an otherwise typical histopathologic characteristic of post-inflammatory hyperpigmentation, which can be explained by the fact that melanophages lie within deep papillary or/and reticular dermis where RCM has a limited penetration. Thus, the discrimination of these specific disorders of hyperpigmentation is clearly provided by two different patterns of RCM [28].

Melasma treatment sometimes turns out to be a pitfall for Dermatologists. Despite the various therapeutic options, it is not a rare clinical scenario to fail in achieving a successful result or having to deal with sequential relapses. Concerning treatment difficulties of melasma, the role of activated melanocytes becomes of interest. These cells are represented as bright dendritic cellular structures at the level of the DEJ in RCM analysis [5,9,20,21]. Kang et al define them by immunohistochemical analysis as true melanocytes – not Langerhans cells – also denoting their effect during the active pigmentation process of the human skin [9]. Worthy of mention is the fact that this finding is previously reported only by means of electron microscopy [9]. Longo et al. remark their perifollicular distribution and describe their presence in cases with an early relapse of melasma after laser treatment, suggesting their influence in the therapeutic outcome [21].

Up to present a strongly definitive factor for the success or even the selection of treatment has been the distribution of melanin in the skin. It is well-documented that the presence of melanophages in the dermis signals a poor therapeutic outcome. RCM shows that the distribution of melanophages is not homogeneous throughout a given melasma lesion, a finding perhaps interfering with therapy [9]. This is also another comparative advantage of RCM upon histopathology since an entire hyper-pigmented macule or plaque can be analyzed thoroughly in vivo. RCM seems to offer a reliable “mapping” of melanin distribution in melasma, being an excellent guide not just for selection, but for monitoring of treatment as well, since confocal analysis is a highly sensitive instrument for detecting even clinically undetectable cell changes during treatment of melasma [5,21-23,26].

In conclusion, RCM emerges as a reliable adjuvant tool for the classification, diagnosis and overall management of melasma. Moreover, RCM provides the chance to further analyze cellular changes in melasma helping to understand not well-decoded aspects of the pathogenesis of the disorder. However, further studies need to be conducted in order to investigate the prospective of in vivo RCM in melasma.

References

- Rigopoulos D, Gregoriou S, Katsambas A (2007) Hyperpigmentation and melasma. *J Cosmet Dermatol* 6: 195-202.
- Sheth VM, Pandya AG (2011) Melasma: a comprehensive update: part I. *J Am Acad Dermatol* 65: 689-697.
- Sheth VM, Pandya AG (2011) Melasma: a comprehensive update: part II. *J Am Acad Dermatol* 65: 699-714.
- Gupta AK, Gover MD, Nouri K, Taylor S (2006) The treatment of melasma: a review of clinical trials. *J Am Acad Dermatol* 55: 1048-1065.
- Ardigo M, Cameli N, Berardesca E, Gonzalez S (2010) Characterization and evaluation of pigment distribution and response to therapy in melasma using in vivo reflectance confocal microscopy: a preliminary study. *J Eur Acad Dermatol Venereol* 24: 1296-1303.
- Sanchez NP, Pathak MA, Sato S, Fitzpatrick TB, Sanchez JL, et al. (1981) Melasma: a clinical, light microscopic, ultrastructural, and immunofluorescence study. *J Am Acad Dermatol* 4: 698-710.
- Grimes PE, Yamada N, Bhawan J (2005) Light microscopic, immunohistochemical, and ultrastructural alterations in patients with melasma. *Am J Dermatopathol* 27: 96-101.
- Sarvjit V, Sharma S, Mishra S, Singh A (2009) Melasma: a clinicopathological study of 43 cases. *Indian J Pathol Microbiol* 52: 357-359.
- Kang HY, Bahadoran P, Suzuki I, Zugaj D, Khemis A, et al. (2010) In vivo reflectance confocal microscopy detects pigmentary changes in melasma at a cellular level resolution. *Exp Dermatol* 19: e228-233.
- Pellacani G, Guitera P, Longo C, Avramidis M, Seidenari S, et al. (2007) The impact of in vivo reflectance confocal microscopy for the diagnostic accuracy of melanoma and equivocal melanocytic lesions. *J Invest Dermatol* 127: 2759-2765.
- Pellacani G, Longo C, Malvehy J, Puig S, Carrera C, et al. (2008) In vivo confocal microscopic and histopathologic correlations of dermoscopic features in 202 melanocytic lesions. *Arch Dermatol* 144: 1597-1608.
- Ardigò M, Maliszewski I, Cota C, Scope A, Sacerdoti G, et al. (2007) Preliminary evaluation of in vivo reflectance confocal microscopy features of Discoid lupus erythematosus. *Br J Dermatol* 156: 1196-1203.
- Ardigo M, Maliszewski I, Dell'anna ML, Berardesca E, Picardo M (2007) Preliminary evaluation of vitiligo using in vivo reflectance confocal microscopy. *J Eur Acad Dermatol Venereol* 21: 1344-1350.
- Middelkamp-Hup MA, Park HY, Lee J, Gilchrist BA, Gonzalez S (2006) Detection of UV-induced pigmentary and epidermal changes over time using in vivo reflectance confocal microscopy. *J Invest Dermatol* 126: 402-407.
- González S, Rajadhyaksha M, Rubinstein G, Anderson RR (1999) Characterization of psoriasis in vivo by reflectance confocal microscopy. *J Med* 30: 337-356.
- Ardigo M, Cota C, Berardesca E, González S (2009) Concordance between in vivo reflectance confocal microscopy and histology in the evaluation of plaque psoriasis. *J Eur Acad Dermatol Venereol* 23: 660-667.
- Cinotti E, Fouilloux B, Perrot JL, Labeille B, Douchet C, et al. (2014) Confocal microscopy for healthy and pathological nail. *J Eur Acad Dermatol Venereol* 28: 853-858.
- González S, Gilaberte-Calzada Y (2008) In vivo reflectance-mode confocal microscopy in clinical dermatology and cosmetology. *Int J Cosmet Sci* 30: 1-17.
- Rajadhyaksha M, Grossman M, Esterowitz D, Webb RH, Anderson RR (1995) In vivo confocal scanning laser microscopy of human skin: melanin provides strong contrast. *J Invest Dermatol* 104: 946-952.
- Liu H1, Lin Y, Nie X, Chen S, Chen X, et al. (2011) Histological classification of melasma with reflectance confocal microscopy: a pilot study in Chinese patients. *Skin Res Technol* 17: 398-403.
- Longo C, Pellacani G, Toulaki A, Galimberti M, Bencini PL (2014) Melasma and low-energy Q-switched laser: treatment assessment by means of in vivo confocal microscopy. *Lasers Med Sci* 29: 1159-1163.
- Goberdhan LT, Mehta RC, Aguilar C, Makino ET, Colvan L (2013) Assessment of a superficial chemical peel combined with a multimodal, hydroquinone-free skin brightener using in vivo reflectance confocal microscopy. *J Drugs Dermatol* 12: S38-41.
- Tsilika K, Levy JL, Kang HY, Duteil L, Khemis A, et al. (2011) A pilot study using reflectance confocal microscopy (RCM) in the assessment of a novel formulation for the treatment of melasma. *J Drugs Dermatol* 10: 1260-1264.
- Costa MC, Eljaiek HV, Abraham LS, Azulay-Abulafia L, Ardigo M (2012) In vivo reflectance confocal microscopy in a typical case of melasma. *An Bras Dermatol* 87: 782-784.
- Funasaka Y, Mayumi N, Asayama S, Takayama R, Kosaka M, et al. (2013) In vivo reflectance confocal microscopy for skin imaging in melasma. *J Nippon Med Sch* 80: 172-173.
- Zhou X, Gold MH, Lu Z, Li Y (2011) Efficacy and safety of Q-switched 1,064-nm neodymium-doped yttrium aluminum garnet laser treatment of melasma. *Dermatol Surg* 37: 962-970.
- Kang HY, Bahadoran P (2012) Application of in vivo reflectance confocal microscopy in melasma classification. *J Am Acad Dermatol* 67: 157.
- Hofmann-Wellenhof R, Pellacani G, Malvehy J, Soyer HP (2012) *Reflectance Confocal Microscopy for Skin Diseases*. Springer, Heidelberg, Dordrecht, London, New York.

This article was originally published in a special issue, **Melasma** handled by Editor(s). Dr. Serena Gianfaldoni, University of Pisa, Italy