

## Complications and Plate Removal Surgeries after Performing Volar Plating of Unstable Distal Radius Fractures

John H. Williksen<sup>1\*</sup>, Torstein Husby<sup>1</sup>, Hebe D. Kvernmo<sup>2</sup> and Frede Frihagen<sup>1</sup>

<sup>1</sup>Orthopedic Department, Oslo University Hospital, Oslo, Norway

<sup>2</sup>Orthopedic and Plastic Department, University of Northern Norway, Tromsø, Norway

### Abstract

**Purpose:** To determine the number of complications and plate removal surgeries after performing volar locking plate fixation of unstable distal radius fractures.

**Methods:** In 2008, there were 100 patients (101 unstable fractures of the distal radius) who were treated with volar locking plates at our hospital. Thirteen patients were lost to follow-up; thus, 87 patients with 88 fractures were reviewed (65 women and 22 men). The mean age was 51 years (range, 17-86 years). In 2010, all the patients were clinically and radiologically assessed. In 2014, the number of hardware removals and complications was retrospectively assessed based on patient records. There were 9 A2, 14 A3, 6 B1, 1 B2, 11 B3, 29 C1, and 18 C2 fractures, according to the AO/OTA classification. The complications, plate removal surgeries, and clinical and radiological outcomes were recorded. In 2010 the patients were clinically assessed using the visual analog scale (0–100 points) pain score at rest and at activity, Mayo Wrist Score (0–100 points), Quick-Disabilities of the Arm, Shoulder, and Hand (0–100 points), and range of motion. Plain radiographs of the wrist were also obtained.

**Results:** Twenty-nine patients had complications (33%), which led to worse clinical results during the follow-up in 2010. Until 2014, hardware removal had been performed in 17 (19%) patients, and this was beneficial in 62%. The main reasons for plate removal were extensor tendon synovitis and pain, and screw penetration into the radiocarpal joint.

**Conclusion:** The use of volar locking plates in unstable distal radius fractures is associated with several surgical-related complications, which has to be considered when using this method. Information about the complications may alter the patient outcomes more positively.

**Keywords:** Distal radius fractures; Volar locking plates; Complications; Secondary surgeries

### Introduction

Complications have often been reported in the literature after distal radius fractures treated conservatively or operatively [1-3]. Previously, the main indication for volar plating was a volar Barton or Smith fracture, but now volar locking plates are the most commonly used treatment for unstable distal radius fractures and during the last decade this method has become increasingly popular [4]. The plate design is anatomic and low profile, minimizing soft-tissue problems, and plating on the volar side of the radius makes it relatively easy to reduce the fracture while preventing extensor tendon irritation [5]. In the last years, there has been a shift in operative technique from pin fixation or external fixation to volar locking plates, because the clinical and radiological outcomes have been good. [6]. However, several authors have reported serious complications when using volar locking plate fixation in unstable distal radius fractures and although the results and severity of complications varies [7], the matter of complications will have to be addressed when implementing new methods. As with all new methods, the rate of complications seem to decrease with increasing surgeon experience [8].

The purpose of this study was to determine the number of complications and plate removal surgeries after volar plating had been performed in unstable distal radius fractures.

### Materials and Methods

In 2008, there were 100 patients (101 unstable fractures of the distal radius) who were treated with volar locking plates (VLP) at our institution. In 2010 thirteen patients were lost to follow-up. They were

contacted by mail and phone, but did not respond. Finally, 87 patients with 88 fractures (65 women and 22 men) were included in the study. There were 9 A2, 14 A3, 6 B1, 1 B2, 11 B3, 29 C1, and 18 C2 fractures, according to the Association for Osteosynthesis/Orthopaedic Trauma Association (AO/OTA) [9]. The complications, plate removal surgeries, and clinical and radiological outcomes were recorded.

In 2010, the patients were clinically assessed using the visual analog scale (VAS, 0–100 points) pain score at rest and at activity, Mayo Wrist Score (0–100 points, 100 best) [10-12]. Quick-Disabilities of the Arm, Shoulder, and Hand (DASH, 0–100 points, 0 best) and range of motion [13-15]. Plain radiographs in the anteroposterior and lateral views were obtained. Three different volar locking plates were used at the surgeon's discretion (Figure 1). The Acumed Acu-Loc<sup>®</sup> 46 plates (Acumed, Beaverton, Oregon, USA), LCP Distal Radius System<sup>®</sup> 30 plates (Oberdorf, Switzerland), and 12 DVR<sup>®</sup> (Biomet Inc., Warsaw, IN, USA). Volar plate prominence was radiologically classified according to the Soong et al. grading system [16], where the plate position is graded from 0 to 2. Grade 0 represents a plate position proximal to the

**\*Corresponding author:** John H. Williksen, Orthopedic Department, Oslo University Hospital, Storgt. 400182 Oslo, Norway, Tel: +4792285918; E-mail: john.williksen@me.com

Received July 04, 2015; Accepted July 16, 2015; Published July 22, 2015

**Citation:** Williksen JH, Husby T, Kvernmo HD, Frihagen F (2015) Complications and Plate Removal Surgeries after Performing Volar Plating of Unstable Distal Radius Fractures. J Trauma Treat S2: 013. doi:10.4172/2167-1222.S2-013

**Copyright:** © 2015 Williksen JH, et al. This is an open-access article distributed under the terms of the Creative Commons Attribution License, which permits unrestricted use, distribution, and reproduction in any medium, provided the original author and source are credited.

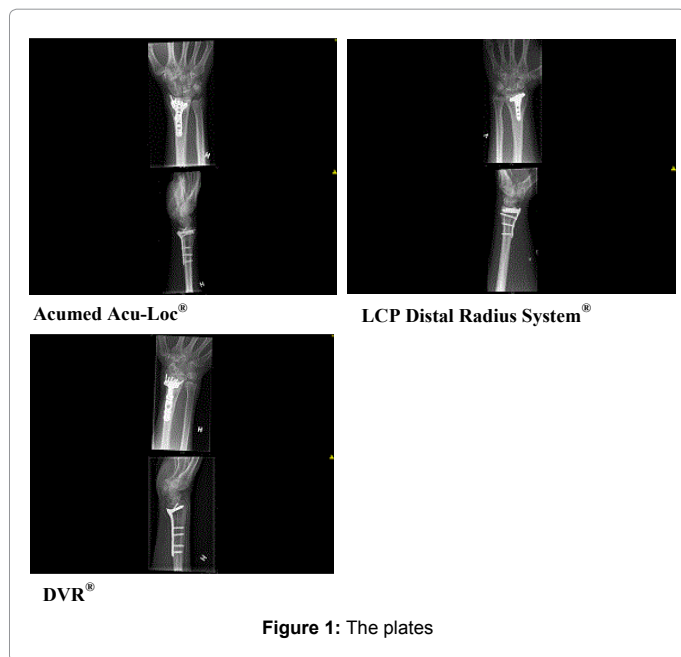


Figure 1: The plates

Complication	N	%	Plate Removals
Carpal tunnel syndrome	7	8	1
CRPS	2	2	1
Screw penetr. RC-joint	2	2	1
Loss of Reduction	1	1	-
Prominent volar screw heads	1	1	1
Screw penetr. dorsal cortex	6	7	6
Superficial wound inf.	1	1	-
Hematoma	1	1	-
Ext. tend synovitis	3	3	2
Radial plate position	1	1	1
EPL-rupture	1	1	1
Volar pain	1	1	1
Pain	2	2	-
Total	29	33	15

Table 1: RC-joint, radio carpal joint, EPL, extensor pollicis longus.

Measure	Group	N	Mean	Mean Difference (95% CI)	P Value
VAS at rest	NC	58	1	-6 (-12 to 0)	0.06
	C	29	6		
VAS activity	NC	58	4	-14 (-23 to -6)	0.001
	C	29	18		
Quick-DASH	NC	58	4	-9 (-15 to -4)	0.002
	C	29	14		
Mayo wrist score	NC	58	93	8 (3 to 13)	0.003
	C	29	84		
Flexion	NC	58	57°	5 (-1 to 10)	0.01
	C	29	52°		
Extension	NC	58	64°	10 (4 to 17)	0.002
	C	29	53°		
Gripstrength FX	NC	58	34 kg	8 (3 to 13)	0.001
	C	29	26 kg		

Table 2: NC, no complications, C, complications, FX, fractured wrist.

volar rim, grade 2 directly at the volar rim and grade 1 between these positions.

All the operations were performed by four qualified hand surgeons. Three of them with more than 15 years of hand surgical experience and one with 5 years. To assess the complications and plate removal surgeries after six years all the patients journals were consulted in 2014 and the reasons for plate removal surgery were recorded.

### Surgical technique

The operations were performed under general anesthesia, or a regional axillary/brachial block and a tourniquet was used. In addition, prophylactic antibiotics (Cephalothin 2 g) were administered pre- and post-operatively in two doses. The Henry approach with retraction of the pronator quadratus and release of the brachioradialis was performed. Temporary pin fixation after reduction of the fracture was performed at the surgeon's discretion, and the fracture was secured with a volar locking plate. Postoperatively, the wrist was placed in a dorsal forearm cast for 2 weeks.

### Ethics

This study design was approved by our institutional review board.

For this retrospective study, approval from the Regional Ethics Committee was not required.

### Statistics

The mean values and confidence intervals were calculated using the independent sample t-test for continuous variables, and the chi-square test for dichotomous variables.

### Results

The mean age of the patients was 51 years (range, 17–86 years, standard deviation [SD] 15,4). The mean time to clinical follow-up in 2010 was 17 months (range, 2–26 months, SD 4,5). High-energy injuries accounted for 30%, with 70% being low-energy injuries. The non-dominant wrist was fractured in 47 patients (54%). There were 29 patients with complications (33%) (Table 1).

### Clinical results at 17 months

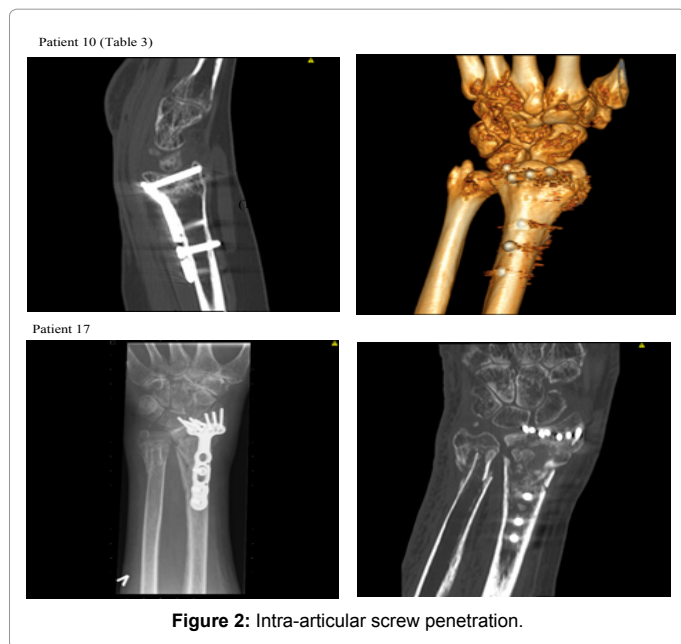
The mean VAS at rest was 3 (range, 0–71, SD 9,5), and the mean VAS at activity was 8 (range, 0–71, SD 15,2). The mean Mayo Wrist score was 90 (range, 50–100, SD 10,3). The mean DASH was 7 (range, 0–55, SD10,6). The following results were for the patients' mean range of motion: extension, 60° (range, 20–82, SD 13,0); flexion, 56° (range, 30–80, SD 11,5); radial deviation, 25° (range, 5–56, SD 9,1); ulnar deviation, 38° (range, 10–72, SD 10,2); pronation, 87° (range, 70–90, SD 3,6); and supination, 88°(20–90, SD 8,3).

Pain as a complication was recorded in 2 patients. Of those, one patient had mild carpal tunnel syndrome (CTS) and a dorsal angulation of 17° of the lateral view, and the other patient experienced pain during activity but had normal radiographs. The clinical outcomes after 17 months were worse in patients with complications (Table 2).

### Radiological results at 17 months

The mean radial inclination was 23° (range, 12–33, SD 4,3). In the lateral view, there was a mean volar tilt of 2° (range, 17° dorsal to 18° volar, SD 7,0).

According to the Soong classification there were 14 grade 0, 42 grade 1, and 29 grade 2. Three plates were not classified. The Acumed



removed in one patient due to complex regional pain syndrome (CRPS), in another due to carpal tunnel syndrome (CTS). In two patients the plates were removed due to screw penetration of the dorsal cortex leading to synovitis and pain, in another patient the plate was in a too radial position leading to pain and in one patient there was intra-articular screw penetration (Figure 2). In one patient the plate was removed due to other hardware removal (misc). In one patient the plate was left in position and only the two screws penetrating the radiocarpal joint was removed. Based on the patients' records in 2014, 9 additional plates were removed (Table 3).

The Acumed Acu-Loc<sup>®</sup> plate system resulted in hardware removal in 20%, and in the LCP Distal Radius System<sup>®</sup> and the DVR<sup>®</sup>, we recorded a hardware removal in 17%. Generally, the plate removal was uneventful; however, in 1 patient, one of the screw heads had fractured (Figure 3), making it difficult to remove the screw. In another patient, one of the screws was cross-locked, and in one patient there was a lack of correct instruments for removing the screws, which made the removal a challenging task. There was no difference in complication rate related to surgical experience.

### Discussion

Volar locking plate fixation for unstable distal radius fractures has become a popular method. The clinical and radiological outcomes are good [17,18] which our functional outcomes in 2010 confirmed, but our study also demonstrated that the complications after VLP fixation led to worse clinical outcomes (Table 2). Serious complications have previously been reported with VLPs in the treatment of distal radius fractures [19-22] This includes tendon tenosynovitis, rupture of the extensor and flexor tendons, and intra-articular screw penetrations. Arora et al. [23] compared non-operative treatment with VLP fixation in patients over the age of 65 and reported a 36% complication rate in the operated group and a high number of reoperations, which were mostly implant removals. In a recent systematic review by Bentohami et al. [7] they reported an overall complication rate of 16.5% of which 7.7% were classified as major complications. However, CRPS and loss of

Patient-Gender-Age	AO/ASIF	Plate	Comp.	Time to plate removal (months)	Improvement after plate removal	Problems during plate removal
1-Female-42	C2	AcuLok	SPD-Pain	27	NR	No
2-Female-31	C1	AcuLok	SPD-Pain	32	Y	No
3-Female-46	A2	Synthes	Volar Pain	32	N	No
4-Female-50	C1	DVR	PVS	24	NR	No
5-Female-28	C1	AcuLok	Misc.	7	NR	No
6-Female-44	C2	Synthes	SPD-Pain	5	Y	No
7-Female-64	A2	Synthes	Rupture EPL	39	Y	No
8-Female-58	C1	Synthes	CRPS	9	N	Yes
9-Female-50	C1	AcuLok	Radial plate pos.	21	Y	No
10-Female-50	C2	AcuLok	Intra. art. screws	9	Y	No
11-Female-21	C1	AcuLok	SPD-Synovitis	19	Y	No
12-Male-40	B3	AcuLok	SPD-Synovitis	27	Y	Yes
13-Female-36	C1	AcuLok	SPD-Pain	27	Y	No
14-Female-58	C1	AcuLok	CTS	12	NR	No
15-Male-55	A2	Synthes	SPD-Pain	72	Y	No
16-Female-31	B1	AcuLok	SPD-Pain	49	Y	Yes
17-Female-68	C1	DVR	Intra. art. screws	2 (screws rem.)	Y	No

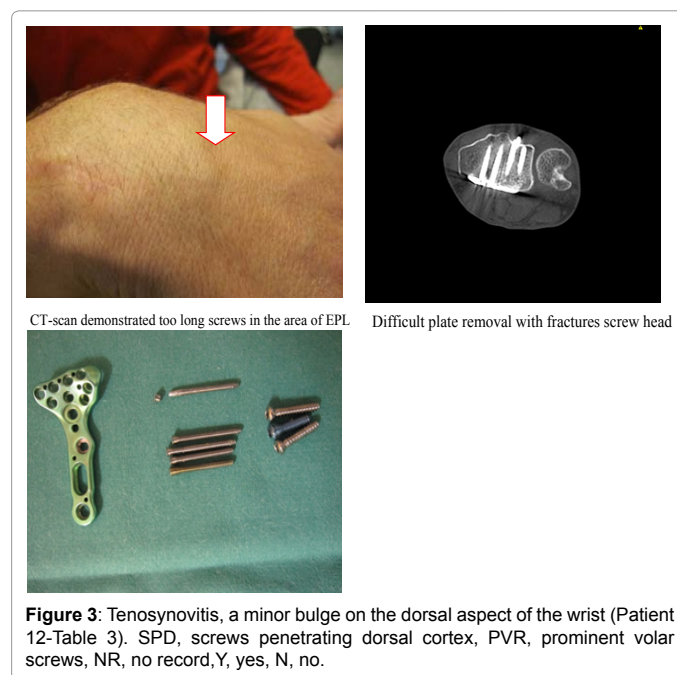
SPD, screws penetrating dorsal cortex, PVS, prominent volar screws, NR, no record, Y, yes, N, no, Misc, miscellaneous.

**Table 3:** Complications and plate removal surgeries (2014).

Acu-Loc<sup>®</sup> plate system resulted in 56% grade 1 and 20% grade 2, in the LCP Distal Radius System<sup>®</sup> 37% grade 1 and 53% grade 2, and in the DVR<sup>®</sup> we recorded 30% grade 1 and 25% grade 2. There were no flexor tendon injuries in this study.

### Plate removal surgeries

By February 2010, 7 plates had been removed. These plates were



reduction, was in their study classified as minor complications, which can be argued. Grewal et al. [24] reported tendon ruptures using the VLPs at a 12 months follow-up. Our study demonstrate that tendon problems might be an issue also beyond 12 months (Table 3), leading to plate removal surgery.

Several studies have described the extensor and flexor tendon ruptures after volar locking plate fixation [25-28]. In our study, there was only one extensor tendon rupture (extensor pollicis longus, EPL) due to screw penetration of the dorsal cortex. Several of our patients had however screw penetration of the dorsal aspect of the radius that led to pain and tenosynovitis. We believe that tenosynovitis due to screw penetrations may lead to tendon rupture, necessitating a prompt implant removal. The close proximity of the extensor tendons to the dorsal cortex, fragmentation of the fracture, and difficulty in correctly measuring the screw length in this area explain the tendon problems that occur when screws penetrate the dorsal cortex. The importance of placing the plate in the correct position in relation to the watershed line in order to avoid flexor tendon problems has been demonstrated by Soong et al. [16] and Kitay et al. [26]. Although 71 of the patients had a grade 1 or 2 plate prominence according to the classification by Soong et al. [16], there were no flexor tendon ruptures after 6 years. There were more plates with a volar rim prominence in the the Acumed Acu-Loc<sup>®</sup> plate system and the LCP Distal Radius System<sup>®</sup> than in the DVR<sup>®</sup>, but the numbers are small and have to be interpreted with caution. One patient had pain in the volar aspect of the wrist, but the pain did not resolve when the plate was removed (Patient 4, Table 3).

Carpal tunnel syndrome may occur after distal radius fractures. Hove [2] reported an incidence rate of 5.5% in conservatively treated fractures. Arora et al. [19] reported that only three patients were diagnosed with CTS, and their patients were treated with carpal tunnel release (CTR) and implant removal. Lattmann et al. [28] reported that nine patients had symptoms of CTS; conversely, Johnson et al. [27] reported that only 0.5% of patients had CTS. In our study, 7 (8%) patients had CTS confirmed by a neurophysiologic examination. Five patients underwent surgical release, but only one underwent plate removal. All the patients recovered well. We do not believe it is necessary to remove the plate in postoperative CTS if the fracture is well reduced and the plate is well seated on the bone. Only one patient had symptoms of CTS during the first 2 weeks after the VLP operation, and CTR was performed with an immediate effect. Based on the general low incidence of this complication, we do not routinely decompress the median nerve during the VLP operation in low-energy injuries. However, we know that CTS is a common disorder with a prevalence of 3-5% [29], which may become symptomatic after injury and operation. The complex regional pain syndrome is a serious complication after distal radius fractures. In our study, this complication rate was in accordance with previous studies [19,21,27,28]; however, it was slightly higher than in conservatively treated patients [2,30].

The complication of screw penetration of the radiocarpal and distal radioulnar joint has been reported previously [19,27] but to a lesser extent than tendon problems. In our two cases of radiocarpal joint penetration, the diagnosis was made postoperatively, because the patients had pain and restricted wrist motion. These problems were resolved when the plate and/or screws were removed. The diagnosis may be difficult to make intraoperatively, but good reduction and placement of the plate, and a lateral elevated fluoroscopic view is important [31]. The rate of infection in the present study was low (1%), which is in accordance with a previous study [21]. The number of hardware removals was high (19%), while other authors have reported a lower incidence [17].

However, the follow-up in this study was longer. Navarro et al. [32] included 36,618 patients and reported a higher number of reoperations after plate fixation than after pin or external fixation. Aigner et al. [33] reported an implant removal rate after palmar plating of 8.2% in their analysis of 721 patients. Hardware removal is necessary in pin and external fixation, but it is not considered a complication. However, in plate fixation, hardware removal is considered a complication, because one would not recommend hardware removal in asymptomatic patients. Ten of 16 patients (62%) in our study reported less pain after VLP removal.

The limitations of this study were that it was mainly retrospective and that the number of patients was low compared to other studies. Another limitation was that in 2014, our conclusions were mainly based on the patients' records and not on clinical examination; however, in our country, there is mainly a public health system where the patients are allocated to only certain hospitals and few change hospital systems. There is also a bias, because three different implants were used at the surgeon's discretion. This may indicate less familiarity with the implants, leading to more complications.

## Conclusion

In the last 10-15 years after the introduction of VLPs, it has been demonstrated that this method has surgical-related complications; in particular, tendon irritation and intra-articular screw penetration, which inevitably cause worse clinical outcomes and secondary surgeries. This should be taken into consideration when choosing this method for more simple fractures that can be operated on using quicker and more inexpensive methods that reduce the need for reoperations. The burdens to the patient include the secondary operation and the cost of the reoperations, which are important aspects to consider. When evaluating the benefits to patients when shifting from more simple methods to more complicated methods, the benefits must outweigh the possible complications. In the early period of volar plating, many surgeons were not aware of the pitfalls of volar plate fixation, and we believe that this method is not very forgiving in suboptimal surgical techniques. Thus, we expect that the information presented herein concerning the complications will positively alter the patients' outcomes.

## References

1. Cooney WP 3rd, Dobyns JH, Linscheid RL (1980) Complications of Colles' fractures. *J Bone Joint Surg Am* 62: 613-619.
2. Hove LM (1995) Nerve entrapment and reflex sympathetic dystrophy after fractures of the distal radius. *Scand J Plast Reconstr Surg Hand Surg* 29: 53-58.
3. Margaliot Z, Haase SC, Kotsis SV, Kim HM, Chung KC (2005) A meta-analysis of outcomes of external fixation versus plate osteosynthesis for unstable distal radius fractures. *J Hand Surg Am* 30: 1185-1199.
4. Downing ND, Karantana A (2008) A revolution in the management of fractures of the distal radius? *J Bone Joint Surg Br* 90: 1271-1275.
5. Orbay JL, Fernandez DL (2002) Volar fixation for dorsally displaced fractures of the distal radius: a preliminary report. *J Hand Surg Am* 27: 205-215.
6. Williksen JH, Frihagen F, Hellund JC, Kvernmo HD, Husby T, et al. (2015) External fixation and adjuvant pins versus volar locking plate fixation in unstable distal radius fractures: a randomized, controlled study with a five-year follow-up. *J Hand Surg Am* 40: 1333-1340.
7. Bentohami A, de Burtet K, de Korte N, van den Bekerom MP, Goslings JC, et al. (2014) Complications following volar locking plate fixation for distal radial fractures: a systematic review. *J Hand Surg Eur Vol* 39: 745-754.
8. Ward CM, Kuhl TL, Adams BD (2011) Early complications of volar plating of distal radius fractures and their relationship to surgeon experience. *Hand (N Y)* 6: 185-189.
9. Marsh JL, Slongo TF, Agel J, Broderick JS, Creevey W, et al. (2007) Fracture



- and dislocation classification compendium-2007: Orthopaedic Trauma Association classification, database and outcomes committee. *J Orthop Trauma* 21: S1-133.
10. Amadio PC, Berquist TH, Smith DK, Ilstrup DM, Cooney WP 3rd, et al. (1989) Scaphoid malunion. *J Hand Surg Am* 14: 679-687.
  11. Green DP, O'Brien ET (1978) Open reduction of carpal dislocations: indications and operative techniques. *J Hand Surg Am* 3: 250-265.
  12. Cooney WP, Bussey R, Dobyns JH, Linscheid RL (1987) Difficult wrist fractures. Perilunate fracture-dislocations of the wrist. *Clin Orthop Relat Res*: 136-147.
  13. Hunsaker FG, Cioffi DA, Amadio PC, Wright JG, Caughlin B (2002) The American academy of orthopaedic surgeons outcomes instruments: normative values from the general population. *J Bone Joint Surg Am* 84-84A: 208-15.
  14. Beaton DE, Wright JG, Katz JN; Upper Extremity Collaborative Group (2005) Development of the QuickDASH: comparison of three item-reduction approaches. *J Bone Joint Surg Am* 87: 1038-1046.
  15. Finsen V (2008) [Norwegian version of the DASH questionnaire for examination of the arm shoulders and hand]. *Tidsskr Nor Laegeforen* 128: 1070.
  16. Soong M, Earp BE, Bishop G, Leung A, Blazar P (2011) Volar locking plate implant prominence and flexor tendon rupture. *J Bone Joint Surg Am* 93: 328-335.
  17. Rozental TD, Blazar PE (2006) Functional outcome and complications after volar plating for dorsally displaced, unstable fractures of the distal radius. *J Hand Surg Am* 31: 359-365.
  18. Williksen JH, Frihagen F, Hellund JC, Kvernmo HD, Husby T (2013) Volar locking plates versus external fixation and adjuvant pin fixation in unstable distal radius fractures: a randomized, controlled study. *J Hand Surg Am* 38: 1469-1476.
  19. Arora R, Lutz M, Hennerbichler A, Krappinger D, Espen D, et al. (2007) Complications following internal fixation of unstable distal radius fracture with a palmar locking-plate. *J Orthop Trauma* 21: 316-322.
  20. Berglund LM, Messer TM (2009) Complications of volar plate fixation for managing distal radius fractures. *J Am Acad Orthop Surg* 17: 369-377.
  21. Esenwein P, Sonderegger J, Gruenert J, Ellenrieder B, Tawfik J, et al. (2013) Complications following palmar plate fixation of distal radius fractures: a review of 665 cases. *Arch Orthop Trauma Surg* 133: 1155-1162.
  22. Tarallo L, Mugnai R, Zambianchi F, Adani R, Catani F (2013) Volar plate fixation for the treatment of distal radius fractures: analysis of adverse events. *J Orthop Trauma* 27: 740-745.
  23. Arora R, Lutz M, Deml C, Krappinger D, Haug L, et al. (2011) A prospective randomized trial comparing nonoperative treatment with volar locking plate fixation for displaced and unstable distal radial fractures in patients sixty-five years of age and older. *J Bone Joint Surg Am* 93: 2146-2153.
  24. Grewal R, MacDermid JC, King GJ, Faber KJ (2011) Open reduction internal fixation versus percutaneous pinning with external fixation of distal radius fractures: a prospective, randomized clinical trial. *J Hand Surg Am* 36: 1899-1906.
  25. White BD, Nydick JA, Karsky D, Williams BD, Hess AV, et al. (2012) Incidence and clinical outcomes of tendon ruptures following distal radius fractures. *J Hand Surg Am* 37: 2035-2040.
  26. Kitay A, Swanstrom M, Schreiber JJ, Carlson MG, Nguyen JT, et al. (2013) Volar plate position and flexor tendon rupture following distal radius fracture fixation. *J Hand Surg Am* 38: 1091-1096.
  27. Johnson NA, Cutler L, Dias JJ, Ullah AS, Wildin CJ, et al. (2014) Complications after volar locking plate fixation of distal radius fractures. *Injury* 45: 528-533.
  28. Lattmann T, Meier C, Dietrich M, Forberger J, Platz A (2011) Results of volar locking plate osteosynthesis for distal radial fractures. *J Trauma* 70: 1510-1518.
  29. Atroshi I, Gummesson C, Johnsson R, Ornstein E, Ranstam J, et al. (1999) Prevalence of carpal tunnel syndrome in a general population. *JAMA* 282: 153-158.
  30. Dijkstra PU, Groothoff JW, ten Duis HJ, Geertzen JH (2003) Incidence of complex regional pain syndrome type I after fractures of the distal radius. *Eur J Pain* 7: 457-462.
  31. Soong M, Got C, Katarincic J, Akelman E (2008) Fluoroscopic evaluation of intra-articular screw placement during locked volar plating of the distal radius: a cadaveric study. *J Hand Surg Am* 33: 1720-1723.
  32. Navarro CM, Pettersson HJ, Enocson A (2015) Complications after distal radius fracture surgery: results from a Swedish nationwide registry study. *J Orthop Trauma* 29: e36-42.
  33. Aigner R, Debus F, Karaman Y, López-López C, Ruchholtz S, et al. (2014) [Outcomes after operative treatment of distal radius fractures - an analysis of 721 patients]. *Z Orthop Unfall* 152: 375-380.