

Comparison of Dual Level Fusion and Hybrid Treatment in the Cervical Spine Based on Patient Outcome

Mende KC^{1*}, Kahl N², Detzner M³, Lefering R⁴, Franke J⁵ and Weber F³

¹HDepartment of Neurosurgery, University Medical Center Hamburg Eppendorf, Hamburg, Germany

²University of Essen, Essen, Germany

³Department of Neurosurgery, Hospital Cologne Merheim, Cologne, Germany

⁴IFOM, Cologne, Germany

⁵Department of Spinal Surgery, Klinikum Dortmund, Dortmund, Germany

Abstract

Objective: Very few studies researched the treatment modalities in treating degenerative disc disease for two adjacent levels of the cervical spine. In order to reduce distress on the adjacent segments and minimize implant subsidence we analyzed the use of a hybrid approach combining arthroplasty with cage fusion.

Methods: 64 “fusion-only” and 47 hybrid patients between the age of 30 and 60 years were clinically evaluated using ODI, Odon’s criteria. X-rays in two planes of the cervical spine were taken, measuring alpha and C2-C7 beta angles using Harrison’s tangent. Signs of subsidence in the sagittal plane were recorded, where subsidence was defined as a shift by more than 40% of the respective implant height.

Results: 10 cages combined with arthroplasty and 2 prostheses showed signs of subsidence compared to 47 cages in the fusion group (25 single level and 11 on two levels). Overall subsidence after two years was found in 49% of the fusion group opposing 18% in our arthroplasty group. Patients with subsidence showed a longer recovery time to work, 14 weeks vs. 26, $p=0.21$; compared to the fusion group, 13/22 weeks, $p=0.34$. Odon’s criteria and Oswestry results were favorable and comparable in both groups. Revision rates were higher for arthroplasty 10.6% vs. 3.1%.

Conclusion: We found two level ACDF implants to subside more frequently than in ACDF in combination with arthroplasty, indicating a reduced distress in the arthroplasty group. Absence of subsidence may have led to a faster return to work as may the implementation of arthroplasty. Overall the clinical outcome of both groups was comparable. However with the hybrid approach a higher revision rate occurred.

Keywords: ACDF; Outcome; Hybrid; Dual level; Lower cervical spine; Subsidence

Abbreviations: ACDF: Anterior Cervical Discectomy and Fusion; ASD: Adjacent Segment Disease; HT: Hybrid Treatment: One Level with ACDF and One Level with TDR; PEEK: Poly-Ether-Ether-Ketone; TDR: Total Disc Replacement; VAS: Visual Analog Scale

Introduction

Anterior cervical decompression and fusion is the gold standard in the operative treatment of degenerative disc disease in the cervical spine for many years [1,2]. Many different alterations to the original techniques have been proposed and numerous types of implants and materials were tested. However, the question of whether fusion is really necessary has not yet been answered [3,4]. Adjacent segment disease due to heightened distress above or below fused levels has often been discussed as a disadvantage of ACDF, by substituting one of the two rigid cages with a more flexible prosthesis we hoped to diminish the deterioration of the adjacent segments.

Therapy options

ACDF has been the gold standard for more than half a century [4]. One of the main disadvantages of ACDF is the often discussed Adjacent Segment Degeneration (ASD) [5].

The other option for DDD in the lower cervical spine is arthroplasty maintaining a part of the original range of motion and segment height thus potentially reducing subsidence through stress shielding of the segment and possibly preventing adjacent segment disease [6].

For the hybrid approach a combination of fusion and total disc replacement was chosen under the impression of reducing the stress on adjacent segments as indicated by Lee et al. [7]. A two level arthroplasty approach was thought to have a possible negative effect on spinal

biomechanics, and subsequently patient outcome, through an artificial hypermobility with increased stress on the adjoining segments (Figure 1).

Materials and Methods

The study was performed at a neurosurgical department including 387 patients that had received an anterior cervical disc replacement surgery between July 1999 and December 2010 (Figures 1 and 2) on two adjacent levels of the cervical spine. 319 received double level ACDF and 68 hybrid procedures (one fusion combined with one arthroplasty). The main diagnosis was a degenerative disc disease.

Using this collective we were able to reach and include 172 (55 arthroplasty and 117 ACDF) patients for the required follow up. To achieve better comparability we set the minimal patient age to 30 years and the maximum to 60 years reducing the sample size to 111 patients (47 arthroplasty, 64 fusion).

Inclusion criteria

Patients with present two level cervical degenerative disc disease and radiculopathy or signs of myelopathy and either failed conservative

***Corresponding author:** Mende KC, Winzeldorfer Weg 17, 20251, Hamburg, Germany, Tel: +417680000492; E-mail: C.Mende@uke.de

Received January 21, 2015; **Accepted** March 13, 2015; **Published** March 15, 2015

Citation: Mende KC, Kahl N, Detzner M, Lefering R, Franke J, et al. (2015) Comparison of Dual Level Fusion and Hybrid Treatment in the Cervical Spine Based on Patient Outcome. J Spine 4: 218. doi:10.4172/21657939.1000218

Copyright: © 2015 Mende KC, et al. This is an open-access article distributed under the terms of the Creative Commons Attribution License, which permits unrestricted use, distribution, and reproduction in any medium, provided the original author and source are credited.

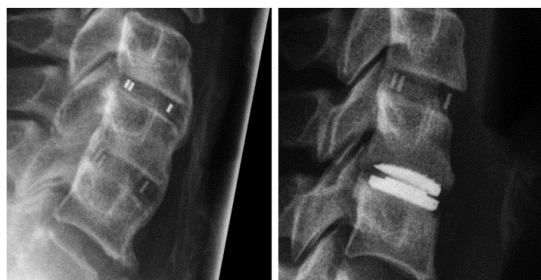

Figure 1: Left: Dual Level fusion, right: Hybrid approach.

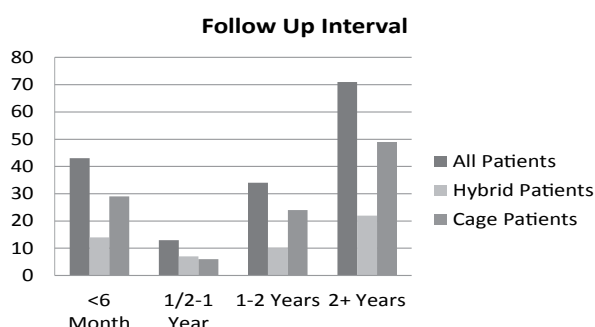


Figure 2: Follow-up time after surgery for patients included after matching.

therapy or presentation of paresis were included if they had not been diagnosed with osteopenia or osteoporosis. The choice of implant and combination lay solely with the surgeon who performed the procedure. There was no specification as to whether the prosthesis in a hybrid setting was the superiorly or inferiorly located implant.

Surgical procedure

A modified anterior Smith-Robinson approach to the cervical spine using a rectangular allograft spacer was performed for all patients. The choice of positioning of the prosthesis (superior or inferior implant) in a hybrid setting lay with the responsible surgeon and was not predetermined.

Assessment of the clinical outcome using the ODI

For all patients besides the clinical and neurological examination the ODI [8] was taken once on average 25.5 month after index surgery (24.3 arthroplasty, 28.1 ACDF).

The clinical examination included search for motor weakness, sensitivity changes, motion range and reflexes. The patient was questioned regarding continence. His lower extremity reflexes, motor strength and overall balance were assessed. Any clinical signs of myelopathy, as well as radiographic signs were recorded, if present. Additionally, a subjective quality of life assessment was performed using a numeric scale ranging from one to five points (1=very good, 2=good, 3=acceptable, 4=unsatisfactory, 5=poor) to be rated by the patients themselves.

Furthermore the patients' co-morbidities, work status, pain medication, myelopathy and complications related to surgery were recorded.

Radiological documentation

For all patients X-Ray images in two planes were taken in order to evaluate the position of the implant and the fusion of the two index

segments. Fusion status (Figure 3) could either be pseudarthrosis at less than 6 month after surgery, at more than 6 month after surgery, heterotopic ossification in 2D roentgenograms, fusion seen by conventional radiographic imaging in 2 planes, or fusion acknowledged through a computer tomographic scan of the cervical spine.

Subsidence was measured in lateral x-ray images and defined as a shift into the adjacent endplates >40% of the implant's respective height. If the subsidence was not balanced in the sagittal plane (angle >5°) the tipping direction was recorded.

Harrison's posterior tangent for the alpha angles of the index segments and for the beta angles of the cervical spine from segment C2-C7 was also measured (Figure 4). A kyphotic alignment (angle <30°) was deemed pathological in correspondence to the findings of McAvinney et al. [9].

Statistical analysis

The collected data were imported to IBM® SPSS® 19. The patients were grouped into the cage and the hybrid group. The groups were matched for age and gender reducing the group size to 64 ACDF and 47 hybrid patients. We used cross tables applying a Chi²-Test, a T-Test to identify significant impacts on patient outcome and to find significant inter-variable influences.

Results

We included 111 patients with DDD in our study, 64 male and 47 female. The mean patient age in the HT group was 48.7 years and in the

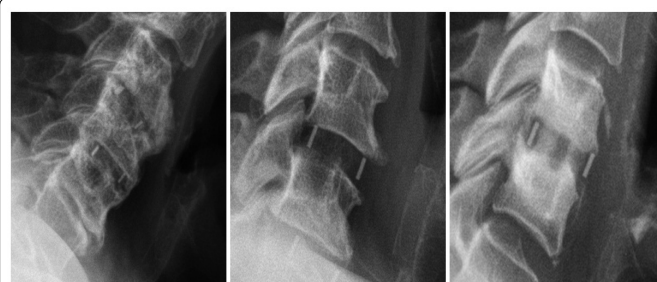

Figure 3: Left: Heterotopic ossification Middle: Pseudarthrosis Right: Solid Fusion.

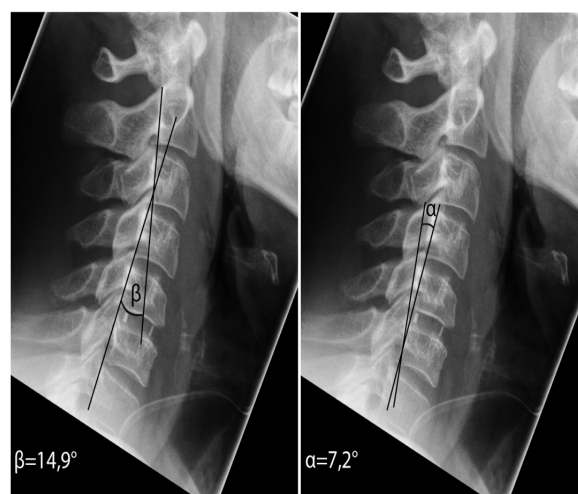


Figure 4: Left: Beta angle for the whole cervical spine (C2-C7) Right: Alpha angle for the specific segment.

ACDF group 52.0 years. There were 43 males and 22 females for ACDF, 21 males and 25 females for HT.

In order to achieve a higher state of comparability we adjusted the mean patient age in both groups for statistical testing (Table 1). The mean Oswestry results were better for HT mean 21.6 than for ACDF mean 28.6 (t-test), this effect could not be found in the VAS rankings. Here, the mean scoring for neck pain was lower in the dual level fusion group mean 2.85 opposing the HT group mean 3.33. The same phenomenon could not be found for pain in the arm (Fusion: mean: 2.30; Hybrid: mean 2.42).

Hybrid Treatment showed better Oswestry scores for patients between 40-50 years of age and for the age group of 50-60 years an outcome comparable to cage therapy (Figure 5).

Overall success was defined as excellent with a post-op Oswestry score below 20% and good success as a score between 20 and 40% resembling mild conservatively treatable impairment. HT had a slightly higher percentage of patients with excellent outcomes, (Cage: 41.5%/HT: 47.8%) but both treatments produced the same number of unsuccessful recoveries (Figure 6).

Radiographic imaging showed that cages implanted in HT had a significantly lower probability to fracture into the underlying vertebrae ($p=0.001$). Only 9 ($n=47$) HT cages sintered compared to 20 patients on one level and 11 patients on both levels ($n=64$) for dual level ACDF, but 2 prostheses ($n=47$) sintered as well (Figure 7). The prostheses sintered once on a male patient and once on a female (Table 2). In patients with surgery more than two years prior to assessment 49% of the cages had sintered in double fusion and only 18% in the arthroplasty plus fusion group ($p=0.01$). Oswestry scores for fusion patients were better if the segment showed signs of solid fusion (31 vs. 24 points, $p=0.2$) and for sintered implants (31 vs. 26 points, $p=0.3$) the effect could not be observed for hybrid treatment.

Alpha angles measured over sintered segments tended to be significantly lower than in segments with stable implant positioning ($9^\circ/5^\circ$, $p=0.02$). The corresponding beta angles were equal for both situations.

The average time of hospitalization was mean: 8.0 days for ACDF (Mean: 5.3 days after Surgery) and mean: 7.5 days for HT (Mean: 4.8 days after surgery). Mean patient satisfaction measured on a scale from one to five (one being best) averaged at 2.0 in the fusion group and 1.9 in the hybrid group.

The return to work was achieved earlier for arthroplasty plus fusion, patients returned on average at 13 weeks post-surgery whereas fusion patients resumed work at 22 ($p=0.34$). The absence of subsidence also led to a faster return to work (14 vs. 26 weeks, $p=0.21$)

Complications

A revision operation was necessary in 2 patients (3.1%, $n=64$) for the ACDF group (1 for implant failure and 2 for hematoma) in the HT group 5 (10.6%, $n=47$, $p=0.11$) operative revisions were performed. Two prostheses sintered into the lower vertebrae.

Discussion

Generally ACDF on one segment is thought to accelerate the progress of adjacent segment disease (ASD) therefore a positive influence on the pathology by arthroplasty on one level has often been discussed [7,10,11]. Robertson et al. [10] found a strong occurrence of radiographically visible changes in terms of ASD within 24 month after

fusion, 33% of their fusion patients required treatment for ASD whereas only 1.3% of the Bryan disc patients required further therapy. As far as we know performing a solid fusion on two levels may induce even more distress at the adjacent segments [7]. Some studies performed on the subject, show an equally strong occurrence of ASD for both, the ACDF and HT [12,13], promoting a search for other impacts on spinal degeneration in ASD e.g. osteopenia and lumbar degenerative disc disease [13]. Other authors, however, conclude that the increased range of motion (ROM) in the levels adjacent to a fused segment increases the development of ASD [14]. Supporting the argument for arthroplasty, are the trials that show better NDI recovery rates in patients with HT (McAfee et al. [3]). Robertson et al. [10] found neck, shoulder and arm pain to show better results for arthroplasty as in Mummaneni et al. [15], where the trial also showed improved neurological results for total disc replacement at 12 and 24 month post op. They also recorded a less frequent use of strong narcotics in the HT group; this effect was not observed in our study. Both groups had an equal necessity for oral pain medication. Mummaneni's findings were confirmed by a study published by Heller et al. [16], who also found TDR to show better overall success than ACDF at both 12 and

Comparison		
	Hybrid	Fusion
Cases	47	64
Mean patient age	48,7 yr/6,0*	52,0 yr/6,0*
Female patients	55,3%	32,8%
Mean oswestry	21,6%	28,6%
Mean VAS neck	3,33	2,85
Mean VAS arm	2,42	2,30
Subsided cages	9	20/11**
Subsided prostheses	2	
Operative revisions	5	2
Hospitalization	7,5	8,0
Patient satisfaction	1,9/5***	2,0 /5***

***Mean Patient satisfaction out of 5, 1 being the best score
**Single level / Both levels; *Standard deviation

Table 1: Overall results.

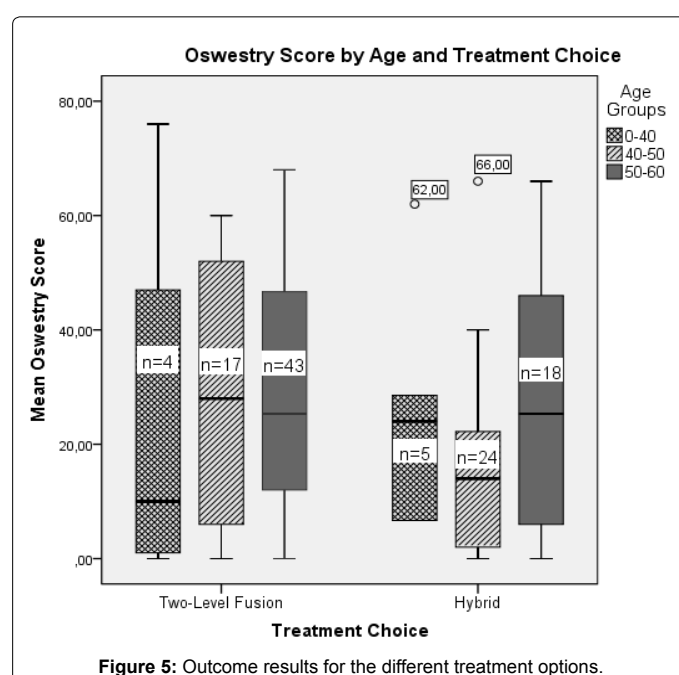
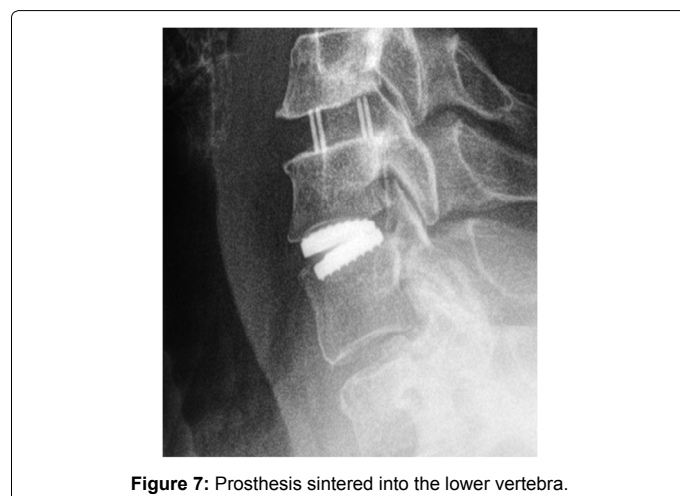
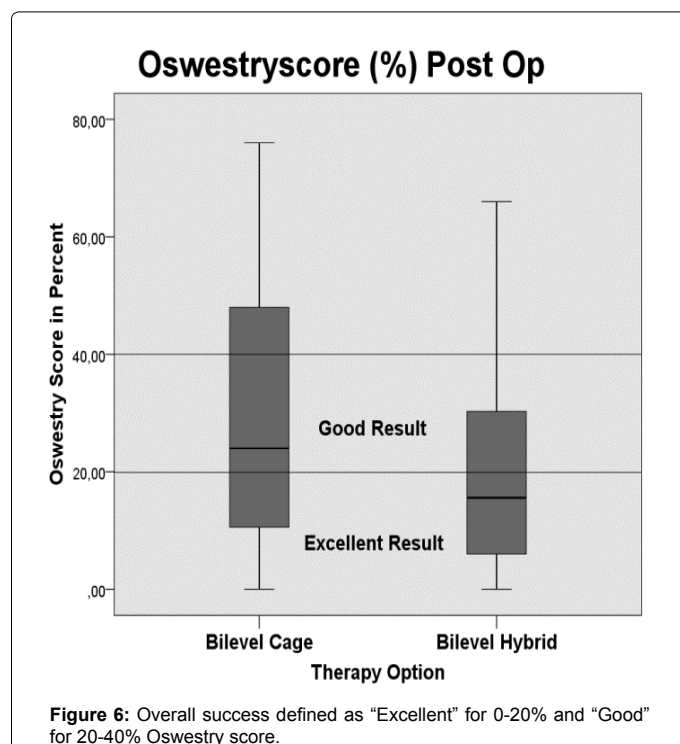


Figure 5: Outcome results for the different treatment options.



24 month post op. In our study we found no difference for the patient outcome regarding the choice of treatment but were able to observe a strong occurrence of spacer subsidence in the fusion-only group (49% after 2 years) as an indirect sign of heightened distress on the fused level. The levels combined with arthroplasty presented only 18% subsidence, thus presenting a possible reduction of distress which may help prevent further degeneration of the adjacent spinal segments. The reduced distress may be caused by the fact that prostheses allow a faster return to an almost physiological range of motion as proposed by Kang et al. [17], reducing hypermobility and pressure on the adjacent spinal segments [7,14]. Due to the nature of our study this effect could not be investigated. Within our HT group 14 prostheses were implanted in an inferior position to the cage, 26 were implanted superiorly. Sintering occurred almost equally for both groups (inferior 35.5%, superior 30.8%) confirming the results of Lee et al. [7] who found a prosthesis implanted adjacent to a fused segment would restore the original range of motion (in relation to a healthy segment) in a cadaveric model.

The slightly better outcomes for arthroplasty as stated by McAfee [3] and Mummaneni [15] were only hinted at in our study but not statistically relevant. A select problem in these comparisons is the fact that neither Mummaneni nor McAfee were referring to double level procedures, their trials were looking at single level disc disease only and therefore may have worked with a less advanced disease of the spine. Only very few studies actually compare the two dual level procedures of ACDF and a combination of ACDF and arthroplasty. Hey et al. [18] performed a study in 2012 researching the solely double level related treatment of the cervical spine. Their study showed equal results for NDI for both treatments which could be confirmed in our study. Also in accordance with their findings we observed a faster return to work for arthroplasty (13 weeks vs. 22 weeks, $p=0.21$). In our study, however, the absence of subsidence was a stronger indicator for an early return to work (14 vs. 26 weeks, $p=0.21$). The strength of our observations is in that relationship the larger sample size, Hey et al. only had 7 patients for each treatment regime, whereas we were able to reach 47 hybrid and 64 fusion patients for evaluation. Another study regarding dual level spinal kinetics after fusion or arthroplasty on two levels was performed by Cardoso et al. [19], who found no difference in post op lordosis between both treatments but again only 24 patients with dual level disease were evaluated. Aside from clinical studies cadaveric studies regarding the biomechanics of the cervical spine for multilevel fusion in combination with arthroplasty have been performed in the last years Martin et al. [20], found that arthroplasty above a solid fusion significantly impacted the force needed to restore full extension and flexion to the arthroplasty level, indicating a heightened level of distress adjacent to a fused segment and an extended demand on the implanted prosthesis for motion preservation.

Arthroplasty in our study required more surgical revisions (3.1% vs. 10.6%, $p=0.11$) than fusion. In two cases, both times on the fused segment, revision had to be performed in terms of an additional foraminotomy for residual nerve root compression. In one case the cage had sintered into the underlying vertebrae with near total collapse of the intervertebral space. In only two out of five cases was the prosthesis responsible for revision surgery. Overall, discounting the revisions performed due to cage related issues, the revision rate of arthroplasty may be equal to that of fusion techniques.

By our best knowledge, this study is the only that compares two level fusion in groups of >40 patients and has shown a higher level of spacer subsidence for ACDF. We hypothesize that the use of an arthroplasty ACDF combination can reduce the level of stress on neighboring spine segments. Due to the nature of retrospective trials bias might have resulted from the definition of surgical success procuring from a post-operative ODI and X-ray data only. Also the surgeon's initial choice of treatment for the individual patients could have resulted in bias. To prevent this in future studies a prospective approach should be taken with a double blind choice of treatment on the day of surgery. Since both treatments are at least equally effective (McAfee [3]) we see no ethical violation in this course.

Conclusion

We found that ACDF and the combination of ACDF with arthroplasty used on two adjacent levels of the lower and mid cervical spine both produce good outcomes with no significant difference in ODI, VAS and duration of hospitalization or Odom's criteria. However, we found hybrid approaches to require a higher rate of surgical revision. Subsidence significantly influenced the alpha angle over the operated segment in terms of a loss of lordosis ($p=0.03$) However, the beta angles over the cervical spine from C2-C7 were equal for both treatments. The

	Effects of subsidence			
	Hybrid		Dual level fusion	
# Subsided Implants	VAS N/A*	Oswestry %	VAS N/A*	Oswestry %
0	3,30/2,6	20,7	3,9/3,21	32,8
1	4,4/2,4	24,6	1,7/1,1	26,5
2	0,00/0,00	2,0 (n=1)	3,1/3,1	22,8
*Neck/Arm				

Table 2: Subsidence in our patient population.

occurrence of subsidence was significantly higher for ACDF and may indicate more altered load on the fused segments ($p=0.001$). This may be significant in terms of patients return to work since patients' with radiographically visible subsidence, showing a longer period of work absence as did the patients from our fusion group.

Key Points

- Subsidence occurs significantly more often in two level ACDF than in ACDF with arthroplasty
- Subsidence reduces the alpha angle of the affected segment without affecting the overall beta angle
- The combination of arthroplasty and ACDF required more surgical revisions which were mostly cage related
- Both treatments produce an equally good outcome but the use of arthroplasty and the absence of subsidence permitted a faster return to work.

References

- Cloward RB (2007) The anterior approach for removal of ruptured cervical disks. 1958. J Neurosurg Spine 6: 496-511.
- Smith GW, Robinson RA (1958) The treatment of certain cervical-spine disorders by anterior removal of the intervertebral disc and interbody fusion. JBJS 40: 607-624.
- McAfee PC, Reah C, Gilder K, Eisermann L, Cunningham B (2012) A meta-analysis of comparative outcomes following cervical arthroplasty or anterior cervical fusion: results from 4 prospective multicenter randomized clinical trials and up to 1226 patients. Spine 37: 943-952.
- Korin MC (2008) Treatment of cervical degenerative disc disease - current status and trends. Zentralbl Neurochir 69: 113-124.
- Ishihara H, Kanamori M, Kawaguchi Y, Nakamura H, Kimura T (2004) Adjacent segment disease after anterior cervical interbody fusion. The spine J 4: 624-628.
- Coric D, Finger F, Boltes P (2006) Prospective randomized controlled study of the Bryan Cervical Disc: early clinical results from a single investigational site. J Neurosurg Spine 4: 31-35.
- Lee MJ, Dumonski M, Phillips FM, Voronov LI, Renner SM, et al. (2011) Disc replacement adjacent to cervical fusion: a biomechanical comparison of hybrid construct versus two-level fusion. Spine 36: 1932-1939.
- Fairbank JC, Pynsent PB (2000) The Oswestry Disability Index. Spine 25: 2940-2952.
- McAviney J, Schulz D, Bock R, Harrison DE, Holland B (2005) Determining the relationship between cervical lordosis and neck complaints. J Manipulative Physiol Ther 28: 187-193.
- Robertson JT, Papadopoulos SM, Traynelis VC (2005) Assessment of adjacent-segment disease in patients treated with cervical fusion or arthroplasty: a prospective 2-year study. J Neurosurg Spine 3: 417-423.
- Sugawara T, Itoh Y, Hirano Y, Higashiyama N, Mizoi K (2009) Long term outcome and adjacent disc degeneration after anterior cervical discectomy and fusion with titanium cylindrical cages. Acta neurochir 151: 303-309.
- Park JY, Kim KH, Kuh SU, Chin DK, Kim KS, et al. (2013) What are the associative factors of adjacent segment degeneration after anterior cervical spine surgery? Comparative study between anterior cervical fusion and arthroplasty with 5-year follow-up MRI and CT. Eur Spine J 22: 1078-1089.
- Nunley PD, Jawahar A, Kerr EJ, Gordon CJ, Cavanaugh DA, et al. (2012) Factors affecting the incidence of symptomatic adjacent-level disease in cervical spine after total disc arthroplasty: 2- to 4-year follow-up of 3 prospective randomized trials. Spine 37: 445-451.
- Prasarn ML, Baria D, Milne E, Latta L, Sukovich W (2012) Adjacent-level biomechanics after single versus multilevel cervical spine fusion. J Neurosurg Spine 16: 172-177.
- Mummaneni PV, Burkus JK, Haid RW, Traynelis VC, Zdeblick TA (2007) Clinical and radiographic analysis of cervical disc arthroplasty compared with allograft fusion: a randomized controlled clinical trial. J Neurosurg Spine 6: 198-209.
- Heller JG, Sasso RC, Papadopoulos SM, Anderson PA, Fessler RG, et al. (2009) Comparison of BRYAN cervical disc arthroplasty with anterior cervical decompression and fusion: clinical and radiographic results of a randomized, controlled, clinical trial. Spine 34: 101-107.
- Kang L, Lin D, Ding Z, Liang B, Lian K (2013) Artificial disk replacement combined with midlevel ACDF versus multilevel fusion for cervical disk disease involving 3 levels. Orthopedics 36: 88-94.
- Hey HW, Hong CC, Long AS, Hee HT (2013) Is hybrid surgery of the cervical spine a good balance between fusion and arthroplasty? Pilot results from a single surgeon series. Eur Spine J 22: 116-122.
- Cardoso MJ, Mendelsohn A, Rosner MK (2011) Cervical hybrid arthroplasty with 2 unique fusion techniques. J Neurosurg Spine 15: 48-54.
- Martin S, Ghanayem AJ, Tzermiadianos MN, Voronov LI, Havey RM, et al. (2011) Kinematics of cervical total disc replacement adjacent to a two-level, straight versus lordotic fusion. Spine 36: 1359-1366.