

# Combination of Medical Needling and ReCell® for Repigmentation of Hypopigmented Burn Scars

Kay H Busch<sup>1</sup>, Richard Bender<sup>1\*</sup>, Mehmet A Altintas<sup>2</sup>, Thomas Pech<sup>2</sup>, Thomas Rohn<sup>2</sup>, Nicole Walezko<sup>2</sup> and Matthias C Aust<sup>2</sup>

<sup>1</sup>Klinik für Plastische Chirurgie, Malteserkrankenhaus Bonn, Von Hompesch Str.1, Bonn, Germany

<sup>2</sup>Klinik für Plastische und Ästhetische Chirurgie / Handchirurgie, Bergmannsheil-Buer, Schernerweg 4, 45894 Gelsenkirchen, Germany

## Abstract

Burn scars remain a serious physical and psychological problem for the affected people. Clinical studies as well as basic scientific research have shown that medical needling can significantly increase the quality of burn scars with comparatively low risk and stress for the patient with regards to skin elasticity, moisture, erythema and transepidermal water loss. However, needling has no influence on repigmentation of large hypopigmented scars.

The goal is to evaluate whether both established methods – needling improvement of scar quality) and ReCell® (repigmentation) – can be combined. So far, 20 patients with mean age of 35 years (7-61 years) with deep second and third degree burn scars have been treated. The average treated tissue surface was 8% (2-18% TBSA) and was focused on areas like face, neck, chest and arm.

Percutaneous collagen induction or “medical needling” is performed using a roller covered with 3mm long needles. The roller is vertically, horizontally and diagonally rolled over the scar, inducing microtrauma. Then, ReCell® is applied, according to the known protocol. The patients have been followed 12 months postoperatively. Pigmentation changes are measured objectively, as well as with patient and observer ratings. Patient satisfaction/preference is also obtained. With this article we present first results of our ongoing study.

Taken together, the pigmentation ratings and objective measures indicate improvement in all study participants.

Medical needling in combination with ReCell® shows promise for repigmentation of burn scars.

## Combination of Medical Needling and ReCell® for Repigmentation of Hypopigmented Burn Scars

The skin as biggest human organ plays a major role for temperature and water regulation, communication and representation. Moreover it essentially serves as a mechanical barrier and also protects from ultraviolet rays by producing melanin.

By losing the physiological lattice pattern collagen and because of the absence or decreased amount of skin appendages, scar tissue frequently loses the aforesaid features of healthy skin. Thus, scars represent the replacement of healthy skin with poor tissue. They regularly remain rigid, dry and itching. Deeper second degree burns often cause death of melanocytes and can result in hypo- or depigmentation [1]. Additionally, scar tissue may provide a barrier to melanocyte migration and melanin transfer [2].

There are numerous methods to treat scar tissue. Beside classical surgical treatments like excision, w or z plasties, flaps or expanders, minimal invasive procedures like dermabrasio, Co<sup>2</sup>-Laser and deep peeling are highly demanded. The last treatments listed are ablative treatments. Using them on scar tissue with a lower amount of skin appendages and flat rete-pegs increases the risk of provoking new scarring [3]. Additionally, the skin becomes more vulnerable for ultraviolet rays and there is a raised risk for dyspigmentation [4,5].

Physical impairments like an increased photosensitivity and thus a higher risk of sunburn [6] can also have an enormous impact on a patient's quality of life like cosmetic aspects. Bright, conspicuous scars are a frequent reminder of traumatic situations or life events and are therefore often associated with posttraumatic stress disorder and depressions [7].

There are several therapies available for repigmentation of hypopigmented scars, like split thickness skin grafts or autologues skin cell transplantation. They are usually combined with the ablative treatments named before and can lead to the known complications like new scarring or dyspigmentation [8].

An ideal scar treatment or wound bed preparation for repigmentation therapies would be a treatment, which does not harm the epidermis and which initiate physiological wound healing with formation of lattice pattern collagen and growth factors. Recent clinical and scientific researches have shown, that it is possible to achieve this ideal skin regeneration by medical needling. Initiating a clinical study in 2008, the outcome of 480 patients, who were treated by medical needling or “percutaneous collagen induction”, was verified regarding satisfaction and cosmetic results [9]. Further, scientific research with histological and immunofluorescence studies combined with RNA analyses were realized to quantify the effects of this therapy [10]. Currently there are ongoing studies to prove these results in vivo by using special measuring instruments. These instruments are used directly on the patients' skin and are able to determine different skin parameters. One of these instruments is the Mexameter® for capturing the amount of melanin in the skin (see below). (The results of different studies about percutaneous collagen induction are presented below [9,10]).

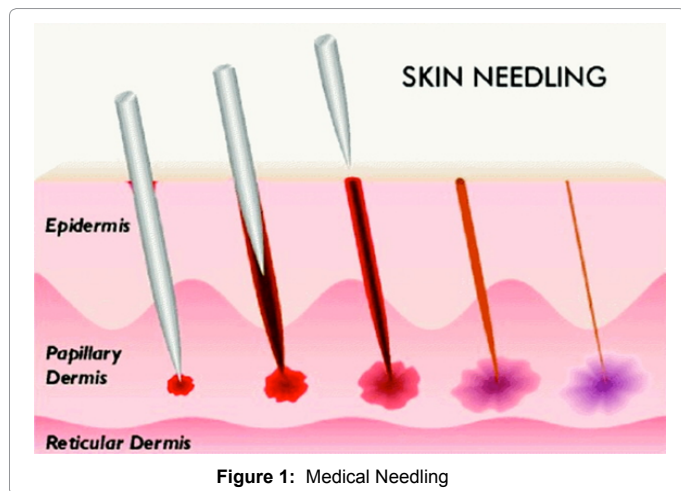
Medical needling can be used as a minimal-invasive, non-ablative treatment for burn scars. By using a roller covered with 3mm long needles and rolling vertically, horizontally and diagonally over the scars, the physician induces multiple punctures right up to the Dermis (Figures 1 and 2).

**\*Corresponding author:** Richard Bender, Malteserkrankenhaus Bonn, Von Hompesch Str. 1, 53123 Bonn, Germany, Tel: +49 (0) 228 64819161; E-mail: [bender.richard@t-online.de](mailto:bender.richard@t-online.de)

Received July 08, 2014; Accepted July 14, 2014; Published July 16, 2014

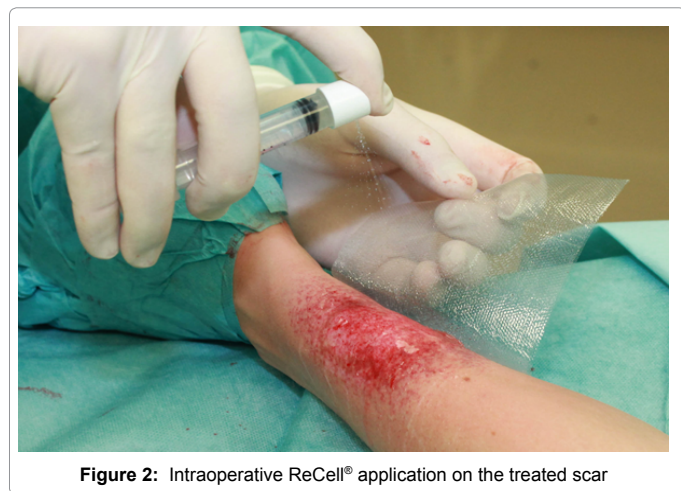**Citation:** Busch KH, Bender R, Altintas MA, Pech T, Rohn T, et al. (2014) Combination of Medical Needling and ReCell® for Repigmentation of Hypopigmented Burn Scars. *Pigmentary Disorders* 1:122. doi:10.4172/JPD.1000122

**Copyright:** © 2014 Busch KH. This is an open-access article distributed under the terms of the Creative Commons Attribution License, which permits unrestricted use, distribution, and reproduction in any medium, provided the original author and source are credited.



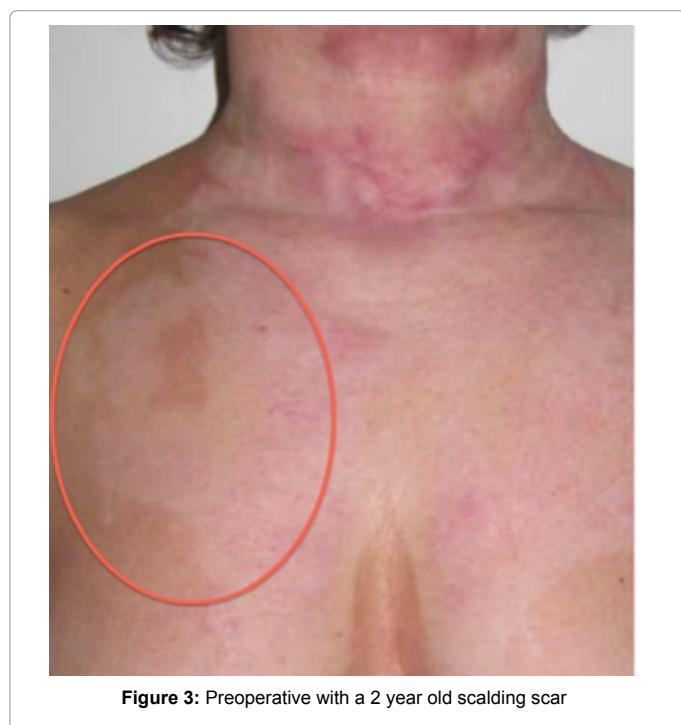Neither the structure of the epidermis nor the dermis are being changed or harmed.

The created microtrauma leads to intradermal bleeding which initiates the physiological wound healing cascade with the production of growth factors like Platelet Derived Growth Factor (PDGF) or Transforming Growth Factor  $\alpha$  and  $\beta$  (TGF- $\alpha$  und - $\beta$ ). TGF- $\beta_1$  and - $\beta_2$  are rather responsible for the formation of parallel organised collagen and are found in adult scars, whereas TGF- $\beta_3$  supports the formation of lattice pattern collagen as it is found in healthy skin and scar free wound healing. It has been shown that the level of TGF- $\beta_3$  remains high even beyond the initial wound healing phase (after 8 weeks), whereas TGF- $\beta_1$  and - $\beta_2$  are down regulated 2 weeks postoperative [10]. After medical needling the amount of keratinocytes rises. The consequence of this process is a thickening of the epidermis. Simultaneously, the count of fibroblasts increases, which eventuates in an increased collagen and elastin production and a growth of the extracellular matrix. Additionally, glykosaminoglykans are integrated more frequently in the dermis, which results in a decreased transepidermal waterloss and thus in a higher moisture of the scar.



The patients feel less itching and the scar contour and elasticity improves. It has been shown, that the pigmentation of the scars remains unchanged and that there is no dyspigmentation. Also there is no repigmentation of large (>10 cm<sup>2</sup>) hypopigmented scars detectable after needling.

ReCell® is available for repigmentation of hypopigmented skin [11,12]. This product is a spray suspension with living, autologous skin cells which are gained intraoperative and applied on the treated area. A 4-5 cm<sup>2</sup> piece of split thickness skin is digested with trypsin at 35°C in order to release the cells (keratinocytes, melanocytes, Langerhans cells, fibroblasts) from their extracellular matrix [13]. In the next step the cells are removed mechanically by scraping them from the skin with a scalpel. The hypothesis is, that the autologous cells get through the needling channels to the basal layer of the epidermis where they remain. After the closure of the needling channels, the transplantation is accomplished successfully.



ReCell® is usually combined with ablative therapies like dermabrasion or laserablation [14]. Treating healthy skin with these ablative methods is less harmful in comparison to the treatment of scars. Scars usually have a thinner Epidermis with a lower amount of rete pegs and skin appendages. Consequently there is a higher risk to provoke new scarring or to cause an impairment of the treated scar [2,15,16].

In order to find an alternative to these ablative treatments with the risks given above, our aim of this study is to evaluate the combination of non-ablative medical needling and ReCell® for repigmentation of hypopigmented burn scars.

We treated and examined 20 patients with 1 year old, large (>10 cm<sup>2</sup>) hypopigmented scars, who have never had a surgical treatment before. The appointments for examination are preoperative, 3,6 and 12 months postoperatively. We verified the success or failure by evaluating clinical aspects and by measuring the amount of melanin in the scar with the Mexameter®.

The clinical evaluation contains pictures taken prior to operation and afterwards. Moreover, the patient and observer assessment regarding the color difference and overall opinion of each scar is gathered with an ordinal scale (1: "like normal skin" to 10: "biggest difference imaginable to normal skin").

The Mexameter® measurement is based on the absorption principle. The probe emits light in defined wavelengths, which is specific for melanin (660 and 870 nm) and detects the reflected amount of the emitted light. By subtracting the reflected from the emitted light the Mexameter® computes the light absorbed by melanin and thus its amount.

Control parameters are a needling only scar, an untreated scar and healthy skin (Figures 3 and 4).

There are obvious hypopigmented areas preoperative on the patients' chest. By choosing the darker area on the right side of the patient as reference point, there is a remarkable repigmentation visible in the surrounding 1 year postoperative (Figures 5 and 6).

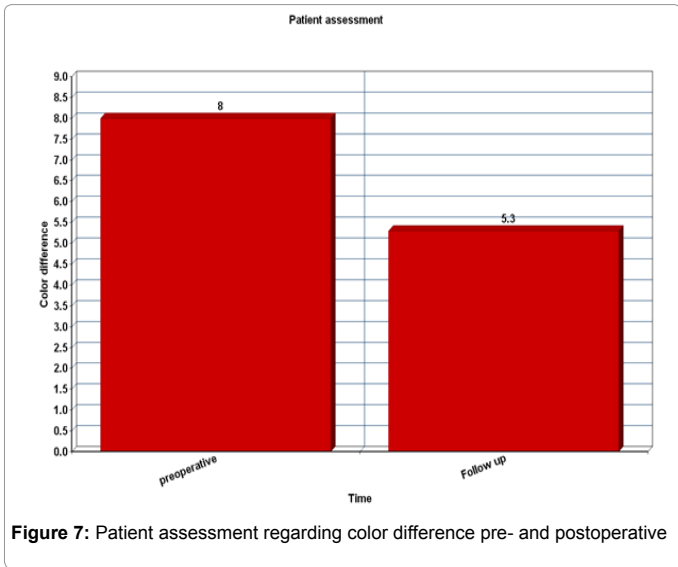
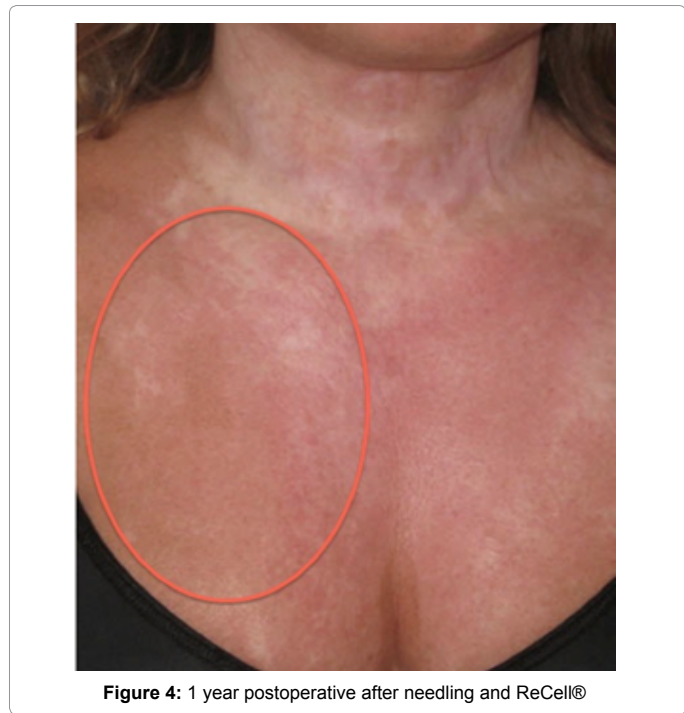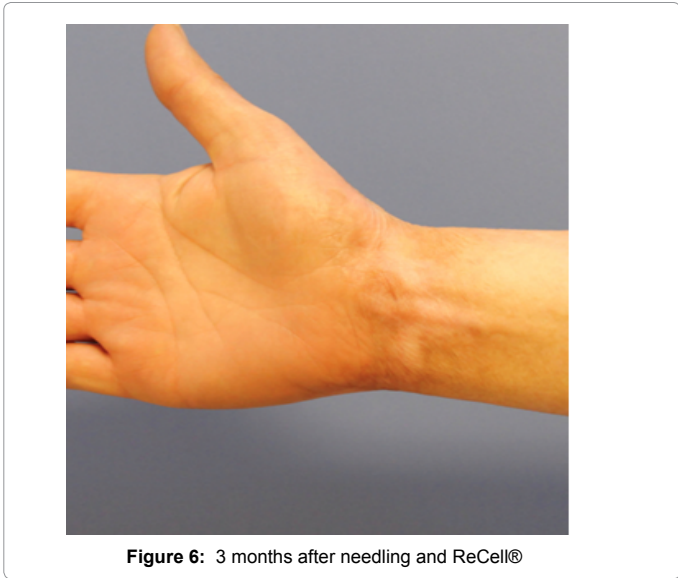
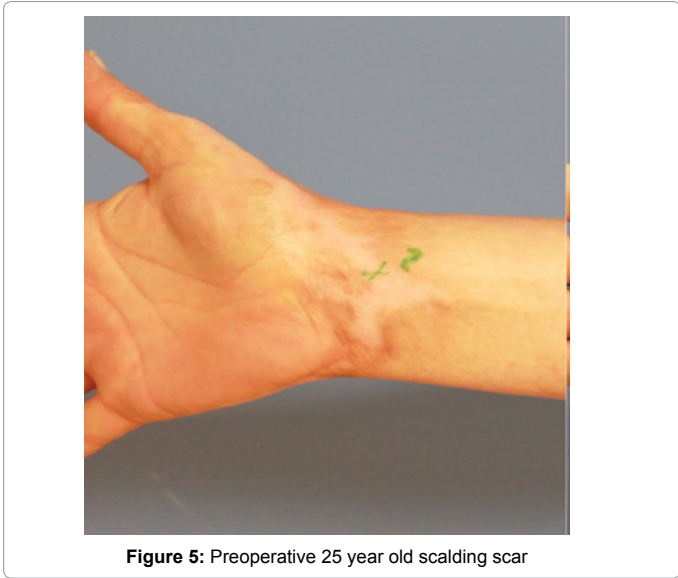
This picture shows an improvement of the scar and pigmentation as well. Beside these positive results presented in the picture documentation, it is noteworthy, that it is always difficult to reproduce the same camera angle, exposure to light or posture of the patient's body. Thus, both the subjective patient and observer assessments are a very important measurement to verify the success or failure of the combination of medical needling and ReCell®.

As it is presented in Figure 7 and 8 the patients assessed the color difference of their treated scars preoperative with 8 and postoperative at the last follow up with 5,3 points, which is a significant improve of 34%.

The observer assessed this parameter equally and scored the scars preoperative with 8,3 and postoperative with 5,5 points, which results in a significant improve of 34% as well.

The results of the Mexameter® are presented exemplarily on one patient below.

The red bar shows the melanin level of the scar treated with both therapies medical needling and ReCell®. This Scar is the only one which



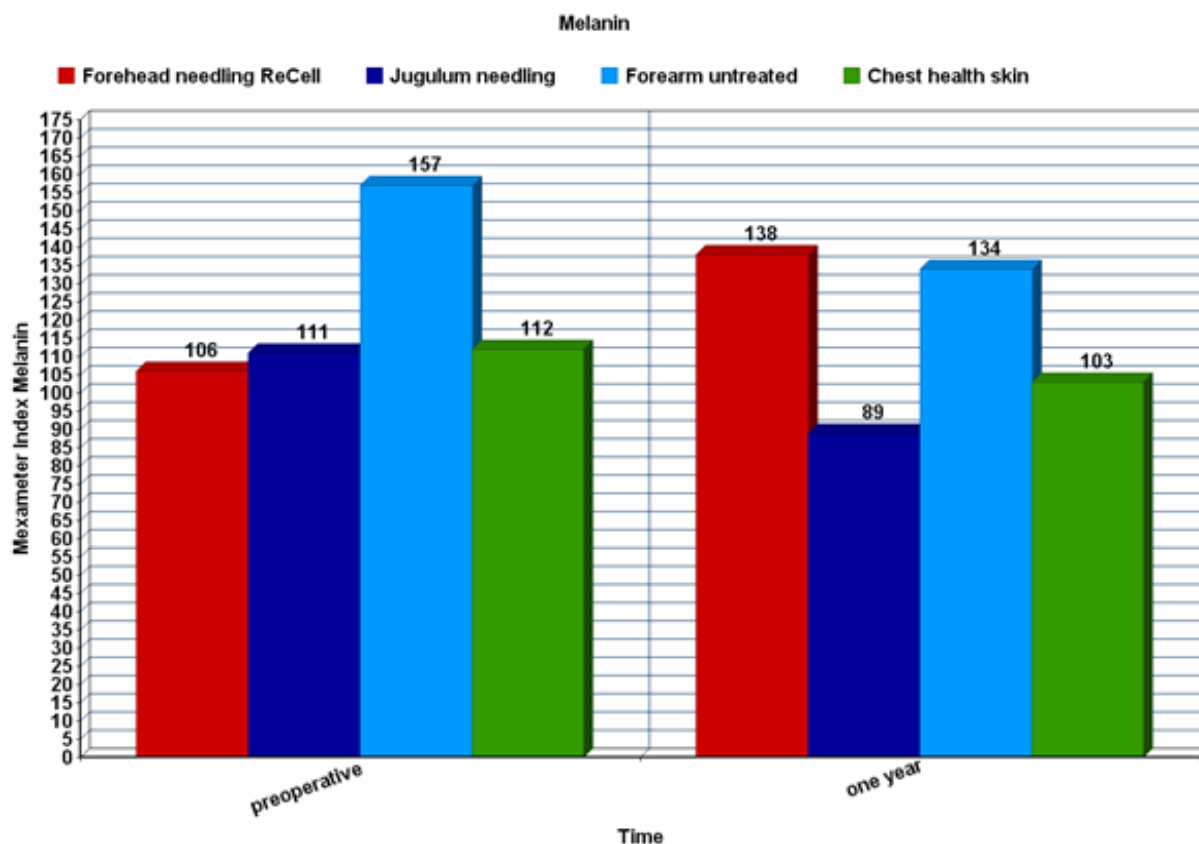


Figure 8: Mexameter® Melanin level at defined skin locations

shows an increase of melanin after the 1 year period. The amount of melanin in the control scars decreases and the healthy skin nearly remains at the same level.

However, beside these positive results, there are two non-responder, of ten patients with a complete one year follow up, which did not show an improvement of the pigmentation or melanin level. The reasons might be ascribed to the following circumstances: - invalid or incorrect Needling technique - invalid wound cleaning and washing before the application of ReCell®, whereby the puncture channels can be agglutinated with serous fluid - lack of immobilization of the treated scar or early detach of the wound dressing can lead to shear force and thus provoke death of the transplanted cells. An other point of discussion is, that the costs of the ReCell® therapy are not provided by the health insurance.

Taken together, the combination of medical needling and ReCell® does not harm the epidermis, the physical wound healing cascade is induced and sets free important growth factors, like TGF-β3, beyond the initial wound healing phase. These positive influences reduce the risk of new scarring on a minimum. Patients report a very low level of postoperative pain. Thus, the down time is very short, whereas the treatment can be done as an outpatient procedure. Our preliminary results show a marked subjective and objective improve of the pigmentation.

Considering all these factors at this point of our study, we come to

the conclusion, that the combination of medical needling and ReCell® is a very promising approach to repigment large hypopigmented burn scars.

#### References

- Grover R, Morgan BD (1996) Management of hypopigmentation following burn injury. *Burns* 22: 627-630.
- Bernstein LJ, Kauvar AN, Grossman MC, Geronemus RG (1997) The short- and long-term side effects of carbon dioxide laser resurfacing. *Dermatol Surg* 23: 519-525.
- Açikel C, Ulkür E, Güler MM (2000) Treatment of burn scar depigmentation by carbon dioxide laser-assisted dermabrasion and thin skin grafting. *Plast Reconstr Surg* 105: 1973-1978.
- Bernstein LJ, Kauvar AN, Grossman MC, Geronemus RG (1997) The short- and long-term side effects of carbon dioxide laser resurfacing. *Dermatol Surg* 23: 519-525.
- Scultetus AH, Villavicencio JL, Kao TC, Gillespie DL, Ketron GD, et al. (2003) Microthrombectomy reduces postsclerotherapy pigmentation: multicenter randomized trial. *J Vasc Surg* 38: 896-903.
- Njoo MD, Westerhof W (2001) Vitiligo. Pathogenesis and treatment. *Am J Clin Dermatol* 2: 167-181.
- Rumsey N, Clarke A, White P (2003) Exploring the psychosocial concerns of outpatients with disfiguring conditions. *J Wound Care* 12: 247-252.
- Mulekar SV, Isedeh P (2013) Surgical interventions for vitiligo: an evidence-based review. *Br J Dermatol* 169 Suppl 3: 57-66.
- Aust MC, Fernandes D, Kolokythas P, Kaplan HM, Vogt PM (2008) Percutaneous collagen induction therapy: an alternative treatment for scars, wrinkles, and skin laxity. *Plast Reconstr Surg* 121: 1421-1429.

10. Aust MC, Reimers K, Gohritz A, Jahn S, Stahl F, et al. (2010) Percutaneous collagen induction. Scarless skin rejuvenation: fact or fiction? *Clin Exp Dermatol* 35: 437-439.
11. Falabella R, Barona MI (2009) Update on skin repigmentation therapies in vitiligo. *Pigment Cell Melanoma Res* 22: 42-65.
12. Gauthier Y, Surleve-Bazeille JE (1992) Autologous grafting with noncultured melanocytes: a simplified method for treatment of depigmented lesions. *J Am Acad Dermatol* 26: 191-194.
13. Wood FM, Giles N, Stevenson A, Rea S, Fear M (2012) Characterisation of the cell suspension harvested from the dermal epidermal junction using a ReCell® kit. *Burns* 38: 44-51.
14. O'Neill TB, Rawlins J, Rea S, Wood F (2011) Treatment of a large congenital melanocytic nevus with dermabrasion and autologous cell suspension (ReCELL®): a case report. *J Plast Reconstr Aesthet Surg* 64: 1672-1676.
15. Roy D (2005) Ablative facial resurfacing. *Dermatol Clin* 23: 549-559,viii.
16. Ross EV, Naseef GS, McKinlay JR, Barnette DJ, Skrobal M, et al. (2000) Comparison of carbon dioxide laser, erbium:YAG laser, dermabrasion, and dermatome: a study of thermal damage, wound contraction, and wound healing in a live pig model: implications for skin resurfacing. *J Am Acad Dermatol* 42: 92-105.