

## Colonoscopy Induced Ischemic Colitis: A Case Report and Literature Review

Hai-Bo Zhou\*

Department of Gastroenterology, Second Hospital of Zhejiang University, Hangzhou 310009, PR China

\*Corresponding author: Hai-Bo Zhou, Department of Gastroenterology, Second Hospital of Zhejiang University, Hangzhou 310009, PR China, Tel: +81-10-87783563; Fax: +81-10-87783886; E-mail: [zhouhaibohz@163.com](mailto:zhouhaibohz@163.com)

Received date: Oct 28, 2015; Accepted date: Dec 10, 2015; Published date: Dec 12, 2015

Copyright: © 2015 Zhou HB. This is an open-access article distributed under the terms of the Creative Commons Attribution License, which permits unrestricted use, distribution, and reproduction in any medium, provided the original author and source are credited.

### Abstract

**Background:** The data of 21 cases of ischemic colitis, including 20 cases in previous reports and one case in this study, were reviewed and incorporated into comprehensive analysis.

**Case presentation:** Ischemic colitis occurred in 3-48 hours after colonoscopy in all patients, with the clinical manifestations of abdominal pain, diarrhea, bloody stools, and increased D-dimer levels. Endoscopic findings were mostly transient. The control measures included: reduced gas injection during examination, and timely withdrawal if excessive gas was injected; gentle operation and proper force used to maintain the colonoscope while retracting tissues; examination performed under intravenous anesthesia for nervous and anxious patients; blood volume supplement during intestinal preparation; and strict implementation of the rules for sterilization of colonoscopy.

**Conclusion:** Colonoscopy can lead to ischemic colitis, which should be brought to attention of endoscopists. For patients with ischemic colitis after colonoscopy, a second colonoscopy should be performed as soon as possible for diagnosis and timely treatment.

**Keywords:** Colitis; Ischemic; Colonoscopy

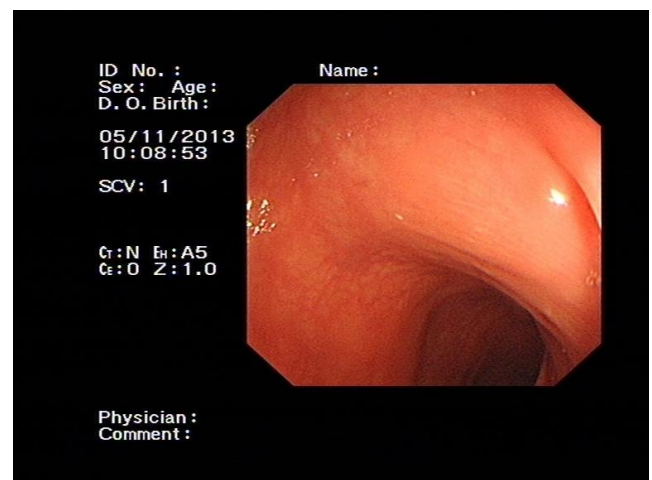
### Introduction

As one of the most intuitive means of diagnosis and treatment of diseases of the colon, colonoscopy has been widely used in clinical settings. Due to its invasive nature, the resulting complications have also been brought to the attention of clinicians. Ischemic colitis is an intestinal syndrome with nutritional disorders resulting from ischemic bowel damage due to poor blood perfusion of the intestinal wall induced by various causes. In this study, we report one case of ischemic colitis caused by colonoscopy, review the literature, analyze the clinical and endoscopic features of this disease, and discuss the preventive measures.

### Case Presentation

The patient was a 30-year-old woman, who visited the clinic for lower abdominal pain. During the examination, the colonoscope could reach no further beyond the hepatic flexure to the ascending colon, while the ileocecal valve and appendiceal orifice could be seen at the distal end. Endoscopic findings showed no abnormalities of the colonic mucosa (Figure 1). Two days after the colonoscopy, she experienced paroxysmal abdominal cramps, with bloody stools 7-8 times (40-50 ml each) on the same day. She was then admitted to the hospital for lower gastrointestinal bleeding. Physical examination showed body temperature 36.5°C, pulse 72 beats/min, breathing 18 times/min, blood pressure 94/58 mmHg, painful face, soft abdomen, lower abdominal tenderness, and no rebound tenderness. Shifting dullness was negative, and bowel sounds 3 times/min. Blood testing showed WBC  $12.7 \times 10^9/L$ , neutrophil percentage 86.1%, and hemoglobin 109 g/L. C-reactive protein was 219.2 mg/L, and D-dimer 3380  $\mu g/L$ .

Colonoscopy revealed congestion, edema and erosion of the descending colon and sigmoid colon. Abdominal vascular and peritoneal ultrasound showed no abdominal findings of the superior mesenteric artery and the aorta, and no obvious abnormalities in the abdominal cavity (Figure 2). Colonoscopic diagnosis was ischemic colitis. After fasting, fluid replacement, vasodilation and anti-inflammatory treatment for seven days, the abdominal pain disappeared and bleeding stopped, and she was discharged.



**Figure 1:** Normal intestinal mucosa of descending colon.

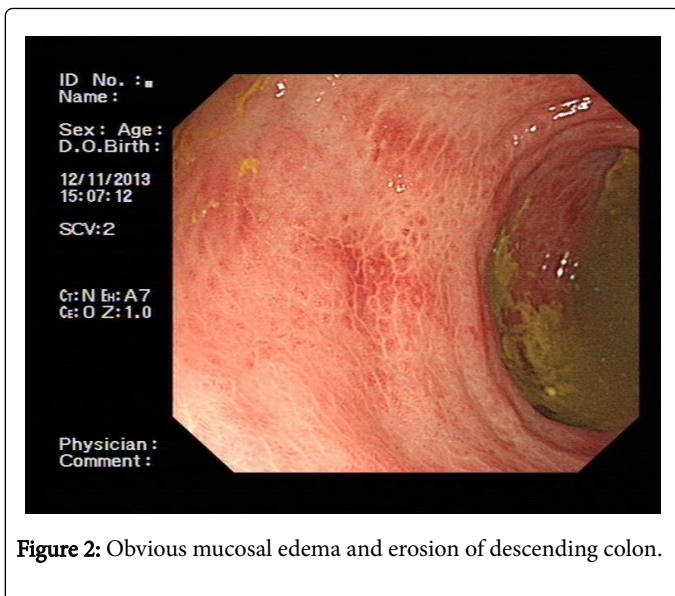


Figure 2: Obvious mucosal edema and erosion of descending colon.

## Discussion

The first case of ischemic colitis after colonoscopy was reported by Wheeldon et al. in 1990 [1]. Twenty-one cases, including 20 cases in previous reports and the case in this study, were analyzed, including 12 men and 9 women aged 32-76 years (with a median age of 56.7 years). Indications for colonoscopy were: endoscopic colon polyp resection (5 cases), abdominal pain (7 cases), diarrhea (5 cases), and constipation and bloating (4 cases). Five patients received colonoscopic polypectomy, 5 were diagnosed with colitis and 4 with colon melanosis, and no obvious abnormalities were found in the colon mucosa in 7 patients. The etiology, clinical manifestations, and endoscopic findings of ischemic colitis following colonoscopy, as well as the preventive measures are discussed as below in view of the previous reports and the present case.

## Etiology

There are various factors for the occurrence of ischemic colitis: (1) Intestinal factors: reduced local blood supply due to any causes and the resultant mucosal damage; the blood supply area at the left colon is more sensitive to visceral ischemic injury, so the majority of cases occur in the left colon. Luminal pressure and bowel motility, and increased intestinal pressure, which can lead to reduced intestinal blood supply, causing localized intestinal ischemia, thinning, necrosis, and transient ischemic mucosal damage (2). Lack of blood flow: any of the common causes of reduced splanchnic blood flow can lead to intestinal ischemia. On the basis of abdominal vascular lesions, heart failure, coronary atherosclerotic heart disease, arrhythmia or shock that causes decreased cardiac output, and other factors can all induce or aggravate intestinal ischemia, resulting in chronic ischemic bowel disease. (3) Hematologic changes: the hypercoagulable state is a high risk of reduced abdominal blood flow, precipitation into blood clots and blockage of intestinal blood vessels, such as polycythemia vera, thrombocythemia, long-term oral contraceptives, severe infection and radiotherapy and chemotherapy, which may cause this disease. (4) Other diseases such as intestinal and abdominal malignancies and obstruction can also lead to the occurrence of chronic ischemic bowel disease.

Based on the analysis, ischemic colitis following colonoscopy may be associated with the following factors: (1) Bowel spasms. During examination, patients with excessive mental stress may experience excessive intestinal movements and intestinal muscle spasms that give rise to vasoconstriction, causing intestinal ischemia [2]. (2) Hypovolemia due to improper intestinal preparation. Rapid laxatives prescribed during bowel preparation, especially high permeability laxatives, can cause intestinal wall dehydration, leading to excessive loss of intestinal liquid. Without timely replacement, the hypovolemia of the intestinal wall may give rise to intestinal ischemia [3,4]. (3) Excessive gas injection and prolonged examination during colonoscopy. Excessive gas injection increases the diameter of the intestine, intestinal muscle tension and the wall pressure, thus decreasing blood flow to the intestinal wall and thereby leading to intestinal ischemia. The longer the examination time is, the later reperfusion occurs when mucosal blood flow is restored, and in turn the worse intestinal damage will be. (4) Rough or sudden operations, particularly improper and excessive retraction. The colonoscope is often retracted when there is a sharp bend or the intestine is twisted. With excessive gas, retraction of the colonoscope against the intestinal wall without adequate space for the motion may increase the local pressure on the intestinal segment and wall upon the instrument, causing intestinal ischemia [5].

## Clinical manifestations

Ischemic colitis occurred in all the 21 patients after colonoscopy, mostly within 3-48 hours after the procedure. The clinical manifestations included abdominal cramps, bearing down, and bloody watery stools 10-20 times a day. Cardiovascular diseases or other medical history could be absent. Physical examination usually involved tenderness of the left abdomen, no rebound tenderness, and mostly with no sign of ascites, and normal or increased D-dimer levels. Vasodilator therapy was effective.

## Endoscopic findings

Marston et al. [6] classified the endoscopic manifestations of ischemic colitis into three types: 1) Transient type: mucosal congestion, edema, erosion, and ulcers can be seen. In patients with mild conditions, scattered superficial punctate ulcers or erythema with increased mucosal fragility can be found, the submucosal vascular texture disappears, with clear boundaries between lesions and normal mucosa, and ulcers can be seen in some cases. The ulcers are mostly longitudinally located at the mesenteric side, and may be associated with a small amount of bleeding, or invade the entire intestinal wall in a circular annular shape, which is not accompanied by stenosis. 2) Stenosis type: obvious mucosal hyperemia, edema, erosion, bleeding, and ulcers can be seen, and the lesions can longitudinally spread at the mesenteric side or invade the entire intestinal wall in a circular annular shape. Nodular bulges can be seen with stenosis of the intestinal cavity. 3) Gangrene type: Dark purple necrosis of the intestinal mucosa is visible, and huge ulcer or patchy bleeding can be formed.

The prominent characteristics of ischemic colitis after colonoscopy are the transient mucosal changes, phased distribution of lesions, mostly located in the left colon; and little bleeding during pathological examination.

## Preventive measures

Examination should be performed under intravenous anesthesia for anxious or nervous patients to reduce intestinal muscle spasms caused by intestinal irritation, and maintain steady blood supply of the intestinal wall. Intestinal gas should be suctioned as much as possible when retracting the scope. Blood volume should be supplemented during intestinal preparation. In case that oral administration is not possible, intravenous supplements should be used. Gas injection should be minimized during the examination. In the event of excessive injection, the gas should be suctioned to relieve pressure on the intestinal wall and restore intestinal blood flow as quickly as possible. Maneuver should be gentle while maintaining the flexible space for the bend buttons. An appropriate force should be maintained when retracting the hook. Otherwise, the knobs should be adjusted immediately to avoid mechanical intestinal blood supply interruption and the consequent intestinal mucosal ischemia. The duration should be as short as possible. For challenging cases, physicians at a higher level should be invited for consultation.

## Conclusion

Colonoscopy usually leads to ischemic colitis, which should be brought to attention of endoscopists. For patients with ischemic colitis after colonoscopy, a second colonoscopy should be performed as soon as possible for diagnosis and timely treatment.

## Consent

Written informed consent was obtained from the patient for publication of this Case report and any accompanying images.

## Acknowledgements

We thank our colleagues Cai-hua Wang und Qing-yu Chen who also took care of the patient during his hospital stay.

## References

1. Wheeldon NM, Grundman MJ (1990) Ischaemic colitis as a complication of colonoscopy. *BMJ* 301: 1080-1081.
2. Green BT, Tendler DA (2005) Ischemic colitis: a clinical review. *South Med J* 98: 217-222.
3. Church JM (1995) Ischemic colitis complicating flexible endoscopy in a patient with connective tissue disease. *Gastrointest Endosc* 41: 181-182.
4. Cremers MI, Oliveira AP, Freitas J (1998) Ischemic colitis as a complication of colonoscopy. *Endoscopy* 30: S54.
5. Versaci A, Macri A, Scuderi G, Bartolone S, Familiari L, et al. (2005) Ischemic colitis following colonoscopy in a systemic lupus erythematosus patient: report of a case. *Dis Colon Rectum* 48: 866-869.
6. Marston A, Pheils MT, Thomas ML, Morson BC (1966) Ischaemic colitis. *Gut* 7: 1-15.

This article was originally published in a special issue, entitled: "**Cytopathology**", Edited by Borislav A. Alexiev Department of Pathology University of Maryland Medical Center USA