

Clinico-Pathologic Observation of Valvular Leakage after Transcatheter Aortic Valve Implantation

Yudai Tamura¹, Kenji Sakata¹, Shohei Yoshida¹, Hayato Tada¹, Kenshi Hayashi¹, Mika Mori¹, Hirofumi Takemura², Akishi Oi³, Masakazu Yamagishi^{1*} and Masa-aki Kawashiri¹

¹Department of Cardiovascular and Internal Medicine, Kanazawa University Graduate School of Medicine, Kanazawa, Japan

²Department of Cardiothoracic Surgery, Kanazawa University Graduate School of Medicine, Kanazawa, Japan

³Department of Human Pathology, Kanazawa University Graduate School of Medicine, Kanazawa, Japan

Abstract

Here, we reported a case who underwent Transcatheter Aortic Valve Implantation (TAVI) which was complicated with aortic regurgitation. Echocardiography revealed both trans- and para valvular regurgitation. Unfortunately, the patient died of congestive heart failure. From autopsy findings, there observed the small space between transplanted valve and aortic wall and the incomplete valve closure both of which were coincided with echocardiographic findings. We suggest that careful observation by echocardiography can detect aortic regurgitation which could be one the factors for determining outcomes after TAVI.

Keywords: Aortic valve; Echocardiography; Implantation

Introduction

Transcatheter aortic valve implantation (TAVI) had been widely performed for treatment of aortic stenosis. Although efficacy of TAVI is recognized, there exists problem particularly relating to the occurrence of aortic regurgitation after procedure.

Case Report

The patient of 83-year-old man was admitted to our clinic because of shortness of breath during exercise. He had had a history of aortic stenosis at the age of 79, when the surgeon gave up aortic valve implantation due to co-existing complications. At the age of 80, the patient received TAVI [1] in another hospital using SAPIEN valve of 23 mm (Edwards, USA). For the occurrence of the atrioventricular block, pacemaker was implanted. Importantly, aortic regurgitation remained just after the procedure. Three years after TAVI procedure, heart failure gradually developed. Echocardiography showed small amount of aortic valve regurgitation which consisted of para- and transvalvular leakages (Figure 1, upper left and right). The patient died of respiratory as well as heart failure. In autopsy, the resected artificial valve did not show any damage of leaflets of valve. Importantly, between valve stent and aortic wall there existed the site of leakage which was exactly identified by echocardiography (Figure 1, lower left and center). Moreover, there was small area of leakage at the center of valve (Figure 1, lower right).

Discussion

TAVI frequently associates aortic regurgitation which can determine the prognosis after the procedure [2]. However, few data exist regarding simultaneous observations of echocardiography and pathology after TAVI. In the present case, echocardiography, even from transthoracic approach, could demonstrate both trans- and para valvular leakage of aortic valve. Importantly, these observations coincided with autopsy findings. Of course, transesophageal echocardiography will more clearly demonstrate these lesions than transthoracic approach, although transesophageal approach is somewhat invasive particularly for old patients with TAVI.

Conclusion

From this particular case, we would suggest that echocardiography, even transthoracic approach, gives an important information regarding the occurrence of regurgitation.

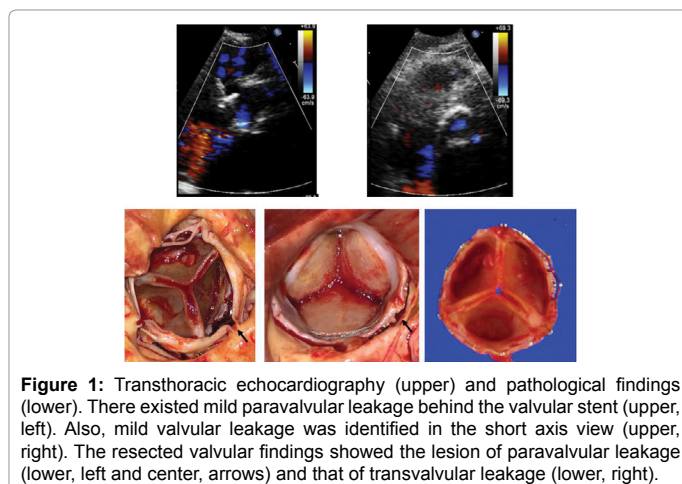


Figure 1: Transthoracic echocardiography (upper) and pathological findings (lower). There existed mild paravalvular leakage behind the valvular stent (upper, left). Also, mild valvular leakage was identified in the short axis view (upper, right). The resected valvular findings showed the lesion of paravalvular leakage (lower, left and center, arrows) and that of transvalvular leakage (lower, right).

References

1. Cribier A, Eltchaninoff H, Bash A, Borenstein N, Tron C, et al. (2002) Percutaneous transcatheter implantation of an aortic valve prosthesis for calcific aortic stenosis: First human case description. *Circulation* 106: 3006-3008.
2. Tamburino C, Capodanno D, Rampondo A, Petronio AS, Ettori F et al. (2011) Incidence and predictors of early and late mortality after transcatheter aortic valve implantation in 663 patients with severe aortic stenosis *Circulation* 123: 299-308.

***Corresponding author:** Masakazu Yamagishi, Department of Cardiovascular and Internal Medicine, Kanazawa University Graduate School of Medicine, Kanazawa, Japan, Tel: +81-76-265-2000 (2251); Fax: +81-76-234-4251; E-mail: myamagi@med.kanazawa-u.ac.jp

Received October 11, 2017; **Accepted** October 25, 2017; **Published** October 31, 2017

Citation: Tamura Y, Sakata K, Yoshida S, Tada H, Hayashi K, et al. (2017) Clinico-Pathologic Observation of Valvular Leakage after Transcatheter Aortic Valve Implantation. *J Clin Case Rep* 7: 1034. doi: 10.4172/2165-7920.10001034

Copyright: © 2017 Tamura Y, et al. This is an open-access article distributed under the terms of the Creative Commons Attribution License, which permits unrestricted use, distribution, and reproduction in any medium, provided the original author and source are credited.