

Clinical Utility of High-Throughput Sequencing for Pregnancies with Ultrasound Anomalies in Southern China

Zhao P^{1-5*}, Lin L^{1-5,†}, Wang H¹⁻⁵ and Lan L⁶

¹Clinical Core Laboratory, Meizhou People's Hospital (Huangtang Hospital), Meizhou Hospital Affiliated to Sun Yat-sen University, Meizhou, P.R. China

²Center for Precision Medicine, Meizhou People's Hospital (Huangtang Hospital), Meizhou Hospital Affiliated to Sun Yat-sen University, Meizhou, P.R. China

³Meizhou Municipal Engineering and Technology Research Center for Molecular Diagnostics of Major Genetic Disorders, Meizhou, P.R. China

⁴Guangdong Provincial Engineering and Technology Research Center for Molecular Diagnostics of Cardiovascular Diseases, Meizhou, P.R. China

⁵Meizhou Municipal Engineering and Technology Research Center for Molecular Diagnostics of Cardiovascular Diseases, Meizhou, P.R. China

⁶Center for Reproductive Medicine, Meizhou People's Hospital (Huangtang Hospital), Meizhou Hospital Affiliated to Sun Yat-sen University, Meizhou, P.R. China

Abstract

We evaluated the clinical utility of high-throughput sequencing for fetal abnormalities detected with ultrasound examination. This study included pregnant women who were at risk for fetal aneuploidy with or without ultrasonography abnormalities, and who underwent invasive surgery. High-throughput sequencing was used for cell-free fetal DNA analysis, and some positive results were compared with conventional karyotyping. This study involved 971 pregnancies, cell-free fetal DNA identified 15 of 18 (83.33%) as fetal Down syndrome, 4 of 5 (80.00%) as trisomy 18, and 0 of 1 (0.00%) as trisomy 13. Comparing high-throughput sequencing results with conventional fetal karyotypes, we observed that sequencing revealed sub-chromosomal duplications or deletions, but results of karyotyping showed aberrations in chromosome structure or a normal karyotype. One chromosomal balanced translocation was inherited from the mother, another one chromosomal abnormalities was inherited from the father. When fetal chromosomal abnormalities were found by ultrasound abnormalities, non-invasive prenatal testing should not be recommended for the genetic evaluation. Invasive procedure should be first offered to the pregnant woman when abnormal nuchal translucency or other ultrasound abnormalities were found. During invasive prenatal diagnostic testing, fetal chromosomal anomalies should be evaluated by high-throughput sequencing combining with conventional karyotyping.

Keywords: High-throughput sequencing; Ultrasound anomalies; Prenatal diagnosis; Conventional karyotyping; Southern China

Introduction

Chromosomal aneuploidy is the most common of chromosome abnormalities and includes trisomy 21, trisomy 18, trisomy 13, and some sex chromosome aneuploidies, such as 45, X, 47, XXY, and 47, XYY. Prefumo's group found that some ultrasonographic indices in early pregnancy could be used to evaluate the fetus with Down syndrome, such as increased nuchal translucency, absence of nasal bone, or hypoplasia [1]. Since the 1970s, pregnant women older than 35 years old were screened for Down syndrome and serological examination was subsequently used to assess risk. At present, the most widely used fetal assessment is ultrasound plus maternal serum biochemistry [2,3]. In 1997, Lo's group reported that cell-free fetal DNA (cffDNA) was present in peripheral blood of pregnant women, and this led the way to non-invasive prenatal testing (NIPT) based on cffDNA [4].

The development of NIPT using high-throughput sequencing (HTS) of cffDNA in maternal peripheral blood plasma provides an alternative approach for measuring fetal genetic aberrations and it is safe, requiring only blood samples. Many clinical studies indicate that NIPT can be used to confirm common chromosome aneuploidy (trisomy 21, 18 and 13) with high sensitivity and specificity and these data are increasingly accepted in clinical practice [5-8]. Non-invasive identification of microdeletions and microduplications at a resolution comparable to microarray analysis has been shown to be feasible [9,10]. NIPT can be carried out in the first 12 weeks of pregnancy, accelerating fetal data collection. Information obtained may facilitate pregnant women and their partners making decision, performing invasive prenatal diagnosis or ultrasonographic follow-up. Thus, we evaluated the application of HTS for non-invasive or invasive prenatal testing for pregnancies at high risk for fetal chromosomal abnormalities as identified with ultrasound.

Materials and Methods

Patient cohort

From January to December 2016, pregnant women participated in prenatal testing at the Meizhou People's Hospital (Huangtang Hospital), Meizhou Hospital Affiliated to Sun Yat-sen University. This study was approved by the Ethics Committee of Meizhou People's Hospital, Huangtang Hospital, Meizhou Hospital Affiliated to Sun Yat-sen University and all patients signed informed consents. Subjects were considered with high-risk for fetal aneuploidies, included advanced maternal age alone (older than 35-years of age), maternal serum screening for high risk, abnormal fetal ultrasound findings, or a history of pregnancy with trisomy and who were willing to undergo invasive procedures. All pregnancies were a singleton or twin pregnancy and were well past 11 weeks of gestation.

Genetic testing

Before NIPT was performed, 5 to 10 mL of peripheral blood was

***Corresponding author:** Dr. Pingsen Zhao, PhD, Head and Associate Professor of Clinical Core Laboratory, Center for Precision Medicine, Meizhou People's Hospital (Huangtang Hospital), Meizhou Hospital Affiliated to Sun Yat-sen University, No 63 Huangtang Road, Meijiang District, Meizhou 514031, P.R. China, Tel: +753-2131-591, Fax: +753-2131-592; E-mail: zhaopingsen01@163.com or zhaopingsen@hotmail.com

Received April 11, 2018; Accepted April 19, 2018; Published April 23, 2018

Citation: Zhao P, Lin L, Wang H, Lan L (2018) Clinical Utility of High-Throughput Sequencing for Pregnancies with Ultrasound Anomalies in Southern China. J Mol Genet Med 12: 349 doi:10.4172/1747-0862.1000349

Copyright: © 2018 Zhao P, et al. This is an open-access article distributed under the terms of the Creative Commons Attribution License, which permits unrestricted use, distribution, and reproduction in any medium, provided the original author and source are credited

collected in an EDTA tube from each pregnant woman. In order to separate plasma, blood was centrifuged at $1,600 \times g$ for 10 min at 4°C . Next, plasma was transferred to a new polypropylene tube, centrifuged at $16,000 \times g$ for 10 min at 4°C to precipitate the remaining cells [11,12]. According to kit instructions, cfDNA was extracted from 600 μL of maternal plasma, using a QIAamp DSP DNA Blood Mini Kit (Qiagen). Then, according to the Ion Plus Fragment Library Kit (Life Technologies), DNA from maternal plasma was used for library construction, finally, according to the manufacturer's instructions (Life Technologies), semiconductor sequencing was performed using an Ion Proton instrument at 400 flows. If invasive diagnostic testing was performed, fetal tissues (amniotic fluid or chorionic villus sampling) were obtained according to standard procedures. Tissues were assayed with HTS (CapitalBio Genomics) and conventional karyotyping.

Data collection

We reviewed the medical records to extract pregnant women information, such as maternal age and weight, gestational age at time of NIPT blood sampling, results of NIPT and karyotyping, and the results from follow-up ultrasound.

Results

From January to December in 2016, 971 pregnant women were performed with prenatal genetic testing, and NIPT was used as a first-line test for identification of genetic aberrations. Figure 1 depicts the design flow and subjects enrolled.

Results of NIPT

Figure 1 depicts outcomes for 911 pregnancies studied. When NIPT was performed, ultrasound anomalies were present in only

one fetus for all multiple pregnancies (Figure 2). Characteristics of pregnant women included in the cohort are presented in Table 1. In two cases, findings of NIPT and findings of diagnostic testing were discordant. In one specific case, when ultrasound was performed at 18 weeks of gestational age, no fetal structural anomalies were observed. Due to a prior positive serum marker, NIPT was applied at 20 weeks and suggested trisomy 21 and follow-up ultrasound at this time revealed an absent nasal bone and nuchal fold thickening, suggestive of trisomy 21. Fetal tissue obtained by amniocentesis for traditional karyotype analysis and confirmed trisomy 21, then, the pregnancy was terminated. In the second case, fetal with trisomy 18, no ultrasound anomalies were observed at 12 weeks but 3 weeks later, a ventricular septal defect, tricuspid regurgitation, and overlapping fingers were confirmed.

Sub-chromosomal aberrations were identified using NIPT for six other pregnancies. We suspected for one case was maternal origin because of a relatively high region-specific Z-score. Follow-up ultrasound showed no structural anomalies, but these data were not confirmed with HTS of the mother's genomic DNA.

Comparison of NIPT results with conventional fetal karyotype

For 35 pregnant women, NIPT was performed with conventional fetal karyotyping. Ultrasound data were not obtained for 5 (3 pregnancies diagnosed as trisomy 21) of 35 pregnancies. Patients were stratified based on fetal ultrasound findings (structural or "soft markers"). Group 1 included 16 patients without abnormal fetal ultrasound findings but at high-risk according to NIPT. Group 2 included 14 patients at high-risk with abnormal fetal ultrasound findings (fetal nuchal fold thickening

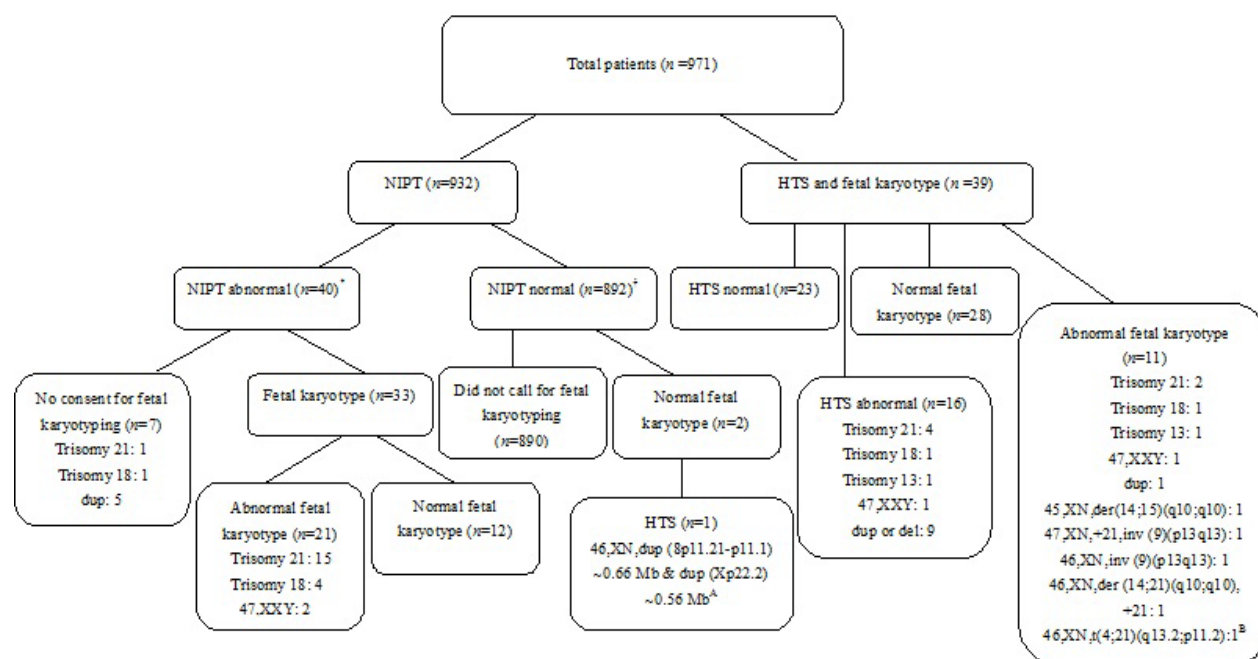


Figure 1: Group A: The couple underwent high-throughput sequencing and karyotyping, the result of maternal was normal, but the paternal sequencing result was the same as the fetal, indicated that the fetal chromosomal abnormalities were inherited from father. **Group B:** The result of fetal karyotyping was the same as maternal, considering that the abnormality was inherited from mother. *Of these 40 pregnant women, 20 performed NIPT in other hospitals, and performed conventional fetal karyotyping in Meizhou People's Hospital (Huangtang Hospital), Meizhou Hospital Affiliated to Sun Yat-sen University. † Of these 892 pregnant women, 1 performed NIPT in other hospital and performed conventional fetal karyotyping in Meizhou People's Hospital (Huangtang Hospital), Meizhou Hospital Affiliated to Sun Yat-sen University (NIPT: Non-invasive prenatal testing, HTS: High-throughput sequencing, dup: Duplication, del: Deletion, der: Derivative, inv: Inversion, t: Translocation).

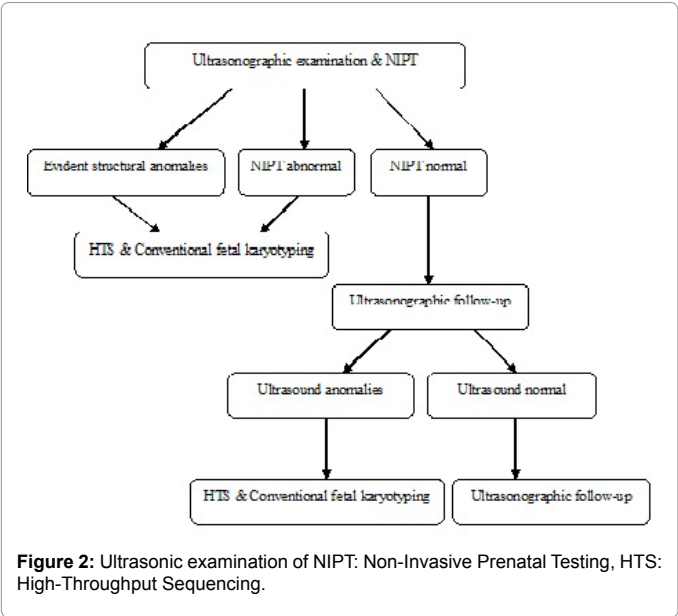


Figure 2: Ultrasonic examination of NIPT: Non-Invasive Prenatal Testing, HTS: High-Throughput Sequencing.

Parameters	Value
Maternal age (years)	
Median (range)	32 (17-44)
Maternal weight at time of NIPT (kilogram)	
Median (range)	56 (31-95)
Singleton pregnancy	
Yes	879 (96.49%)
No	32 (3.51%)
Gestational age at time of NIPT (weeks)	
Median (range)	16 (11-30)

Table 1: Characteristics of pregnant women included in the study (n=911).

or multiple structural anomalies). In Group 1, NIPT and conventional fetal karyotype data were discordant. In Group 2, NIPT confirmed fetal karyotype, and only one was 45, XO with a normal fetal karyotype. Ultrasound follow-up confirmed intra-uterine demise (Table 2).

Comparison of HTS results with conventional fetal karyotype

For 39 pregnant women, HTS and conventional fetal karyotyping was performed and after analysis, subjects were placed into two groups. Group 1 included 5 patients with no abnormal fetal ultrasound findings, and 3 cases with normal fetal karyotypes, one with trisomy 21. Another one was confirmed as balanced translocation, because the result of fetal karyotyping was the same as maternal, considering that the abnormality was inherited from mother. Group 2 included 34 patients at high-risk of multiple congenital anomalies, soft markers, or other anomalies. HTS data suggested subchromosomal duplications or deletions, but karyotyping showed aberrations in chromosome structure or data were normal. For one patient in our study, a positive karyotyping result for chromosome 21 was observed, but HTS confirmed high-level mosaicism (60%). We speculated that the mosaicism may be an artifact of contamination from chorionic villus sampling. Another normal NIPT and fetal karyotype results had abnormal HTS data indicating subchromosomal duplications. The couple had sequencing and karyotyping and maternal data were normal but paternal sequencing result was the same as fetal data suggesting that the fetal chromosomal abnormalities were inherited from father (Table 3).

NIPT result	Fetal karyotype
Group 1 (n=16)	
Positive trisomy 21 (n=7)	Positive trisomy 21 (n=4)
Positive trisomy 18 (n=2)	Positive trisomy 18 (n=1)
Positive trisomy 13 (n=1)	Positive trisomy 13 (n=0)
Sex chromosome aneuploidies (n=5)	Sex chromosome aneuploidies (n=1)
Other' (n=1)	Other' (n=0)
Normal (n=0)	Normal (n=10)
Group 2 (n=14)	
Positive trisomy 21 (n=8)	Positive trisomy 21 (n=8)
Positive trisomy 18 (n=3)	Positive trisomy 18 (n=3)
Positive trisomy 13 (n=0)	Positive trisomy 13 (n=0)
Sex chromosome aneuploidies (n=1)	Sex chromosome aneuploidies (n=0)
Other' (n=0)	Other' (n=0)
Normal (n=2)	Normal (n=3)

Table 2: Comparison of NIPT results with conventional fetal karyotype according to the absence (Group 1) or presence (Group 2) of fetal findings at ultrasound examination.

Groups	HTS result	Fetal karyotype	Tissue
Group 1 (n=5)	47, XN, +21	47, XN, +21	AF
	46, XN, del (14q32.33) ~1.26Mb	Normal	AF
	Normal	6, XN, t (4;21) (q3.2; p11.2) ^B	AF
	47, XXY	47, XXY	AF
	46, XN, dup (14q21.1-q22.3) ~18Mb	46, Xn, dup(14)(q21.1q22.3)	AF
Group 2 (n=34)	6, XN, dup (5q23.3) ~0.76Mb	45, XN, der(14;15)(q10;q10)	AF
	47, XX, +21[60]/46, XX[40]	47, XN, +21, inv(9)(p13q13)	CVS
	46, XN, dup (2q36.3) ~1Mb & dup (20p12.1) ~0.48Mb	Normal	AF
	46, XN, del (17q12) ~1.68Mb & dup (Xp11.3-p11.3) ~0.6Mb	Normal	AF
	46, XN, dup (7p21.1) ~0.5Mb	Normal	AF
	46, XN, del (22q11.21) ~3.32Mb	46, Xn, inv(9)(p13q13)	AF
	47, XN, +13	47, XN, +13	AF
	47, XN, + 21	46, XN, der(14;21) (q10;q10),+21	AF
	46, XN, dup (8p11.21-p11.1) ~0.66Mb & dup (Xp22.2) ~0.56Mb ^A	Normal	AF
	46, XN, dup (Xq13.1) ~0.46Mb	Normal	AF
	Normal (n=1)	Normal (n=1)	CVS
	Normal (n=19)	Normal (n=19)	AF

HTS: High-throughput sequencing, del: Deletion, AF: Amniotic fluid, t: Translocation, dup: Duplication, CVS: Chorionic villus sampling, der: Derivative, inv: Inversion. **Group A:** The couple underwent throughput sequencing and karyotyping, the result of maternal was normal, but the paternal sequencing result was the same as the fetal, indicated that the fetal chromosomal abnormalities were inherited from father. **Group B:** The result of fetal karyotyping was exactly the same as maternal, considering that the abnormality was inherited from mother.

Table 3: Comparison of HTS results with conventional fetal karyotype according to the absence (Group 1) or presence (Group 2) of fetal findings at ultrasound examination.

Discussion

This is the first evaluation of the application of HTS for non-invasive or invasive prenatal testing of pregnant women at high risk for fetal chromosomal abnormalities found based on ultrasonography. Our results show that NIPT should not be as a genetic assessment

diagnostic test for the etiology of ultrasound abnormalities. Because of the resolution and sensitivity, or negative predictive values were inferior to conventional G-band karyotyping.

With NIPT, a fetal DNA fraction of 4% or greater is estimated, resolution and sensitivity of NIPT is mainly limited by sequencing depth when sufficient fetal DNA was presence [13,14]. Predictably that technology will advance to allow non-invasive detection of microdeletions and microduplications. But, even though the resolution and sensitivity of NIPT is comparable to microarray analysis, it cannot be recommended for genetic assessment of the source of abnormal ultrasound because maternal genetic aberrations may exist and complicate analysis of abnormal results. Although NIPT can be used as a first-tier test for identifying genetic problems, abnormal results demand microscopic G-band karyotyping. Furthermore, NIPT has low efficacy for detecting trisomy 13 and sex chromosomal abnormalities, which may be related to chromosome copy number variability and may be limited by our small sample size [15,16]. Thus, more work is needed to validate sequencing data to improve efficiency.

HTS can be used to identify major chromosomal aneuploidy and submicroscopic changes too small to find with conventional karyotyping (resolution 5-10 Mb) [17]. Duplicated or deleted sections of DNA or “copy number variants” can be what? HTS can identify nearly all abnormalities detectable with karyotype (except for structural abnormalities or triploidy, structural abnormalities such as balanced translocations). In this study, we noted that fetal chromosomal abnormalities with sub-chromosomal duplications cannot be detected by conventional fetal karyotyping, because the paternal sequencing result was the same as the fetal data. This indicated that the abnormalities were inherited from the father. Another pregnancy, with a normal sequencing result, was confirmed as a balanced translocation by conventional karyotyping, because fetal karyotyping was the same as the maternal data, suggesting that the abnormality was inherited from mother. So, we recommend HTS for invasive prenatal genetic plus conventional fetal karyotyping for pregnancies at high-risk for fetal chromosomal abnormalities as indicated by ultrasound. This study is limited by a lack of outcomes assessment with ultrasound follow-up.

Conclusion

NIPT should not be recommended for the genetic evaluation of fetal chromosomal abnormalities when ultrasound abnormalities were found. In the case of fetal with abnormal nuchal translucency or other ultrasound findings, pregnant woman should be first offered an invasive procedure. During invasive prenatal diagnostic testing, fetal chromosomal anomalies should be evaluated by high-throughput sequencing combining with conventional karyotyping.

Acknowledgements

The author would like to thank other colleagues whom were not listed in the authorship of Clinical Core Laboratory and Center for Precision Medicine, Meizhou People's Hospital (*Huangtang Hospital*), Meizhou Hospital Affiliated to Sun Yat-sen University for their helpful comments on the manuscript.

Contributors

Pingsen Zhao conceived and designed the experiments; Lifang Lin and Liubing Lan recruited subjects and collected clinical data. Pingsen Zhao, Lifang Lin and Huaxian Wang conducted the laboratory testing. Pingsen Zhao and Lifang Lin prepared the manuscript.

Funding

This study was supported by Medical Scientific Research Foundation of Guangdong Province, China (Grant No.: A2016306 to Dr. Pingsen Zhao), National Key Research and Development Program of China (Grant No.: 2017YFD0501705

to Dr. Pingsen Zhao), National Key Research and Development Program of China (Grant No.: 2016YFD0050405 to Dr. Pingsen Zhao), Natural Science Foundation of Guangdong Province, China (Grant No.: 2016A030307031 to Dr. Pingsen Zhao) and Key Scientific and Technological Project of Meizhou People's Hospital (*Huangtang Hospital*), Meizhou Hospital Affiliated to Sun Yat-sen University, Guangdong Province, China (Grant No.: MPHKTSP-20170102 to Dr. Pingsen Zhao).

Competing Interests

None declared.

Patient Consent

Patient consent is obtained.

Ethics Approval

The study was approved by the Ethics Committee of the Meizhou People's Hospital (*Huangtang Hospital*), Meizhou Hospital Affiliated to Sun Yat-sen University.

References

1. Prefumo F, Sethna F, Sairam S, Bhide A, Thilaganathan B (2005) First-trimester ductus venosus, nasal bones, and Down syndrome in a high-risk population. *Obstet Gynecol* 105: 1348-1354.
2. Ferguson-Smith MA, Yates JR (1984) Maternal age specific rates for chromosome aberrations and factors influencing them: Report of a collaborative european study on 52 965 amniocenteses. *Prenat Diagn* 4: 5-44.
3. Benn PA, Egan JF, Fang M, Smith-Bindman R (2004) Changes in the utilization of prenatal diagnosis. *Obstet Gynecol* 103: 1255-1260.
4. Lo YM, Corbetta N, Chamberlain PF, Rai V, Sargent IL, et al. (1997) Presence of fetal DNA in maternal plasma and serum. *Lancet* 350: 485-487.
5. Benn P, Cuckle H, Pergament E (2012) Genome-wide fetal aneuploidy detection by maternal plasma DNA sequencing. *Obstet Gynecol* 119: 1270.
6. Chiu RW, Akolekar R, Zheng YW, Leung TY, Sun H, et al. (2011) Non-invasive prenatal assessment of trisomy 21 by multiplexed maternal plasma DNA sequencing: Large Scale Validity Study. *BMJ* 342: c7401.
7. McCullough RM, Almasri EA, Guan X, Geis JA, Hicks SC, et al. (2014) Non-invasive prenatal chromosomal aneuploidy testing-clinical experience: 100,000 clinical samples. *PLoS One* 9: e109173.
8. Norton ME, Brar H, Weiss J, Karimi A, Laurent LC, et al. (2012) Non-Invasive Chromosomal Evaluation (NICE) Study: Results of a multi-centre prospective cohort study for detection of fetal trisomy 21 and trisomy 18. *Am J Obstet Gynecol* 207: 137 e1-e8.
9. Yin AH, Peng CF, Zhao X, Caughey BA, Yang JX, et al. (2015) Non-invasive detection of fetal subchromosomal abnormalities by semiconductor sequencing of maternal plasma DNA. *Proc Natl Acad Sci USA* 112: 14670-14675.
10. Srinivasan A, Bianchi DW, Huang H, Sehner AJ, Rava RP (2013) Non-invasive detection of fetal subchromosome abnormalities via deep sequencing of maternal plasma. *Am J Hum Genet* 92: 167-176.
11. Chiu RW, Poon LL, Lau TK, Leung TN, Wong EM, et al. (2001) Effects of blood-processing protocols on fetal and total DNA quantification in maternal plasma. *Clin Chem* 47: 1607-1613.
12. Liao C, Yin AH, Peng CF, Fu F, Yang JX, et al. (2014) Non-invasive prenatal diagnosis of common aneuploidies by semiconductor sequencing. *Proc Natl Acad Sci USA* 111: 7415-7420.
13. Lo KK, Karampetsou E, Boustred C, McKay F, Mason S, et al. (2016) Limited clinical utility of non-invasive prenatal testing for subchromosomal abnormalities. *Am J Hum Genet* 98: 34-44.
14. Fan HC, Quake SR (2010) Sensitivity of non-invasive prenatal detection of fetal aneuploidy from maternal plasma using shotgun sequencing is limited only by counting statistics. *PLoS One* 5: e10439.
15. Cheung SW, Patel A, Leung TY (2015) Accurate description of DNA-based non-invasive prenatal screening. *N Engl J Med* 372: 1675-1677.
16. Yu SC, Jiang P, Choy KW, Chan KC, Won HS, et al. (2013) Non-invasive prenatal molecular karyotyping from maternal plasma. *PLoS One* 8: e60968.
17. Wu Z, Zou X, Zhu W, Mao Y, Chen L, et al. (2016) Minocycline is effective in intracerebral hemorrhage by inhibition of apoptosis and autophagy. *J Neurol Sci* 371: 88-95.