

# Clinical Outcomes of Esthetic and Functional Rehabilitation with Dental Implants in Patients with Alveolar Cleft

Hidemi Nakata<sup>1</sup>, Shinji Kuroda<sup>1\*</sup>, Noriko Tachikawa<sup>1</sup>, Munemitsu Miyasaka<sup>1</sup>, Kenya Yoneda<sup>1</sup>, Hisatomo Kondo<sup>2</sup> and Shohei Kasugai<sup>1</sup>

<sup>1</sup>Department of Oral Implantology and Regenerative Dental Medicine, Division of Oral Health Sciences, Graduate School of Medical and Dental Sciences, Tokyo Medical and Dental University, Tokyo, Japan

<sup>2</sup>Prosthodontics and Implant Dentistry, Iwate Medical University, Iwate, Japan

## Abstract

**Background and aim:** Alveolar cleft is notable congenital deformity in the oral and maxillofacial region. And missing incisor is often associated with the cleft site. Owing to recent advances in bone grafting techniques, dental implant treatment has become an appreciable method of restoring the edentulous space at the cleft site in addition to conventional methods using bridges or dentures. In this study, we investigated the risk factors related to esthetic outcomes of implant treatment at alveolar cleft sites.

**Materials and methods:** A total of 13 patients treated with dental implants for missing teeth associated with an alveolar cleft were examined. The patients' gender, cleft type, and number of dental implants were recorded. The ages of patients at bone grafting for cleft closure, additional bone grafting prior to dental implant surgery, and dental implant placement were also investigated. Seven risk factors were assessed to evaluate the relation to esthetic outcomes.

**Results:** Five to thirteen years after the final prostheses were delivered, neither marginal bone resorption nor loss of dental implants were found. The esthetic outcomes differed among patients according to several risk factors.

**Discussion and conclusion:** Oral rehabilitation with dental implants represented a promising treatment for alveolar cleft sites when bone graft was appropriate. However, the esthetic outcomes of this treatment depend upon multiple risk factors.

**Keywords:** Alveolar cleft; Aesthetics; Secondary bone graft

## Introduction

The frequency of cleft lip and palate (CLP) among Asians is approximately one in every 500 newborns, which is higher than the incidence among Caucasians or Africans (one in 800–1000 newborns) [1]. Patients with CLP frequently associate a missing incisor at the cleft site. To restore the edentulous space and achieve esthetic and functional rehabilitation after orthodontic treatment, conventional prosthodontic treatment, such as bridges or dentures, is chosen more frequently than implant treatment. This is because prosthodontic treatment retains the expanded dental arch with a fixed prosthesis between the bilateral premolars, even when the alveolar cleft is unilateral [2,3]. Although implant treatment is not always suitable in these patients because of a lack of available bone, recent advances in surgery, including secondary bone grafting (SBG) and improved orthodontic techniques, has increased the eligibility of these patients for the placement of dental implants at the cleft sites [4]. Furthermore, preparation of adjacent healthy teeth is not required for implant treatment [5]. In this report, we investigated the timing of bone grafting for cleft closure and dental implant placement at cleft sites and evaluated the risk factors associated with the esthetic outcomes of this regenerative treatment.

## Materials and Methods

This study was performed with the approval of and adherence to the guidelines of Tokyo Medical and Dental University, Tokyo, Japan (Approval Number: 1150).

## Patients

We evaluated 13 patients who were treated with dental implants for missing teeth associated with an alveolar cleft at the Implant Clinic of the Dental Hospital at Tokyo Medical and Dental University between

Type of Clefts	r-s	l-s	Bilateral	Total
Male	1	3	1	5
Female	0	6	2	8
Total	1	9	3	13

r-s: right side

l-s: left side

**Table 1:** Description of the 13 patients evaluated in the present study.

2002 and 2010. Of the 13 individuals studied, eight were women, and five were men. Three had a bilateral and 10 had a unilateral cleft lip, alveolus, and palate (Table 1). The dental implant evaluated in this study was 16 in total.

## Ages at bone grafting and implant placement

All patients except one had undergone bone grafting to close the alveolar cleft with autologous trabecular bone harvested from the iliac crest (SBG) between the ages of 11 and 28, and the mean age was 19. Two underwent additional bone grafting prior to implant placement. The patients' ages ranged from 18 to 36 years, and the mean age was 23 years at the time of dental implant placement (Figure 1).

**\*Corresponding author:** Shinji Kuroda, Tokyo Medical and Dental University, 1-5-45 Yushima, Bunkyo-ku, Tokyo 113-8510, Japan, Tel: +813 5803 4656; E-mail: [skuroda.mfc@tmd.ac.jp](mailto:skuroda.mfc@tmd.ac.jp)

**Received** November 24, 2015; **Accepted** December 18, 2015; **Published** December 28, 2015

**Citation:** Nakata H, Kuroda S, Tachikawa N, Miyasaka M, Yoneda K, et al. (2015) Clinical Outcomes of Esthetic and Functional Rehabilitation with Dental Implants in Patients with Alveolar Cleft. J Tissue Sci Eng 6: 160. doi:10.4172/2157-7552.1000160

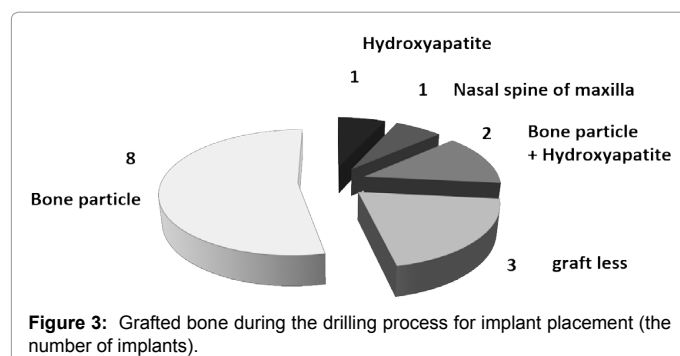
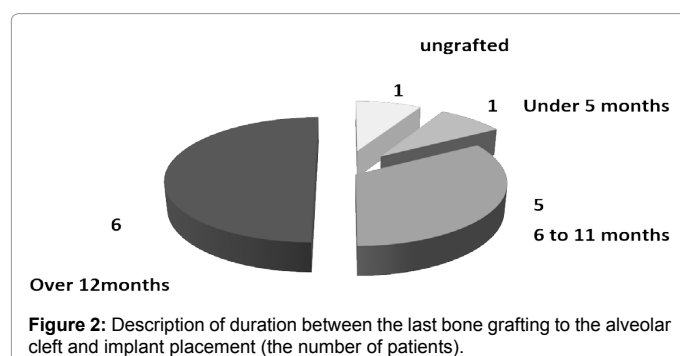
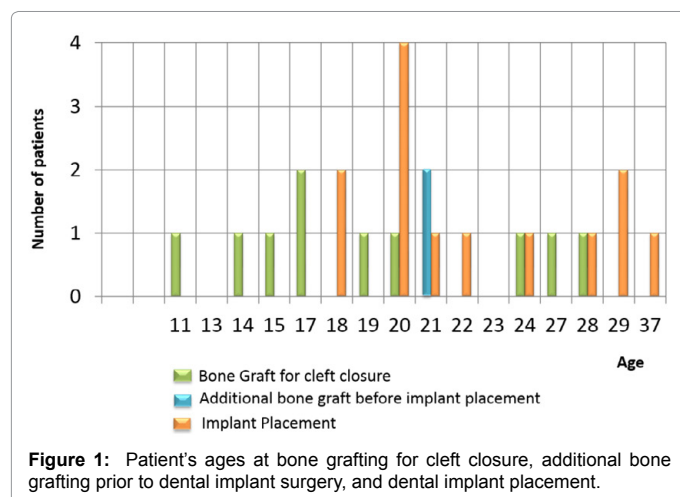
**Copyright:** © 2015 Nakata H, et al. This is an open-access article distributed under the terms of the Creative Commons Attribution License, which permits unrestricted use, distribution, and reproduction in any medium, provided the original author and source are credited.

## Interval between the last bone graft and implant placement

In most patients (11/13), dental implants were installed at least 6 months after the last bone graft at the cleft sites. One patient did not undergo any bone grafting before implant placement, and one patient had dental implants installed 5 months after the last bone graft (Figure 2).

## Bone grafting for implant surgery

Even though the time elapsed from the last bone graft at the cleft sites until implant placement was over 6 months in most patients, the grafted bone remained, and all implants were completely covered by host/grafted bone, with or without added bone substitute or bone particles obtained during drilling for implant placement. Notably, three patients did not require any bone grafting during implant placement (Figure 3). Hydroxyapatite allografts (Calcitite®, HAKUHO, Japan, Tokyo) were used in three patients.



## Risk factors

We evaluated the bone level of the adjacent teeth based on Enemark's protocol[6] which were reported as a method to evaluate the marginal bone level after SBG. Risk factors such as lip line, length from the nasal floor to the alveolar ridge, width of the edentulous span, gingival margin of the adjacent teeth, gingival biotype, status of the adjacent teeth, score of the marginal bone level of the adjacent teeth (Enemark's Score), and cleft types (bilateral;BCLP or unilateral;UCLP) [7] were evaluated, and designated as "high risk" or "low risk" depending on their effect on esthetic outcomes (Figures 4 and 5).

## Results

### Clinical outcomes

No dental implants were lost in 5 to 13 years after final restoration. Bone resorption around the fixture did not observed. All patients were satisfied the esthetic and functional results of dental implant treatment.

### Risk factors

The allocations of the 13 patients are; 2 cases with only low-risk factors, 8 cases with a high-risk factor, a case with 3 high-risk factors, and a case with 4 high-risk factors, respectively at the timing of implant placement.

The clinical result of 2 patients with no high-risk factors showed good esthetic outcomes (Figure 6). Although they used to be with a high-risk factor in the width of edentulous span, orthodontic treatment made them low-risk (Figure 6). A case with 2 high-risks in the length from nasal floor to alveolar ridge and gingival margin of next teeth received an additional bone grafting prior to implant placement (Figure 7D-7I). This process made this case be only with 1 high-risk, and facilitated the installation of a dental implant (Figures 8A-8F). Although the esthetic outcomes of 8 patients with a high-risk factor showed slightly inferior to no high-risk group, it was satisfactory (Figure 9-11). The value of esthetic outcomes was not varied among the different types of risk factors. In contrast, the esthetic outcomes of 2 patients with 3 high-risk factors and 2 patients with 4 high-risk factors were inferior to other groups (Figure 12 and 13). It suggested that an increased number of high-risk factors related to a poorer esthetic outcome

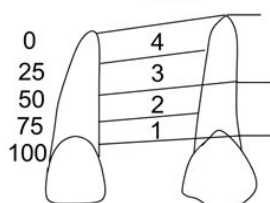
## Discussion and Conclusion

In the present investigations, all cleft sites except one received bone graft from the iliac crest, and in most patients, dental implants were installed at least 6 months after the last bone graft. Although bone grafting for closure of the cleft was performed between 9 and 11 years of age and placement of the dental implants was performed after 20 years of age in most patients, only two patients needed additional grafting from the iliac crest at the cleft sites to facilitate implant placement; in most patients, the implant fixture was covered by bone substitute or bone particles obtained during the drilling process. According to the clinical results of the present investigations, it was suggested that if the bone grafting has performed appropriately, the treatment using dental implants can be efficient for the patients those who have alveolar clefts.

However, compared with the normal jaw, the cleft jaw has considered to be less suited for dental implant treatment and the esthetic outcomes are more variable [8]. To overcome the limitations, it is important to regard and screen the risk factors to imagine the clinical outcomes. Thus, in this study, we investigated several risk factors related to the esthetic outcomes of the treatment of missing teeth associated with alveolar cleft. Our results suggest that the esthetic outcomes may

Prognosis Relevant Factor	Low Risk	High Risk
Lip line	Low	High
Length from nasal floor to alveolar ridge	Over 10mm	Under 10mm
Width of edentulous span	Appropriate for 1 tooth	2 teeth or more, under 1 tooth
Score for marginal bone level of canine. (Enemark H et al )	1	2,3,4
Gingival margin of next teeth	Low scalloped	High scalloped
Gingival bio type	thick	thin
Status of adjacent teeth	healthy	malposition

Score





Scores for marginal bone level assessed on X-ray film , quoted from Enemark (1987)

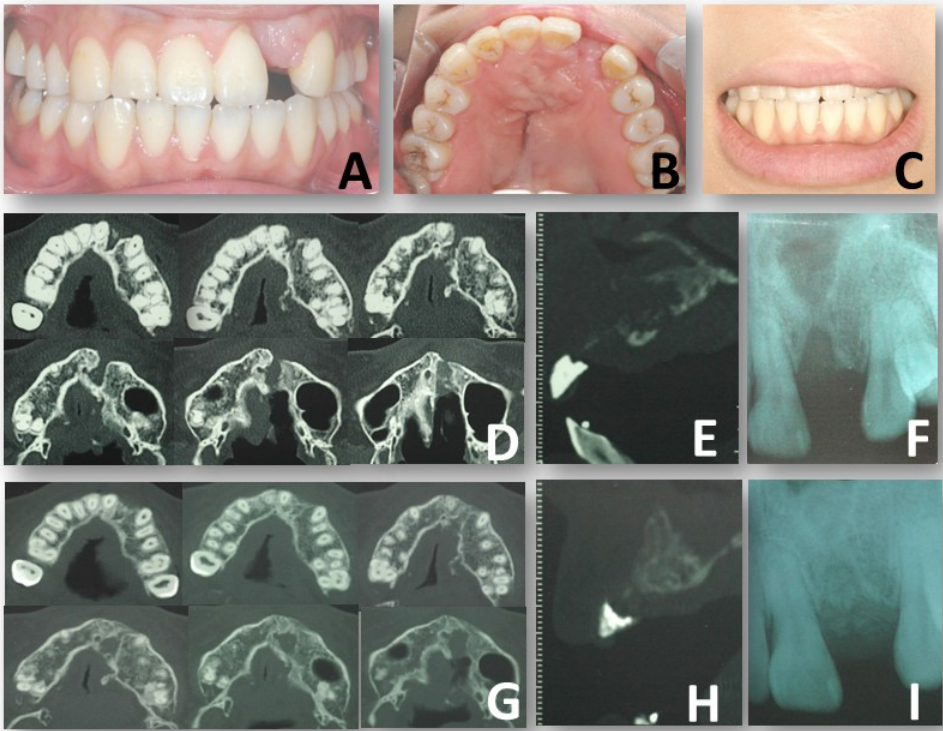**Figure 4** Left: Risk factors related to the esthetic outcomes of the treatment of missing teeth associated with alveolar cleft. Right: Scores of marginal bone level of adjacent tooth assessed on X-ray film.

Prognosis Relevant factor	High Risk	Esthetic outcomes
Lip line	High	visible externally
Length from nasal floor to alveolar ridge	Under 10mm	difficulty in installing implant
Width of edentulous span	2 teeth or more, under 1 tooth	unnatural in shape or size of the tooth
Score for marginal bone level of adjacent teeth	2,3,4	long shape of the tooth
Gingival margin of next teeth	High scalloped	disharmony of the maginal line between adjacent teeth
Gingival bio type	thin	the metal can be seen through the mucosa
Status of adjacent teeth	malposition	unnatural in shape or size of the tooth
Cleft type	bilateral	disharmony between the central and the lateral incisor

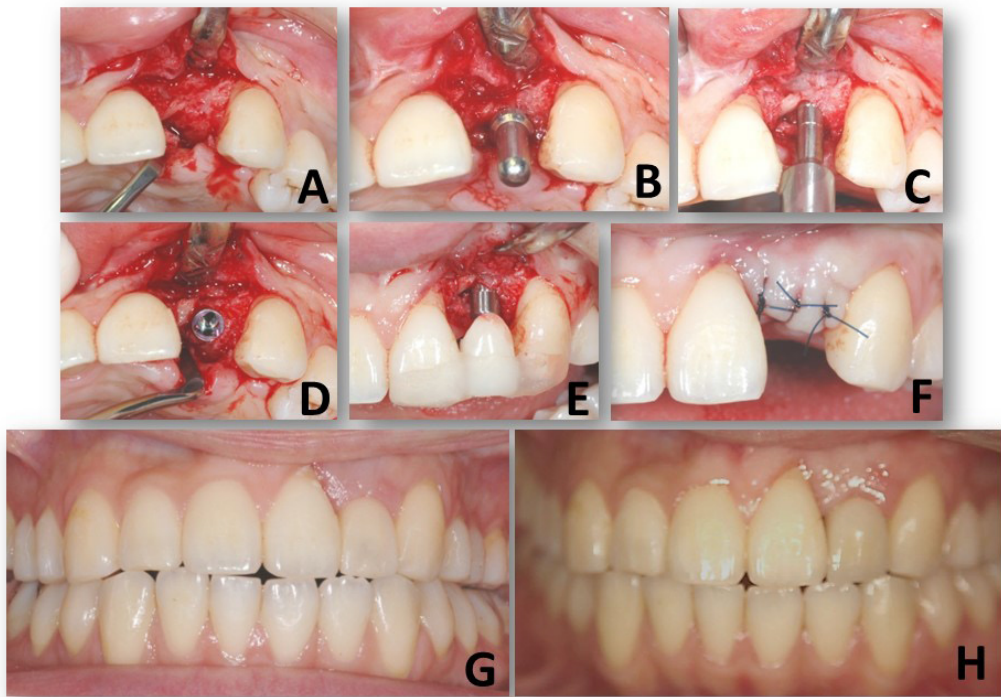
**Figure 5:** Anticipated results of associated risk factors.

Prognosis Relevant factor	Low Risk	High Risk	
Lip line	Low	High	
Length from nasal floor to alveolar ridge	Over 10mm	Under 10mm	
Width of edentulous span	Appropriate for 1 tooth	2 teeth or more, under 1 tooth	
Score for marginal bone level of adjacent teeth	1	2,3,4	
Gingival margin of next teeth	Low scalloped	High scalloped	
Gingival bio type	thick	thin	
Status of adjacent teeth	helthy	malposition	
Cleft type	unilateral	bilateral	

**Figure 6:** Patients without high-risk factor showed good esthetic outcomes. Upper: left-side UCLP accompany with missing of left first and second incisor. A dental implant has installed at the first incisor subsequent to orthodontic treatment to adjust the edentulous space to appropriate for 1 tooth. Lower: left-side UCLP accompany with missing of left second incisor.



**Figure 7:** Description of preoperative diagnosis of a patient with a high-risk factor. The gingival margin of the adjacent tooth showed high scalloped triangle shape compare to the opposite side (A). The width of the edentulous span was appropriate for a tooth (B). The patient has low lip line (C). Computed tomography (CT) before (D, E) and after (G, H) bone grafting for cleft closure. Dental X-ray for evaluation of marginal bone level of adjacent tooth (before bone grafting: F, after bone grafting: I)




**Figure 8:** Surgical process of dental implant placement of the patient (A-F). Provisional restoration (G) and final prosthesis (H) of the dental implant treatment.

Prognosis Relevant factor	Low Risk	High Risk
Lip line	Low	High
Length from nasal floor to alveolar ridge	Over 10mm	Under 10mm
Width of edentulous span	Appropriate for 1 tooth	2 teeth or more, under 1 tooth
Score for marginal bone level of adjacent teeth	1	2,3,4
Gingival margin of next teeth	Low scalloped	High scalloped
Gingival bio type	thick	thin
Status of adjacent teeth	helthy	malposition
Cleft type	unilateral	bilateral


**Figure 9:** Esthetic outcomes of patients with a high-risk factor on the gingival margin of next teeth. Upper: left-side UCLP accompany with missing of left second incisor (Figure 7 and 8). Lower: left-side UCLP accompany with missing of left second incisor. The gingival margin showed high scalloped shape on the edentulous site.

Prognosis Relevant factor	Low Risk	High Risk
Lip line	Low	High
Length from nasal floor to alveolar ridge	Over 10mm	Under 10mm
Width of edentulous span	Appropriate for 1 tooth	2 teeth or more, under 1 tooth
Score for marginal bone level of adjacent teeth	1	2,3,4
Gingival margin of next teeth	Low scalloped	High scalloped
Gingival bio type	thick	thin
Status of adjacent teeth	helthy	malposition
Cleft type	unilateral	bilateral





**Figure 10:** Appearance after dental implant treatment for the patient with a high-risk factor on the width of edentulous span. Upper: Front view of the final prosthesis. Lower: Occlusal view after final restoration.



Prognosis Relevant factor	Low Risk	High Risk
Lip line	Low	High
Length from nasal floor to alveolar ridge	Over 10mm	Under 10mm
Width of edentulous span	Appropriate for 1 tooth	2 teeth or more, under 1 tooth
Score for marginal bone level of adjacent teeth	1	2,3,4
Gingival margin of next teeth	Low scalloped	High scalloped
Gingival bio type	thick	thin
Status of adjacent teeth	helthy	malposition
Cleft type	unilateral	bilateral



**Figure 11:** Clinical results of dental implant treatment of the patients with bilateral alveolar clefts. Since the block of the first incisors and its surrounding bone have been isolated from the alveolus bone of the maxilla, reconstruction of the front block of the alveolus bone is more complicated.

Prognosis Relevant factor	Low Risk	High Risk	
Lip line	Low	High	
Length from nasal floor to alveolar ridge	Over 10mm	Under 10mm	
Width of edentulous span	Appropriate for 1 tooth	2 teeth or more, under 1 tooth	
Score for marginal bone level of adjacent teeth	1	2,3,4	
Gingival margin of next teeth	Low scalloped	High scalloped	
Gingival bio type	thick	thin	
Status of adjacent teeth	helthy	malposition	
Cleft type	unilateral	bilateral	

**Figure 12:** A case with three high-risk factors. The score for marginal bone level was 2 on the adjacent tooth. The gingival margin of the adjacent tooth showed high scalloped shape. And the gingival biotype was thin.

Prognosis Relevant factor	Low Risk	High Risk	
Lip line	Low	High	
Length from nasal floor to alveolar ridge	Over 10mm	Under 10mm	
Width of edentulous span	Appropriate for 1 tooth	2 teeth or more, under 1 tooth	
Score for marginal bone level of adjacent teeth	1	2,3,4	
Gingival margin of next teeth	Low scalloped	High scalloped	
Gingival bio type	thick	thin	
Status of adjacent teeth	helthy	malposition	
Cleft type	unilateral	bilateral	

**Figure 13:** The aesthetic outcomes of the patients with four high-risk factors. The score of the marginal bone level were 2, they have high scalloped gingival shape, thin gingival bio type, and malposition of the adjacent tooth.

depend on the number of risk factors present rather than which risk factor is involved in high risk. Our findings also suggest that physicians may be able to predict the outcomes of dental implant treatment in these patients by evaluating these risk factors beforehand.

Bone defects associated with alveolar cleft can often be large, meaning that bone height and alveolar ridge width are often insufficient for dental implant placement. Bone grafting has been shown to increase bone volume remarkably for implant stability at the grafted sites [9-11]. Since these bone defects are large, trabecular bone from the iliac crest is mainly used for cleft closure at present [12]. However, although bone grafting for dental implant placement was demonstrated efficient in the present study, the procedure of harvesting marrow from the iliac bone is invasive and may bring suffering such as pain after surgery [13-15]. In addition, it has been reported that trabecular bone may be resorbed by time after surgery [14,16]. Indeed, additional bone grafting for implant placement was necessary in two patients who had already undergone bone graft several years before for the first time, which implies bone resorption after the original graft [17-19].

Recent advances in stem cell therapy may yield a novel protocol for bone regeneration applicable to bone defects associated with an alveolar cleft [20-24]. This approach may be less invasive and more natural than conventional autologous bone grafting [25-28]. Tissue regeneration using stem cells may provide useful methods for cleft closure and it can replace the conventional invasive procedure in the future [29-31].

## Acknowledgements

We would like to express their appreciation to Dr. Hidemi Yoshimasu, associate professor at the Maxillofacial Surgery, Tokyo Medical and Dental University, Tokyo, Japan, for the surgical procedure of SBG. We would also like to thank Dr. Michiko Suzuki, research assistant in the Department of Oral Implantology and Regenerative Dental Medicine, Tokyo Medical and Dental University, Tokyo, Japan.

## References

- Lei RL, Chen HS, Huang BY, Chen YC, Chen PK, et al. (2013) Population-based study of birth prevalence and factors associated with cleft lip and/or palate in Taiwan 2002-2009. *PLoS One* 8: e58690.
- Friede H, Enemark H (2001) Long-term evidence for favorable midfacial growth after delayed hard palate repair in UCLP patients. *Cleft Palate Craniofac J* 38: 323-329.
- Acharya V, Brecht LE (2014) Conventional prosthodontic management of partial edentulism with a resilient attachment-retained overdenture in a patient with a cleft lip and palate: a clinical report. *J Prosthet Dent* 112: 117-121.
- Hidemi Nakata SK, Noriko Tachikawa, Tomoko Nagayama, Shohei Kasugai (2014) Aesthetical reconstruction of an anterior tooth in an alveolar cleft site: A case report and 3-year follow-up findings. *Journal of Oral Implantology*. DOI: 10.5163/AAID-JOI-D-14-00042.
- Landes, CA, Lukas B, Katharina L, Sharam G, Robert S, et al. (2012) Patient satisfaction after prosthetic rehabilitation of bone-grafted alveolar clefts with nonsubmerged ITI Straumann dental implants loaded at three months. *Cleft Palate Craniofac J* 49: 601-608.
- Enemark H, Sindet-Pedersen S, Bundgaard M, Simonsen EK (1988) Combined orthodontic-surgical treatment of alveolar clefts. *Ann Plast Surg* 21: 127-133.
- Bittermann GK, de Ruiter AP, Janssen NG, Bittermann AJ, van der Molen AM, et al. (2015) Management of the premaxilla in the treatment of bilateral cleft of lip and palate: what can the literature tell us? *Clin Oral Invest* .
- Filho JF, de Almeida AL (2013) Aesthetic analysis of an implant-supported denture at the cleft area. *Cleft Palate Craniofac J* 50: 597-602.
- Guerrero CA (2012) Cleft lip and palate surgery: 30 years follow-up. *Ann Maxillofac Surg* 2: 153-157.
- Semb G (2012) Alveolar bone grafting. *Front Oral Biol* 16: 124-136.
- Wermker K, Jung S, Joos U, Kleinheinz J (2014) Dental implants in cleft lip, alveolus, and palate patients: a systematic review. *Int J Oral Maxillofac Implants* 29: 384-390.
- Vura N, Reddy KR, R S, G R, Kaluvala VR (2013) Donor site evaluation: anterior iliac crest following secondary alveolar bone grafting. *J Clin Diagn Res* 7: 2627-2630.
- Theologie-Lygidakis N, Chatzidimitriou K, Tzerbos F, Kolomvos N, Iatrou I (2014) Development of surgical techniques of secondary osteoplasty in cleft patients following 12 years experience. *J Craniomaxillofac Surg* 42: 839-845.
- Matsa S, Murugan S, Kannadasan K (2012) Evaluation of morbidity associated with iliac crest harvest for alveolar cleft bone grafting. *J Maxillofac Oral Surg* 11: 91-95.
- Baqain ZH, Anabtawi M, Karaky AA, Malkawi Z (2009) Morbidity from anterior iliac crest bone harvesting for secondary alveolar bone grafting: an outcome assessment study. *J Oral Maxillofac Surg* 67: 570-575.
- Raposo-Amaral, Cesar A, Denadai, Rafael, Chammas, et al. (2015) Cleft Patient-Reported Postoperative Donor Site Pain Following Alveolar Autologous Iliac Crest Bone Grafting: Comparing Two Minimally Invasive Harvesting Techniques. *J Craniofac Surg*. 26: 2099-2103.
- Schultze-Mosgau S, Nkenke E, Schlegel AK, Hirschfelder U, Wiltfang J (2003) Analysis of bone resorption after secondary alveolar cleft bone grafts before and after canine eruption in connection with orthodontic gap closure or prosthodontic treatment. *J Oral Maxillofac Surg* 61: 1245-1248.
- Nagashima H, Sakamoto Y, Ogata H, Miyamoto J, Yazawa M, et al. (2014) Evaluation of bone volume after secondary bone grafting in unilateral alveolar cleft using computer-aided engineering. *Cleft Palate Craniofac J* 52: 336-340.
- Feichtinger M, Mossböck R, Kärcher H (2006) Evaluation of bone volume following bone grafting in patients with unilateral clefts of lip, alveolus and palate using a CT-guided three-dimensional navigation system. *J Craniomaxillofac Surg* 34: 144-149.
- Yamamoto M, Nakata H, Hao J, Chou J, Kasugai S, et al. (2014) Osteogenic Potential of Mouse Adipose-Derived Stem Cells Sorted for CD90 and CD105 In Vitro. *Stem Cells Int* 2014: 576358.
- Van Hout, Wouter MM, Aebale B, Corstiaan CB, Ronald K, et al. (2011) Reconstruction of the alveolar cleft: can growth factor-aided tissue engineering replace autologous bone grafting? A literature review and systematic review of results obtained with bone morphogenetic protein-2. *Clin Oral Invest* 15: 297-303.
- Toshiharu S, Goki M (2015) First Report of Histological Evaluation of Human Tissue-Engineered Vasculature. *Journal of Biotechnology & Biomaterials* 05. DOI: 10.4172/2155-952x.1000200
- Miyasaka M, Nakata H, Hao J, Kim YK, Kasugai S, et al (2015) Low-Intensity Pulsed Ultrasound Stimulation Enhances Heat-Shock Protein 90 and Mineralized Nodule Formation in Mouse Calvaria-Derived Osteoblasts. *Tissue Eng Part A* 21: 2829-2839
- GŁadysz D, Hozyasz KK (2015) Stem cell regenerative therapy in alveolar cleft reconstruction. *Arch Oral Biol* 60: 1517-1532.
- Oryan A, Alidadi S, Moshiri A, Maffulli N (2014) Bone regenerative medicine: classic options, novel strategies, and future directions. *J Orthop Surg Res* 9: 18.
- Kim YK, et al., Osteogenic Potential of Mouse Periosteum-derived Cell Sorted for CD90 in vitro and in vivo. *STEM CELLS TRANSLATIONAL MEDICINE* 2015. 1. in press
- Janssen N, Willem LJW, Ronald K, Antoine JWPR, Gert JM (2014) Tissue engineering strategies for alveolar cleft reconstruction: a systematic review of the literature. *Clinical Oral Investigations* 18: 219-226.
- Brochhausen C, James K (2012) An Evolutionary View on Guided Tissue Engineering—from the Replacement to the Regeneration of Damaged Tissue. *Journal of Tissue Science & Engineering* 3:e117
- Yi Chien Lin, J.M.C (2014) Stem Cell Therapy: Are we Ready to use it? *Journal of Tissue Science & Engineering*, 05: DOI: 10.4172/2157-7552.1000136
- Padial-Molina M, O'Valle F, Lanis A, Mesa F, Dohan Ehrenfest DM, et al. (2015) Clinical Application of Mesenchymal Stem Cells and Novel Supportive Therapies for Oral Bone Regeneration. *Biomed Res Int* 2015: 341327.
- Gordeladze JO (2012) Engineering of Osteoblasts for Bone Replacement: How to Test for Acquisition and Maintenance of a Proper Phenotype. *Journal of Tissue Science & Engineering* 3:e134 DOI: 10.4172/2157-7552.1000e114.