

# Clinical Characteristics and Treatment Experiences in 2 Serious Cases of Influenza A (H5N6) Virus Infection

Jian Liao<sup>1,2#</sup>, Xi Liu<sup>2,3#</sup>, Jianming Li<sup>2</sup>, Lijiao Zeng<sup>2</sup>, Zheng Yang<sup>4</sup>, Jing Yuan<sup>2\*</sup> and Boping Zhou<sup>2,5\*</sup>

<sup>1</sup>Department of Infectious Diseases, Shenzhen Third People's Hospital, University of South China, Shenzhen, P.R China

<sup>2</sup>Department of Infectious Diseases, Shenzhen Third People's Hospital, Guangdong Medical University, Shenzhen, P.R China

<sup>3</sup>Department of Infectious Diseases, The Fifth Affiliated Hospital, Sun Yat-sen University, Zhuhai, P.R China

<sup>4</sup>Guangdong Key Lab for Diagnosis and Treatment of Emerging Infectious Diseases, Shenzhen Key Lab of Infection and Immunity, Shenzhen Third People's Hospital, Guangdong Medical University, Shenzhen, P.R China

<sup>5</sup>Longhua Branch of Shenzhen People's Hospital, Shenzhen, P.R China

#Equally Contributed

## Abstract

Since April 2014, a fatal human infection with a novel reassortant H5N6 avian influenza virus was identified in China. Eight of 10 patients died from this virus. Two H5N6 patients were hospitalized in Shenzhen Third People's Hospital in China, with one patient recovered. Here, we describe their clinical characteristics and treatment strategies. We suggest these strategies in the early stage may be important for severe avian influenza patients, including early combined antiviral therapy, oxygen therapy and ventilator support treatment, short-term usage of low-dose corticosteroid and appropriate immune globulin and keeping negative fluid balance in the progression period.

**Keywords:** Avian influenza A viruses; H5N6; Treatment strategy

## Introduction

The threat posed by avian influenza A viruses to humans remains significant because these viruses have raised sporadic human infections and have undergone gene evolution and potential reassortment with

human viruses [1]. Of these viruses, H5N1 and the more recently emerged H7N9 in China have raised global concerns because of high mortality [2]. Since April 2014, a fatal human infection with a novel reassortant H5N6 avian influenza virus was first identified in Sichuan province of China. A total of nine H5N6 infected cases were identified so far in China, of which 3 cases were reported in Shenzhen city of Guangdong province. Among 10 cases, 8 cases died, and the mortality rate was 80.0%. Two cases were treated in our hospital, and one case was cured. We herein summarize the preliminary findings of these two cases, including clinical features and treatment experience, which may help us to understand the natural history and full spectrum of H5N6 infection.

## Case Reports

### Case 1

A 25-year-old man developed initial symptoms of fever (the highest axillary temperature almost to 39.5°C) and cough on January 1, 2016. The initial symptoms were not relieved by taking some antifebriles, and then other symptoms developed, including chest pain, shortness of breath, and blood-tinged sputum. On January 4, he was hospitalized in the Department of Emergency Medicine in Shenzhen Third People's Hospital, and received cefoperazone-sulbactam treatment. On January 6, he had developed type 1 respiratory failure. Oseltamivir was added to the previous antibiotic treatment. A throat-swab sample was tested with a positive result of H5N6 virus. He was transferred to the Department of Infectious Disease for further treatment at the night of January 6. He

	Patient 1	Patient 2
<b>Laboratory results on admission</b>		
Leukocyte count, ×10 <sup>9</sup> /L	7.8	22.99
Neutrophil count, ×10 <sup>9</sup> /L	6.76	21.29
Lymphocyte count, ×10 <sup>9</sup> /L	0.79	0.84
Red blood cell count, ×10 <sup>12</sup> /L	5.68	2.98
Platelet count, ×10 <sup>9</sup> /L	199	185
TH-COUNT, cells/μL	82	152
TS-COUNT, cells/μL	71	265
PT, second	14	1.22
APTT, second	42.1	2.17
D-Dimer, μg/mL	1.36	8.5
ALB, g/L	39.9	46.3
ALT, U/L	35.8	70
AST, U/L	66.4	98
LDH, U/L	532	1283
CK, U/L	1082	529
Creatinine, μmol/L	79	127
CRP, mg/L	89.53	31
PCT, ng/mL	0.333	0.4
<b>Complications</b>		
Septic shock	No	Yes
ARDS	Yes	Yes
Acute renal damage	No	Yes
Encephalopathy	No	No
Rhabdomyolysis	No	No
Secondary infections	Yes	Yes
Outcome	Discharged 21 d after illness onset	Died 31 d after illness onset

TH-COUN: Helper T Cells Count; TS-COUNT: Suppressor T Cells Count; PT: Prothrombin Time; APTT: Activated Partial Prothrombin Time; ALB: Albumin; ALT: Alanine Aminotransferase; AST: Aspartate Aminotransferase; LDH: Lactate Dehydrogenase; CK: Creatine Kinase; CRP: C-Reactive Protein; PCT: Procalcitonin; ARDS: Acute Respiratory Distress Syndrome

**Table 1:** Characteristics of 2 patients infected with avian influenza A(H5N6) virus, Shenzhen, China.

\*Corresponding authors: Boping Zhou, Department of Infectious Diseases, Shenzhen Third People's Hospital, Guangdong Medical University, Shenzhen, 518112, P.R China, Tel: +86 755 8336 6388; E-mail: [zhoubp@hotmail.com](mailto:zhoubp@hotmail.com)

Jing Yuan, Department of Infectious Diseases, Shenzhen Third People's Hospital, Guangdong Medical University, Shenzhen, 518112, P.R China, Tel: +86 20 8134 0448; E-mail: [13500054798@139.com](mailto:13500054798@139.com)

Received November 22, 2016; Accepted December 15, 2016; Published December 21, 2016

**Citation:** Liao J, Liu X, Li J, Zeng L, Yang Z, et al. (2016) Clinical Characteristics and Treatment Experiences in 2 Serious Cases of Influenza A (H5N6) Virus Infection. J Clin Case Rep 6: 897. doi: [10.4172/2165-7920.1000897](https://doi.org/10.4172/2165-7920.1000897)

**Copyright:** © 2016 Liao J, et al. This is an open-access article distributed under the terms of the Creative Commons Attribution License, which permits unrestricted use, distribution, and reproduction in any medium, provided the original author and source are credited.

had a close contact with live poultry. He had no underlying medical conditions.

On admission, the blood biochemistry tests are summarized in Table 1. A chest radiography suggested pneumonia in left lower lobe. On January 4, rapid improvement of both lung consolidation showed in the computed tomographic (CT) scan on 6 February. Dynamic changes of bilateral lung on CT scan are shown in Figure 1B-1E.

The patient was daily administrated antiviral drugs (Oseltamivir 300 mg by mouth, peramivir 300 mg by IV and zanamivir 20 mg by oxygen atomizing inhalation), noninvasive ventilation with 40% oxygen, methylprednisolone 120 mg by IV, gamma-globulin 15 g by IV, albumin 10 g by IV and antibiotics. After his condition stabilized on January 10, the dose of methylprednisolone was decreased gradually. In addition, the fluid management strategies were undertaken, as shown in Table 2. On January 12, the throat-swab sample was negative for H5N6 virus (Figure 1A). After 17 days hospitalization, He was recovered and discharged on January 22, 2016.

### Case 2

A 31-year-old woman complained of 6-day history of fever, cough, and 3-day history of chest tightness and shortness of breath. She was hospitalized in Futian District People's Hospital in Shenzhen on

January 14, and confirmed as H5N6 infection the next day. She was daily administrated antiviral drugs (oseltamivir, zanamivir and peramivir), methylprednisolone, gamma-globulin, broad-spectrum antibiotics, invasive ventilator support and continuous renal replacement therapy. However, her condition persistently deteriorated. She developed severe shortness of breath, weakness, poor appetite, anuria and coma because of progression to severe pneumonia with pleural effusion, acute respiratory distress syndrome (ARDS), septic shock and multiple organ dysfunction syndrome (MODS).

On January 25, she was transferred to Shenzhen Third People's Hospital. The laboratory results on admission are summarized in Table 1. Dynamic changes of bilateral lung on chest radiograph are shown in Figure 2B-2E. The patient was daily administrated antiviral drugs (oseltamivir 300 mg by mouth, peramivir 300 mg by IV), ventilator support, methylprednisolone 30 mg, gamma-globulin 15 g, albumin 10 g and antibiotics. In addition, the fluid management strategies were undertaken, as shown in Table 2. From January 27, she began to present with hyperthermia; her body temperature increased from 35°C to 37°C. After consecutive negative result of H5N6 detection, she was transferred to the Intensive Care Unit on February 5. She died of acute respiratory distress syndrome (ARDS) and MODS 3 days later (Figure 2A).

### Discussion

A novel highly pathogenic avian influenza H5N6 virus with the backbone of H5N1 virus and an acquired NA gene from H6N6 virus was first identified in 2014 in China [3]. The clinical presentation and laboratory indices of the H5N6 patients at hospital admission are similar with H5N1 patients [4]. We have a wealth of experience on treatment of patients severely infected with influenza virus. Since December, 2013, a total of 38 H7N9 confirmed cases visited to our hospital, including 37 hospitalized patients and a 6-year-old boy with mild condition isolated and treated at home. Among the 38 patients, only 5 patients died. The mortality (5/38, 13%) was much lower than the national mortality (272/657, 41.4%) (<http://www.nhfpc.gov.cn/zhuozhan/yqxx/lists.shtml> China CDC). Our treatment strategies are summarized as four aspects: (I) early combined antiviral therapy; (II)

Hospitalization time	Patient 1			Patient 2		
	Intake	Output	Intake-output	Intake	Output	Intake-output
Day 1	630	1112	-482	1164	1140	24
Day 2	2729	3329	-600	2941	1915	1026
Day 3	2692	2855	-166	3695	3151	544
Day 4	3006	2989	17	3425	3317	108
Day 5	2538	2435	103	3536	3563	-27
Day 6	2368	2963	-595	4365	4390	-25
Day 7	2154	1618	536	3594	3446	148

Table 2: 24 hours intake and output volume of liquid in the first week after admission (ml).

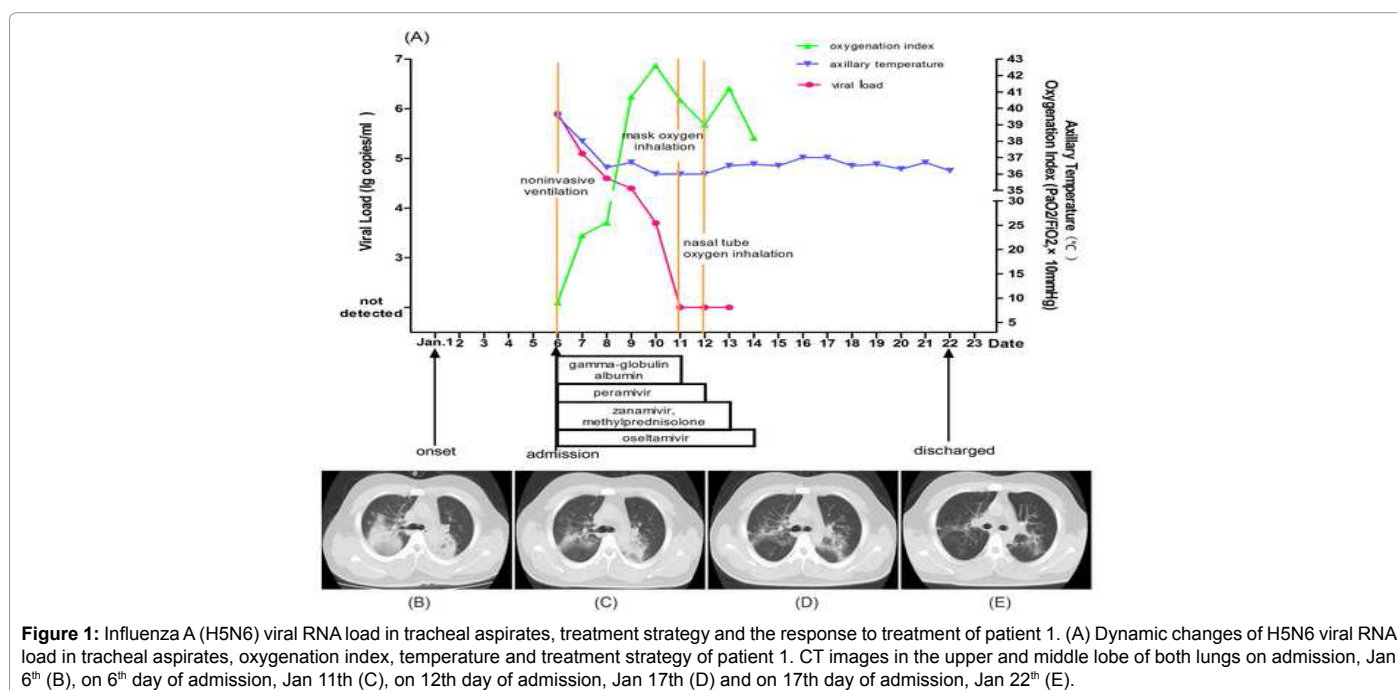
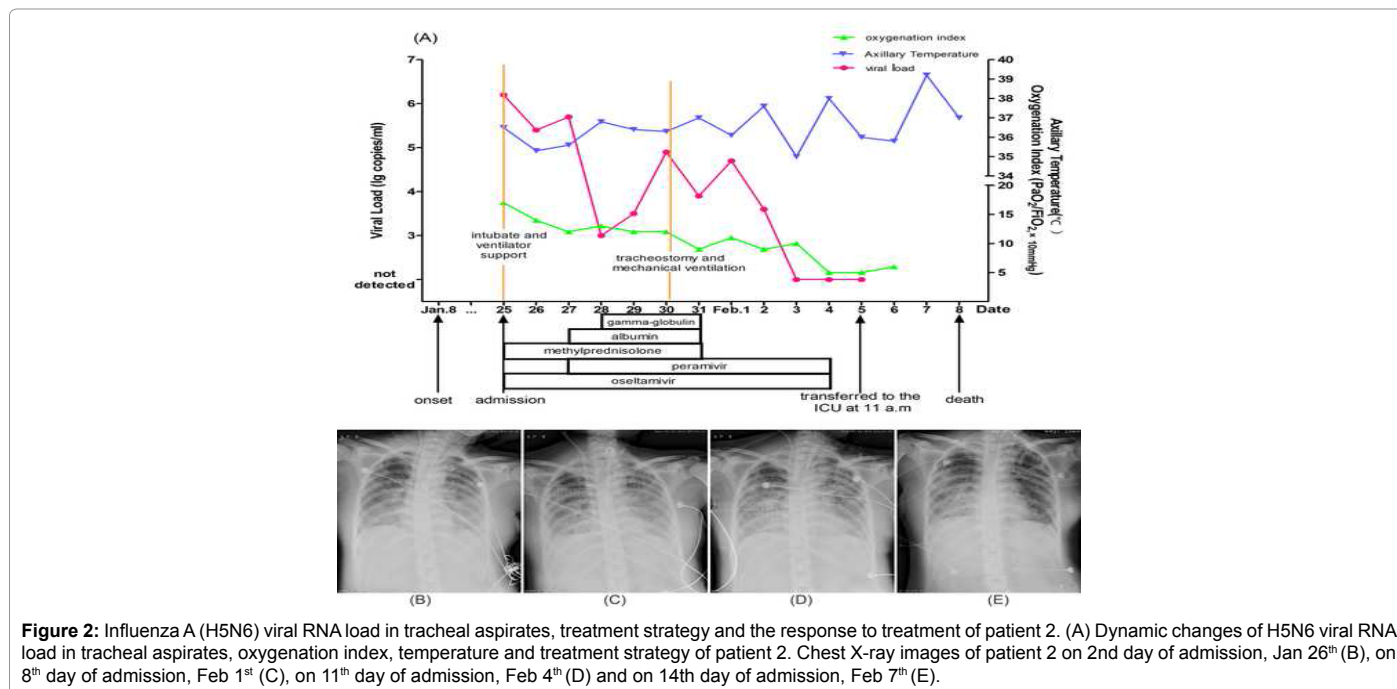


Figure 1: Influenza A (H5N6) viral RNA load in tracheal aspirates, treatment strategy and the response to treatment of patient 1. (A) Dynamic changes of H5N6 viral RNA load in tracheal aspirates, oxygenation index, temperature and treatment strategy of patient 1. CT images in the upper and middle lobe of both lungs on admission, Jan 6<sup>th</sup> (B), on 6<sup>th</sup> day of admission, Jan 11<sup>th</sup> (C), on 12<sup>th</sup> day of admission, Jan 17<sup>th</sup> (D) and on 17<sup>th</sup> day of admission, Jan 22<sup>th</sup> (E).



**Figure 2:** Influenza A (H5N6) viral RNA load in tracheal aspirates, treatment strategy and the response to treatment of patient 2. (A) Dynamic changes of H5N6 viral RNA load in tracheal aspirates, oxygenation index, temperature and treatment strategy of patient 2. Chest X-ray images of patient 2 on 2nd day of admission, Jan 26<sup>th</sup> (B), on 8<sup>th</sup> day of admission, Feb 1<sup>st</sup> (C), on 11<sup>th</sup> day of admission, Feb 4<sup>th</sup> (D) and on 14<sup>th</sup> day of admission, Feb 7<sup>th</sup> (E).

oxygen therapy and ventilator support treatment in the early phase; (III) short-term usage of low-dose corticosteroid and appropriate immune globulin in the early stage; (IV) keeping negative fluid balance in the progression period.

The US Centers for Disease Control and Prevention was advising clinicians to begin antiviral treatment as soon as possible for individuals with suspected or confirmed H7N9 influenza infection [5]. However, influenza infections always missed the best opportunity for antiviral therapy. Previous study suggested that the treatment outcome of the triple combination of amantadine, ribavirin and oseltamivir was comparable to that of oseltamivir monotherapy [6]. In our cases, we could not immediately decide whether there was a certain resistance to neuraminidase inhibitors, so we adopt oseltamivir, zanamivir and peramivir triple antivirals treatment early.

Advanced respiratory support or oxygen therapy was suggested for all inpatients to maintain the minimum SpO<sub>2</sub> at 90%, which contributed to lung function recovery to ensure the oxygen supply of vital organs. It was of great significance to shorten hospitalization time and reduce the mortality. Compared with the invasive mechanical ventilation, if the condition allows, we preferred to adopt noninvasive mechanical ventilation in the early phase to reduce the occurrence of ventilator associated pneumonia.

A previous study found that a high percentage of patients with severe avian influenza developed systemic inflammatory response syndrome (SIRS) accompanied by a high percentage of activated T cells and increased levels of serum cytokines [7]. Early administration of glucocorticoids can inhibit the inflammatory reaction, reduce the release of cytokines and inflammatory mediators, and reduce alveolar exudation [8]. Two meta-analyses on prolonged glucocorticoid treatment in severe sepsis and acute lung injury (ALI)-ARDS concluded that prolonged low-to-moderate-dose glucocorticoid treatment was safe and associated with significant reduction in organ dysfunction scores, duration of intensive care unit stay and mechanical ventilation [9,10]. Moreover, the recent literature reported that the high-dose corticosteroids (>150 mg/d methylprednisolone or its equivalent)

were associated with increased mortality and longer viral shedding in patients with influenza A (H7N9) viral pneumonia [11]. Therefore, we used low-dose corticosteroid in short-term. Patient 1 was treated with moderate-dose methylprednisolone (120 mg/d). However, patient 2 was administered high-dose methylprednisolone (maximum dose to 240 mg/d) in the Futian District People's Hospital.

In addition to shock in patients, keeping negative fluid balance in the disease progression period is vitally important for patients' prognosis. A randomized study suggested that the fluid management strategies of keeping negative fluid balance improved lung function and shortened the duration of mechanical ventilation and intensive care, without increasing extrapulmonary-organ failures [12]. Considering that the excessive strict control of liquid intake and output might worsen cardiovascular or renal function, we only adopted the fluid management strategies of keeping negative fluid balance to reach approximately -500 ml/d in the disease progression period.

In summary, the clinical features provided some evidence for diagnoses and treatment of human infected with H5N6 avian influenza virus. We conclude that combination antiviral therapy in the early stage and oxygen therapy with ventilator support are key to the treatment of infections with this virus, and proper doses of methylprednisolone and intravenous immunoglobulin are recommended. In addition, keeping negative fluid balance in the disease progression period is also vitally important.

## References

1. Dawood FS, Jain S, Finelli L, Shaw MW, Lindstrom S, Garten RJ, et al. (2009) Emergence of a novel swine-origin influenza A (H1N1) virus in humans. *N Engl J Med* 360: 2605-2615.
2. Qi X, Qian YH, Bao CJ, Guo XL, Cui LB, et al. (2013) Probable person to person transmission of novel avian influenza A (H7N9) virus in Eastern China, 2013: Epidemiological investigation. *BMJ* 347: f4752.
3. Pan M, Gao R, Lv Q, Huang S, Zhou Z, et al. (2016) Human infection with a novel, highly pathogenic avian influenza A (H5N6) virus: Virological and clinical findings. *J Infect*. 72: 52-59.
4. Liem NT, Tung CV, Hien ND, Hien TT, Chau NQ, et al. (2009) Clinical features

- 
- of human influenza A (H5N1) infection in Vietnam: 2004-2006. *Clin Infect Dis* 48: 1639-1646.
5. Kuehn BM (2013) CDC: Use antivirals early, aggressively for H7N9 flu. *JAMA* 9: 2086.
  6. Kim WY, Young SG, Huh JW, Kim SH, Kim MJ, et al. (2011) Triple-combination antiviral drug for pandemic H1N1 influenza virus infection in critically ill patients on mechanical ventilation. *Antimicrob Agents Chemother* 55: 5703-5709.
  7. Wu W, Shi Y, Gao H, Liang W, Sheng J, et al. (2014) Immune derangement occurs in patients with H7N9 avian influenza. *Crit Care* 18: R43.
  8. Cao HF, Liang ZH, Feng Y, Zhang ZN, Xu J, et al. (2015) A confirmed severe case of human infection with avian-origin influenza H7N9: A case report. *Exp Ther Med* 19: 693-696.
  9. Annane D, Bellissant E, Bollaert PE, Briegel J, Confalonieri M, et al. (2009) Corticosteroids in the treatment of severe sepsis and septic shock in adults: a systematic review. *JAMA* 301: 2362-75.
  10. Tang BM, Craig JC, Eslick GD, Seppelt I, McLean AS (2009) Use of corticosteroids in acute lung injury and acute respiratory distress syndrome: A systematic review and meta-analysis. *Crit Care Med* 37: 1594-603.
  11. Cao B, Gao H, Zhou B, Deng X, Hu C, et al. (2016) Adjuvant corticosteroid treatment in adults with Influenza A (H7N9) Viral Pneumonia. *Crit Care Med* 44: e318-28.
  12. Wiedemann HP, Wheeler AP, Bernard GR, Thompson BT, Hayden D, et al. (2006) Comparison of two fluid-management strategies in acute lung injury. *N Engl J Med* 354: 2564-2575.