

# Choriocarcinoma Presenting with Spinal Metastasis: Case Report and Review of the Literature

Keveh Ebrahimzadeh, Mohammad Hallajnejad, Amirarsalan Amin Darozarbi, Mehrdad Hosseinzadeh Bakhtevvari\*, Reza Jabbari and Omidvar Rezaei

Department of Neurosurgery, Lohman Hakim hospital, Shahid Beheshti University of Medical Sciences, Tehran, Iran

## Abstract

Gestational trophoblastic disease (GTD) is a spectrum of cellular proliferations originating from placental villous trophoblasts. Spinal metastasis of choriocarcinoma is rare, especially after a normal pregnancy. In this paper, we present a rare case of metastatic choriocarcinoma to the lumbar spine as the first manifestation of disease. The patient underwent surgery, and a dark red hemorrhagic, epidural mass was totally removed. Histopathologic studies on the mass and specimen from the episiotomy site led to a diagnosis of metastatic choriocarcinoma. Surgical resection has a limited role in metastatic choriocarcinoma, but it should be considered if rapid-onset neurological deficit appears due to spinal cord compression.

**Keywords:** Choriocarcinoma; Spinal metastasis; Lumbar vertebrae; Episiotomy scar

## Introduction

After an intrauterine or an ectopic pregnancy, and more commonly after a hydatidiform mole, a malignant and aggressive neoplasm of gestational trophoblastic epithelium of the placenta known as choriocarcinoma (CC) can appear [1,2]. Choriocarcinomas are cancers that develop from germ cells and resemble those cells surrounding an embryo in the uterus. Most of these cancers form inside the reproductive organs. Some originate in the testes or ovaries, especially in young adults. Others develop in the uterus following a pregnancy or miscarriage, particularly after a molar pregnancy. A few Choriocarcinomas arise in sites outside the reproductive organs and are usually found in young adults, more commonly in males [1-3]. Choriocarcinomas have two distinct forms, a de novo non-gestational form and the more frequently seen gestational form that consists of abnormal trophoblastic cell growth and occur once in every 20,000 to 40,000 pregnancies [3]. CC has a tendency for rapid hematogenous metastasis to multiple organs. The lung and vulvo-vaginal region are the most common locations for metastasis; CC is less commonly found in the brain and liver. Metastasis to the gastrointestinal tract, kidney, breast, or bones is extremely rare [1-5]. There are very few reports of metastasis to the spine. Herein, we report a rare case of choriocarcinoma after a normal-term pregnancy that presented primarily with spinal metastasis and metastasis to the episiotomy incision scar.

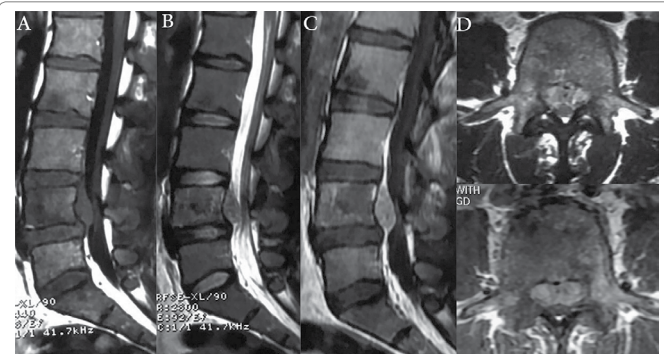
## Methods and Materials

We present a rare case of metastatic choriocarcinoma to the lumbar spine as the first manifestation of disease. A 33-year-old female patient was admitted to our hospital with low back pain increasing over the previous month that irradiated bilaterally to her ankles. She also complained of bilateral calf and anterior thigh numbness and paresthesia. The pain had worsened during the preceding week. She had just experienced her first pregnancy, which was normal with an uncomplicated full-term vaginal delivery. During the postpartum course, she reported intermittent vaginal bleeding and episiotomy wound dehiscence and underwent suturing under local anesthesia.

Upon physical examination, upper and lower extremity strength and rectal sphincter function were normal. On sensory exam, decreased sensation to light touch in a distribution that approximated the bilateral L4 and L5 dermatomes was noted. Deep tendon reflexes were normal, and no long-track signs were observed. Other systemic examinations were normal except for noted erythema and bloody discharge from the episiotomy site.

A plain radiograph of the lumbar spine was normal, but magnetic resonance imaging (MRI) showed a lumbar epidural mass posterior to the body of L4 with severe thecal sac compression which was iso-intense on T1-weighted and hyper-intense on T2-weighted images and showed marked enhancement after gadolinium administration (Figure 1). The first diagnosis was epidural abscess due to insertion of the epidural needle used for spinal anesthesia 3 months' prior for a normal vaginal delivery.

The presentation of the neurological deficit associated with thecal sac compression was a definite indication for surgical intervention. The proposed goals consisted of posterior spinal decompression. The patient underwent spinal surgery with a midline posterior approach. After an L3-L4 laminectomy, a dark-reddish, highly-hemorrhagic, firm



**Figure 1:** (A) MRI showing epidural mass posterior to L4 body that is iso-intense on sagittal T1-weighted, (B) Iso to hyper intense on sagittal T2-weighted and (C) Enhanced after gadolinium (D) Axial T1-weighted enhanced images shows compression of thecal sac.

**\*Corresponding author:** Mehrdad Hosseinzadeh Bakhtevvari, M.D. Clinical Neurosurgeon, Department of Neurosurgery, Lohman Hakim Hospital, Shahid Beheshti University of Medical Sciences, Tehran, Iran, Tel: +9821-55414065; +98912-1874506; Fax: +9821-55414065; E-mail: [mehrdaada@yahoo.com](mailto:mehrdaada@yahoo.com), [Mbakhtevvari@yahoo.com](mailto:Mbakhtevvari@yahoo.com)

**Received** May 13, 2016; **Accepted** October 13, 2016; **Published** October 15, 2016

**Citation:** Ebrahimzadeh K, Hallajnejad M, Darozarbi AA, Bakhtevvari MH, Jabbari R, et al. (2016) Choriocarcinoma Presenting with Spinal Metastasis: Case Report and Review of the Literature. J Spine 5: 336. doi: [10.4172/2165-7939.1000336](https://doi.org/10.4172/2165-7939.1000336)

**Copyright:** © 2016 Ebrahimzadeh K, et al. This is an open-access article distributed under the terms of the Creative Commons Attribution License, which permits unrestricted use, distribution, and reproduction in any medium, provided the original author and source are credited.

mass was seen posterior to the L4 body with compression on the thecal sac and was completely removed. Postoperative imaging revealed total removal of the mass lesion (Figure 2).

Histopathologic examination of the mass lesion revealed two components: multinucleated cells with a dark staining cytoplasm (syncytiotrophoblasts) and mononuclear cells which had a pale staining cytoplasm (cytotrophoblasts), indicating metastatic choriocarcinoma (Figure 3). Both components are necessary for the diagnosis of choriocarcinoma. Tissue specimens from the vertebral bodies (L3 & L4) and surrounding soft tissues were normal.

In a pathologic examination, the serum B-HCG level was found to be above 250,000 mIU/mL. A postoperative metastatic disease workup revealed a metastatic burden in the episiotomy incision. A chest and abdominopelvic CT scan, whole body bone scan, and neuraxis imaging revealed no other metastatic lesion. No metastasis was found in the lung, liver, or CNS.

The patient was referred to an oncologist, and chemotherapy was begun. During the 24-month follow-up and after chemotherapy, no recurrence or new metastasis appeared, and the serum B-HCG level was 1.8 mIU/mL. Furthermore, the patient remained symptom free.

## Discussion

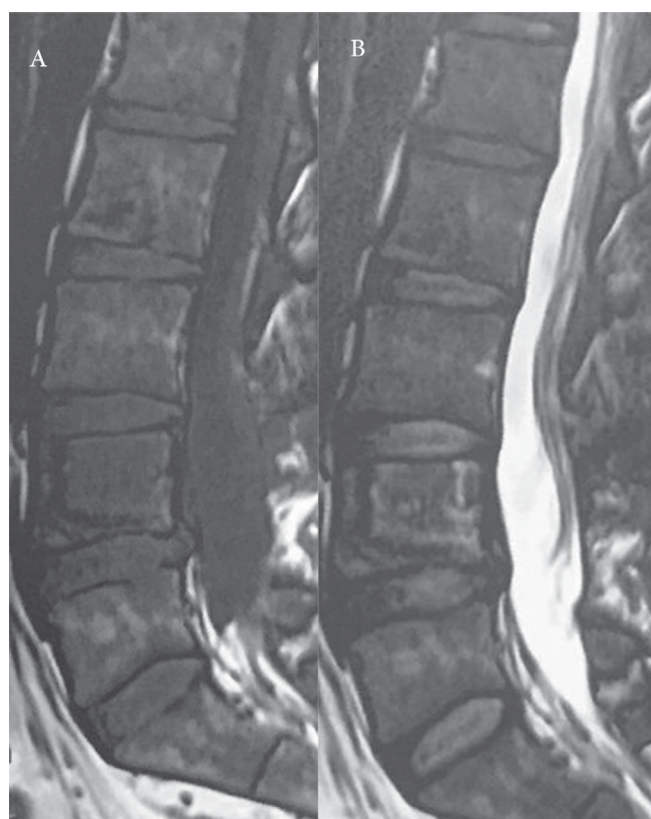
Gestational trophoblastic disease (GTD) is a spectrum of cellular proliferations originating from the placental villous trophoblast and including four main clinicopathologic forms: hydatidiform mole (complete and partial), invasive mole, choriocarcinoma, and placental site trophoblastic tumor [4]. Choriocarcinoma is a rare, highly malignant neoplasm of a trophoblastic origin among GTDs (1). It can

arise after a molar pregnancy (50%), after previous abortions (25%), in normal pregnancy (25%), and subsequent to an ectopic pregnancy (3%) [1,6]. Histopathologically, Choriocarcinomas characterized by abnormal trophoblastic hyperplasia and anaplasia, the absence of chorionic villi, hemorrhage, and necrosis. Because of direct invasion into the myometrium and vascular invasion, choriocarcinoma has a marked tendency to metastasize hematogenously [4]. Thirty percent of patients with choriocarcinoma have metastases at the time of diagnosis [7,8]. The most common organs involved by choriocarcinoma are the lungs (94% of all metastatic choriocarcinoma), vagina (44%), liver (28%), and the brain (28%); it is less commonly seen in the skin, gastrointestinal tract, kidney, breast, and bones [4,3,6,9]. The clinical presentation of metastatic choriocarcinoma varies depending on the site of involvement. Because the lung, brain, and vulvo-vaginal region are the most common sites for metastases, vaginal bleeding, chest pain, and neurological signs such as seizures or stroke are the most common presentations of the disease [5]. Metastasis in the spine is extremely rare, and only a few cases have been reported in the literature (Table 1) [10-21].

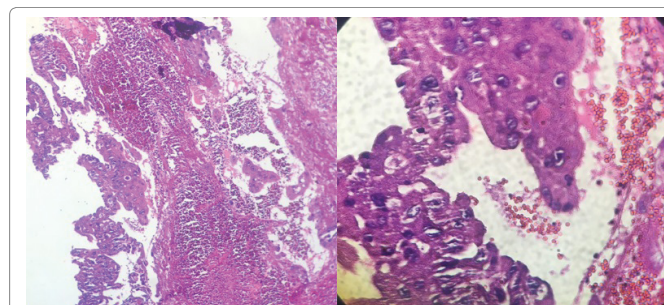
The patients age at presentation range from 20 to 44 years. Eight cases undergone surgery with chemo radiotherapy. Fourteen cases had more than one site of metastases (spinal and extra spinal metastasis), and only one of them had an epidural spinal metastasis. Kuten et al. reported a case of caudaequina compression due to epidural metastatic gestation choriocarcinoma a 20-year-old woman. Complete remission and disappearance of the neurological deficit were achieved with chemotherapy and radiotherapy, allowing a subsequent normal pregnancy and delivery; the patient remained alive during the 4 years of follow-up [7]. Qian reported choriocarcinoma in the cesarean scar of a 22-year-old woman [22].

However, to the best of our knowledge and based on the literature review, metastasis of choriocarcinoma to an episiotomy incision has never before been reported.

Choriocarcinomas are cancers that develop from germ cells and resemble those cells surrounding an embryo in the uterus. Most of these cancers form inside the reproductive organs. Metastatic choriocarcinoma can occur during or after any type of pregnancy, about half of the reported cases preceded by hydatidiform mole, the other cases presented in ectopic pregnancy and normal pregnancy [4,7,10,11,21]. Choriocarcinoma is most sensitive to chemotherapy [18], and remission rates in the nonmetastatic stage of choriocarcinoma are 98% to 100% and more than 75% even in cases of metastatic choriocarcinoma [4,8,23]. Based on previous cases, the survival rate of patients with choriocarcinoma with spinal metastasis is not favorable, and chemotherapy is the treatment of choice. Decompressive surgery



**Figure 2:** Post-operative imaging revealed total removal of the mass lesion (A: Sagittal T1-weighted image. B: sagittal T2-weighted image).



**Figure 3:** Pathologic examination revealed two components: multinucleated cells with a dark staining cytoplasm (syncytiotrophoblasts) and mononuclear cells which had a pale staining cytoplasm (cytotrophoblasts),

Authors	Age/Sex	Spinal metastasis	Other metastasis	Neurologic deficit	Surgery	Chemotherapy	radiotherapy	outcome
Azzopardi et al., 1961 [10]	26/M	Vertebral body	Liver, lung, brain, kidney, spleen, psoas, testis, retroperitoneal	None	No	Yes	No	Death 6 weeks after admission
Kuten et al., 1978 [7]	20/F	L1-3 Epidural	No	Paraparesis	L1-3 Laminectomy	Yes	Yes	Alive during 4 years follow up
Eskreis et al., 1988 [11]	33/F	T2-3	Stomach	Urine incontinency, lower extremity weakness and sensory loss	T2-3 Laminectomy	Yes	Yes	Alive until follow up (6 weeks)
Rustin et al., 1989 [12]	F	Lumbar spine	Unknown	Unknown	Unknown	Yes	No	Unknown
Vani et al., 1993 [13]	27/ F	S5	lung, gluteal	Unknown	No	Yes	Yes	Lost follow up
Williamson et al., 1994 [14]	26/ M	Vertebral bodies	testis, liver, spleen, kidneys, pancreas, thyroid, adrenals, eyes, lung	Visual loss	No	Yes	Yes	Death 1 month after admission
Beşkonakli et al., 1998 [15]	44/F	T5 Body	Uterus	Urine incontinency and difficult walking	T4-6 Laminectomy and tumor resection	Yes	No	Death after 5 months without neurological improvement
Balat et al., 2004 [16]	24/F	T5 Body, T3-5 Epidural	ovary, sternum	Paresthesias	T5 Corpectomy	Yes	No	Death during chemotherapy
Menegaz et al., 2004 [17]	41/F	L2-S1 Epidural space	iliopsoas, lungs, uterus	Cauda equine Syndrome	No	Yes	Yes	Death after 5 months
Natio et al., 2009 [18]	38/ F	L2 Body	Lung	None	L2 vertebrectomy, L1-3 posterolateral fusion (PSF)	Yes	Yes	Death 3 months after surgery
Lee et al., 2010 [1]	33/F	L3 body, pedicle and epidural Space	brain, lung, uterus	Paraparesis	Embolization, L3 laminectomy, L2-4 PSF, L3 vertebroplasty	Yes	NO	Remission during 10 months
Guber et al. 2011 [19]	26/F	Not mentioned	Eye, lung, brain, kidney, liver	Visual loss	No	Yes	Yes	Remission during 4 years follow up
Ko et al., 2012 [8]	21/F	L2 body	Thoracic intramedullary, brain, lungs	Paraplasia and sensory level	No	Yes	Yes	Death after 13 months
Skoch et al., 2014 [20]	30/ M	C3 body, L2 Body and Epidural Space	Retroperitoneal, Lung, Liver, Testis, Brain	Paraparesis and sensory loss	L1-13 Laminectomy, T12-L4 PSF	Yes	No	Death 22 days after admission
Atjimakul et al., 2014 [21]	34/F	L1-L2 vertebral bodies T11-L4 epidural	Lung	Paraparesis	Laminectomy	Yes	No	Remission (10 months after diagnosis)

M: Male  
F: Female  
\* Metastatic choriocarcinoma in these patients originated from testicular mass.

**Table 1:** Literature review of 15 cases of metastatic choriocarcinoma of the spine.

for metastatic choriocarcinoma to the spine is recommended only when rapid-onset neurologic decline appears [20].

## Conclusion

We report a rare case of metastatic choriocarcinoma to the lumbar vertebral body and epidural space after an uneventful pregnancy. The interesting aspect of this case is the presentation of the disease well after delivery, so that choriocarcinoma was not among the most probable diagnoses. Metastatic choriocarcinoma is a rare differential diagnosis of low back pain after pregnancy and should be considered in differential diagnoses. Surgery has a limited role with this form of the disease, but could be considered for progressive neurologic decline.

## Conflict of Interest

All authors certify that they have no affiliations with or involvement in any organization or entity with any financial interest or non-financial interest in the subject matter or materials discussed in this manuscript.

There is no funding or conflict of interest.

There are no financial disclosures.

## References

- Lee JH, Park CW, Chung DH, Kim WK (2010) A case of lumbar metastasis of choriocarcinoma masquerading as an extraosseous extension of vertebral hemangioma. J Korean Neurosurg Soc47: 143-147.
- Cole LA, Khanlian SA, Muller CY, Giddings A, Kohorn E, et al. (2006) Gestational trophoblastic diseases: 3. Human chorionic gonadotropin-free beta-subunit, a reliable marker of placental site trophoblastic tumors. Gynecol Oncol 102: 160-164.
- Hensley JG, Shviraga BA (2014) Metastatic choriocarcinoma in a term pregnancy: a case study. MCN Am J Matern Child Nurs 39: 8-15.
- Lurain JR (2010) Gestational trophoblastic disease I: epidemiology, pathology, clinical presentation and diagnosis of gestational trophoblastic disease, and management of hydatidiform mole. Am J Obstet Gynecol 203: 531-509.
- Chung C, Kao MS, Gersell D (2008) Incidental placental choriocarcinoma in a term pregnancy: A case report. Int J Gynecol Pathol 1: 330.
- Huang CY, Chen CA, Hsieh CY, Cheng WF (2007) Intracerebral hemorrhage as initial presentation of gestational choriocarcinoma: a case report and literature review. Int J Gynecol Cancer 17: 1166-1171.
- Kuten A, Cohen Y, Tatcher M, Kobrin I, Robinson E (1978) Pregnancy and delivery after successful treatment of epidural metastatic choriocarcinoma. Gynecol Oncol 6: 464-466.



8. Ko JK, Cha SH, Lee JH, Choi CH (2012) Intramedullary spinal cord metastasis of choriocarcinoma. *J Korean Neurosurg Soc* 51: 141-143.
9. Weir B, MacDonald N, Mielke B (1978) Intracranial vascular complications of choriocarcinoma. *Neurosurgery* 2: 138-142.
10. Azzopardi JG, Mostofi FK, Theiss EA (1961) Lesions of testes observed in certain patients with widespread choriocarcinoma and related tumors. The significance and genesis of hematoxylin-staining bodies in the human testis. *Am J Pathol* 38: 207-225.
11. Eskreis D, Zinberg J, Manzione NC, Jones J (1988) Metastatic choriocarcinoma to the stomach presenting as hematemesis. *Dig Dis Sci* 33: 247-250.
12. Rustin GJ, Newlands ES, Begent RH, Dent J, Bagshawe KD (1989) Weekly alternating etoposide, methotrexate, and actinomycin/vincristine and cyclophosphamide chemotherapy for the treatment of CNS metastases of choriocarcinoma. *J Clin Oncol* 7: 900-903.
13. Vani R, Kuntal R, Koteswar RK (1993) Choriocarcinoma following term pregnancy with bone metastasis. *Int J Gynaecol Obstet* 40: 252-253.
14. Williamson KF, Barry DR, Sutton GA, Jones EL, Crews SJ (1994) Male choriocarcinoma with choroidal metastases. *Br J Ophthalmol* 78: 155-156.
15. Beskonakli E, Cayli S, Kulacoglu S (1998) Metastatic choriocarcinoma in the thoracic extradural space: case report. *Spinal Cord* 36: 366-367.
16. Balat O, Kutlar I, Ozkur A, Bakir K, Aksoy F, et al. (2004) Primary pure ovarian choriocarcinoma mimicking ectopic pregnancy: a report of fulminant progression. *Tumori* 90: 136-138.
17. Menegaz RA, Resende AD, Da Silva CS, Barcelos AC, Murta EF (2004) Metastasis of choriocarcinoma to lumbar and sacral column. *Eur J Obstet Gynecol Reprod Biol* 113: 110-113.
18. Naito Y, Akeda K, Kasai Y, Matsumine A, Tabata T, et al. (2009) Lumbar metastasis of choriocarcinoma. *Spine (Phila Pa 1976)* 34: E538-E543.
19. Guber I, Zografos L, Schalenbourg A (2011) Choroidal metastases in testicular choriocarcinoma, successful treatment with chemo- and radiotherapy: a case report. *BMC Urol* 11: 24.
20. Skoch J, Kobylanski K, Rice JM, Baaj AA (2014) Metastatic choriocarcinoma to the lumbar spine: Case report and review of literature. *Surg Neurol Int* 5:161.
21. Atijmakul T, Hanprasertpong J, Saeai N (2014) Choriocarcinoma with spinal metastasis: A case report and literature review. *Mol Clin Oncol* 2: 1019.
22. Qian ZD, Zhu XM (2014) Caesarean scar choriocarcinoma: a case report and review of the literature. *Eur J Med Res* 19: 25.
23. Athanassiou A, Begent RH, Newlands ES, Parker D, Rustin GJ, et al. (1983) Central nervous system metastases of choriocarcinoma. 23 years' experience at Charing Cross Hospital. *Cancer* 52: 1728-1735.