

# Chest Discomfort Secondary to Ossification of the Ligamentum Flavum of the Thoracic Spine: A Case Report

Chungnam Lee<sup>1</sup>, Minsoo Kang<sup>1\*</sup>, Sangho Lee<sup>1</sup>, Yonghwan Shin<sup>1</sup> and Chanhong Park<sup>2</sup>

<sup>1</sup>Department of Neurosurgery, Spine Health Wooridul Hospital, Daegu, South Korea

<sup>2</sup>Department of Anesthesiology, Spine Health Wooridul Hospital, Daegu, South Korea

## Abstract

Symptomatic thoracic ossification of the ligamentum flavum is rare, and a modality for its treatment has not yet been fully established; most reported patients complained of myelopathy. Herein, the authors will report on an extremely rare presentation of thoracic ossification of the ligamentum flavum, along with clinical outcomes. The patient complained of chest discomfort and myelopathy symptoms for 1 year secondary to thoracic ossification of the ligamentum flavum. He underwent one surgical procedure. Postoperatively, his symptoms such as chest discomfort and myelopathy improved completely. As of this report, the patient has had a good postoperative recovery, had good overall health, and adapted well to his social activities.

**Keywords:** Ossification of the ligamentum flavum; Thoracic spine; Chest discomfort

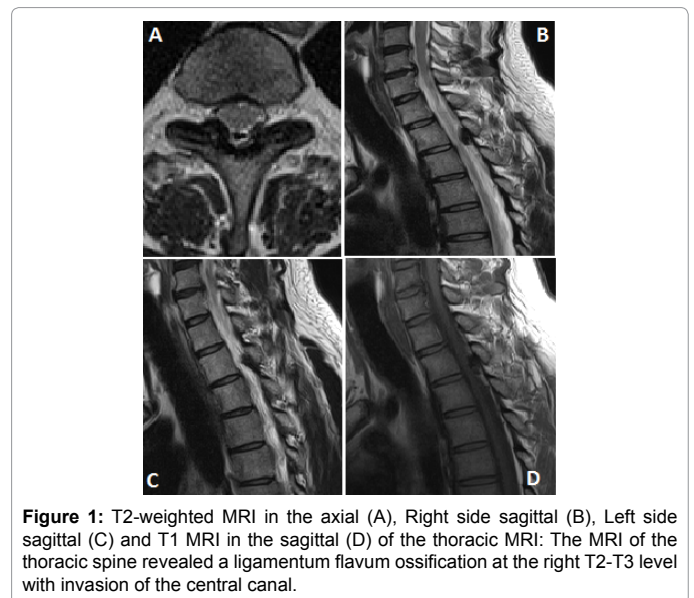
## Introduction

Generally, although patients with cervical and lumbar stenosis have symptoms characteristic of the condition, patients with thoracic spinal stenosis rarely experience symptoms [1]. Clinical symptoms of thoracic spinal cord compression usually develop in the canal, which has an anteroposterior diameter of less than 10 mm [10-6]. This usually occurs in cases involving vertebral trauma, a herniated thoracic disc, spondylosis, osseous overgrowth secondary to general bone and joint disorders, metabolic disease, ankylosis, and hypertrophy of posterior spinal elements [2,3]. Among the above-mentioned issues, thoracic ossification of the ligamentum flavum (thoracic OLF or TOLF), a main cause of thoracic myelopathy, is a rare disease entity [4,5]. Although TOLF usually occurs in the lower thoracic spine, it has been reported at higher thoracic levels [6]. Herein, the authors will report on an extremely rare presentation of OLF in the thoracic spine in a patient who experienced chest discomfort.

## Case Report

A 41-year-old man complained of chest tightness and discomfort for 3 months. In addition, he complained of numbness in both arms and had a hard time walking because of bilateral calf and plantar numbness. The patient obtained medical care from thoracic and cardiovascular surgeons at several hospitals because of chest pain, and only heard stories that there is no longer at all in the electrocardiogram (EKG) and echocardiography. Further, physical therapy and medication were the only treatments performed for the leg numbness. As the patient's symptoms such as chest pain did not improve, he quit his job and had stable care at home. A week before a visit to the hospital, he experienced an almost unbearable pain that resulted in his admission to our hospital and was considered an urgent matter. He underwent an EKG and pulmonary function tests. However, no abnormal findings were observed during either test. At the time of his admission, his neurological exam revealed bilateral leg numbness and a limping gait without any noticeable weakness, and he complained of severe chest pain.

Magnetic resonance imaging (MRI) of his cervical, thoracic, and lumbar spine revealed ligamentum flavum ossification at the right T2-T3 level with invasion of the central canal. The lesion had no high signal intensity on T2-weighted images and was isointense on T1-weighted images that was analogous to a muscle signal intensity (Figure 1), Computed tomography (CT) of thoracic revealed ligamentum flavum ossification with compression of the central canal (Figure 2).



**Figure 1:** T2-weighted MRI in the axial (A), Right side sagittal (B), Left side sagittal (C) and T1 MRI in the sagittal (D) of the thoracic MRI: The MRI of the thoracic spine revealed a ligamentum flavum ossification at the right T2-T3 level with invasion of the central canal.

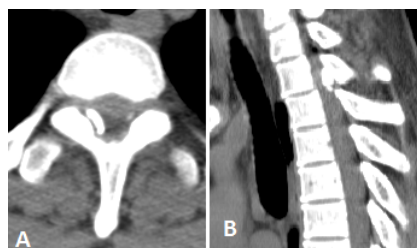Although several evaluations were performed because of the patient's symptoms, no specific details were revealed. The T2-T3 lesions were thought to be the most likely cause, and a surgeon decided to operate on these lesions. The patient underwent a bilateral laminotomy to remove the ligamentum flavum. First, it was performed on a lesion on the right side. When the right laminectomy was performed, no spinal cord pulsation was observed, and the calcified right ligamentum flavum was surgically removed. After the right laminectomy was sufficiently performed, it was possible to remove the left ligamentum flavum. When the left ligamentum flavum was removed, pulsation of the dura was confirmed, and the operation was terminated.

**\*Corresponding author:** Minsoo Kang M.D., Department of Neurosurgery, Spine Health Wooridul Hospital, Daegu, South Korea, Tel: +82 51 559 5004, E-mail: [bd21c@hanmail.net](mailto:bd21c@hanmail.net)

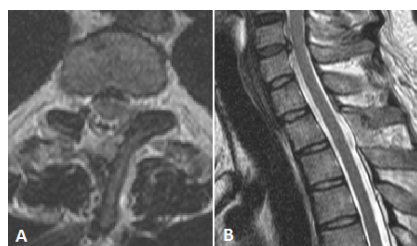Received April 18, 2017; Accepted April 26, 2017; Published April 28, 2017

**Citation:** Lee C, Kang M, Lee S, Shin Y, Park C (2017) Chest Discomfort Secondary to Ossification of the Ligamentum Flavum of the Thoracic Spine: A Case Report. J Spine 6: 370. doi: [10.4172/2165-7939.1000370](https://doi.org/10.4172/2165-7939.1000370)

**Copyright:** © 2017 Lee C, et al. This is an open-access article distributed under the terms of the Creative Commons Attribution License, which permits unrestricted use, distribution, and reproduction in any medium, provided the original author and source are credited.



**Figure 2:** Computed tomography in the axial (A) and sagittal (B): The CT of thoracic spine revealed ligamentum flavum ossification with compression of the central canal.



**Figure 3:** Post-operative T2-weighted MRI in the axial (A) and sagittal (B): The MRI shows that ligamentum flavum with calcification was removed and there is no evidence of cord compression.

Postoperatively, the patient's symptoms such as chest tightness and bilateral arm numbness improved immediately, except for surgical site pain. T2-3 level of spinal stenosis in postoperative MRI imaging was able to confirm that decompression was enough (Figure 3). The patient was discharged 10 days postoperatively, and all his symptoms had improved; as of this report, 5 months after the operation, he had adapted well to social activities.

## Discussion

OLF, also known as ossification of the yellow ligament, is a pathological condition that affects the ligament and causes a slow and progressive myelofurculopathy [1,7-9]. TOLF is rare and usually asymptomatic [1]. In a survey of radiographic findings conducted in Japan, the prevalence of asymptomatic thoracic and lumbar OLF in adults was as high as 6.2% for men and 4.8% for women [8,10]. The disease usually has an insidious onset and a slow progression [1,9]. However, once symptomatic OLF is diagnosed, it is usually progressive and refractory to conservative management, and surgical decompression is indicated. In general, it is diagnosed using MRI, myelography, computed tomography, and plain radiographs [1,6,11,12].

TOLF was first reported by Polgar in 1920 based on lateral radiographs [5]. Since then, hundreds of cases of TOLF have been reported in several clinical series and numerous case reports [5]. Kazuhiko Shiokawa et al. introduced a 31-case series of middle-aged men who had symptomatic TOLF lesions at a lower thoracic level in 2001 [9]. Shisheng et al. reported on 27 patients who had TOLF [7]. All the above-mentioned patients had symptomatic lesions, and all underwent a total laminectomy. The predominant symptom most patients had was myelopathy, and the doctors think there was no problem for the primary lesion because it is not observed the different lesion. Se-Jun et al. reported that the most common symptoms were lower extremity motor dysfunction and sensory deficits in TOLF, not pain, numbness, and claudication [11].

However, the myelopathic symptoms our case experienced were

not severe enough for the patient to complain of numbness, and the patient's main symptom was chest discomfort. The patient has seen a doctor with many other appealing when he complained of the first symptoms that are not general and doctors did not doubt that was the TOLF suffered several misdiagnoses. The patient was suffering from the steadily worsening symptoms without any other checks and were performed last thoracic MRI after he toured with several procedures.

As this rare case demonstrates, TOLF can be difficult to distinguish from unspecific diseases that present with chest discomfort. We did not find any clinical signs that would allow us to distinguish between TOLF and other diseases in medical literature. Several doctors have emphatically not a doubt about TOLF during the patient complained of symptoms and patient had a hard time that the symptoms did not improve at all during he receive different treatment for months. We observed that the patient experienced dramatic clinical improvement within 1 day of the operation. Currently, patients are returning to work and can enjoy a satisfying and normal life. Most importantly, doctors should consider TOLF in patients who have chest discomfort, not just severe myelopathy, to avoid misdiagnosis. However, the sooner patients are diagnosed, the faster patients can return to a normal life.

## Conclusion

Symptomatic OLF-induced thoracic cord compression is rare. MRI can provide sufficient clues for establishing a TOLF diagnosis. Unspecific TOLF is easy to miss, and it is important that physicians suspect this condition when patients experience symptoms that are not severe.

## References

1. Liao CC, Chen TY, Jung SM, Chen LR (2005) Surgical experience with symptomatic thoracic ossification of the ligamentum flavum. *J Neurosurg Spine* 2: 34-39.
2. Epstein NE (1999) Ossification of the yellow ligament and spondylosis and/or ossification of the posterior longitudinal ligament of the thoracic and lumbar spine. *J Spinal Disord* 12: 250-256.
3. Epstein NE, Schwall G (1994) Thoracic spinal stenosis: Diagnostic and treatment challenges. *J Spinal Disord* 7: 259-269.
4. Kang KC, Lee CS, Shin SK, Park SJ, Chung CH (2011) Ossification of the ligamentum flavum of the thoracic spine in the Korean population: Clinical article. *J Neurosurg Spine* 14: 513-519.
5. Wang W, Kong L, Zhao H, Dong R, Li J, et al. (2007) Thoracic ossification of ligamentum flavum caused by skeletal fluorosis. *Eur Spine J* 16: 1119-1128.
6. Tokala DP, Lam KS, Prince HG (2007) Ossification of the proximal thoracic ligamenta flava causing acute myelopathy in a Caucasian: Case report and literature review. *Spinal Cord* 45: 310-313.
7. Shisheng He, Hussain N, Li S, Hou T (2005) Clinical and prognostic analysis of ossified ligamentum flavum in a Chinese population. *J Neurosurg Spine* 3: 348-354.
8. Inamasu J, Guiot BH (2006) A review of factors predictive of surgical outcome for ossification of the ligamentum flavum of the thoracic spine. *J Neurosurg Spine* 5: 133-139.
9. Shiokawa K, Hanakita J, Suwa H, Saiki M, Oda M, et al. (2001) Clinical analysis and prognostic study of ossified ligamentum flavum of the thoracic spine. *J Neurosurg* 94: 221-226.
10. Kudo S, Ono M, Russell WJ (1983) Ossification of thoracic ligamenta flava. *AJR Am J Roentgenol* 141: 117-121.
11. Abiola R, Rubery P, Mesfin A (2016) Ossification of the posterior longitudinal ligament: Etiology, diagnosis, and outcomes of nonoperative and operative management. *Global Spine J* 6: 195-204.
12. Hanakita J, Suwa H, Ohta F, Nishi S, Sakaida H, Iihara K (1990) Neuroradiological examination of thoracic radiculo-myelopathy due to ossification of the ligamentum flavum. *Neuroradiology* 32: 38-42.