

Rape and Strangulation of Kid with Creeper Plant

Sabyasachi Nath* and Hemanta K Pratihari

Forensic Division, State Forensic Science Laboratory, Tripura, India

Abstract

The rape crime-clock is very alarming compared to other crime against women in India. It is seen that different age groups including kids are the victim of such menace. In one case, a 6½-year kid used to visit the neighbouring house to play with her girl friend of same age. One day, the uncle (father of her friend) lured her and took her to a nearby bushy area close to the house. The kid was raped there and strangulated with a flexible wild creeper (rope like plant material) and abandoned naked on the spot. In the mean-time, parents of the victim girl enquired the place where she often used to visit and play. Since several hours passed without any result, an FIR was lodged in the local police station. Subsequently in the late evening, the detection of a dead body (kid) was reported and identified to be the same missing kid. As per secret input, it was ascertained that the deceased (kid) was last seen with the accused moving towards the bushy area in mid hour of the day. The undisturbed crime spot was examined by the police and forensic team to collect physical evidence and establish the crime and criminal. The autopsy findings and criminal psychology along with other details have been discussed in this paper.

Keywords: Kid • Rape • Strangulation • Wild creeper • Naked body • Autopsy findings

Introduction

As per National Crime Records Bureau (NCRB), MHA, Govt. of India, 33,356 cases of rape has been reported in 2018, roughly 91 a day [1], but expert says that rape incidents are much higher. The Lok Sabha unanimously passed the protection of children from sexual offence amendment bill 2019 seeking death penalty for aggravated sexual assault on children. Study reveals that in more than 90% cases of rape, victims are well known to their assailants either friend, relative or neighbor and the rest 10% or less are stranger [2]. Sexual homicide (rape-murder) is comparatively less and statistical data is also not available in literature [3]. In sexual-homicide cases, behavior of the accused is observed to be different than normal sexual offenders [4]. Rape followed with murder is heinous and committed with aggressive behavior of the offender under different situations resulting death of the victim.

During investigation of a rape and murder case, the investigative agency and forensic team need to analyze the undisturbed crime scene as quickly as possible to collect evidence considering the following issues and to link between victim, crime scene and criminal for successful investigation [4-7]:

- Timely management of crime scene with proper documentation
- Photograph/sketch of crime scene/injury on body/private parts
- Strangling materials used (like rope, wire, dupatta, long cloth etc.)
- Photograph of strangulation mark with scale
- Other post strangulation symptoms on rape victim
- Condition of wearing apparel of victim
- Footwear position of victim/suspect on crime spot
- Foot/shoe print on spot for comparison
- Soil/pollen on body/wearing apparel along with control sample
- Blood stained soil along with control soil sample
- Sign of dragging of body on crime spot
- Collection of hair from spot/wearing apparel of victim

- Condom used during assault be swabbed separately both from inner/outer surfaces
- Collection of biological evidence (vaginal/anal/oral swab) by registered medical officer using sexual assault evidence collection kit (SAECK)
- Autopsy of victim by a team of medico legal experts
- Nail clippings of rape victim for examination of blood/skin/tissue
- Viscera/urine of victim for rape-drug analysis
- Different biological samples, hair and wearing apparel of suspect for examination/comparison
- Family history of victim and other details to help investigation
- Post analysis of violent crime scene and criminal profile
- Collection of cell phone of victim/suspect to analyse call records.

Case Report

A kid age about 6½-year used to visit and play with her neighbouring girlfriend. Taking advantage of the age and innocence, one day her friend's father lured and took her to a nearby bushy area and raped her. At this age, the kid could not understand what was being done on her. The elderly accused brutally raped and strangulated the kid with available wild creeper plant and abandoned the dead body in that lonely place to go undetected and escape stringent punishment. The case was registered under different sections of Indian Penal Code (IPC) and Protection of Children from Sexual Offence (POCSO) Act 2012.

Observation

The position of the strangulated body at the scene of crime and other evidence are shown in Figures 1-5.

*Address for Correspondence: Sabyasachi Nath, Forensic Division, State Forensic Science Laboratory, Tripura, India, Tel: 0381-2341266; Fax: 0381-2341266; E-mail: drsabyasachinath@gmail.com

Copyright: © 2021 Nath S, et al. This is an open-access article distributed under the terms of the creative commons attribution license which permits unrestricted use, distribution and reproduction in any medium, provided the original author and source are credited.

Received: 26 February, 2021; Accepted: 12 March, 2021; Published: 19 March, 2021



Figure 1. Victim lying on spot (in a bushy area).



Figure 2. Wild creeper plant tied around neck to strangle the victim.

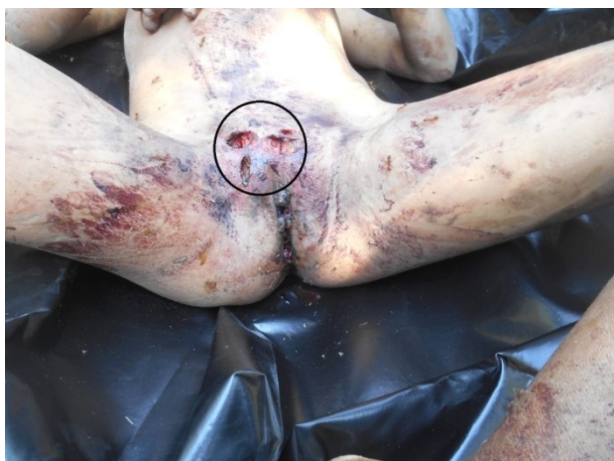

Figure 3. Multiple deep laceration wounds above the vagina with bleeding injury.

Autopsy findings

External: The deceased was about 6½-year old girl. On external examination, one deep lacerated wound was found above the mid nostril. External genitalia i.e., labia majora and labia minora, were found freshly torn and lacerated and extended up to the anterior commissure through vaginal canal with torn hymen. Multiple small bruises were found over the trunk of the body. A ligature mark over the neck, below the occipital region, was found on removal of the ligature material (wild creeper plant) that tied around the neck, the knot being found just below the mid occipital region.




Figure 4. Wooden stick with blood stain at one end used to inflict injury on the victim.



Figure 5. Strangling material (wild creeper plant) cut during autopsy.

Internal: No abnormality was detected in the scalp, skull, vertebrae, meninges, ribs, cartilages, vessels, peritoneum, pharynx and oesophagus. Brain, spinal cord, pleurae, larynx, trachea, both the lungs, pericardium, liver, small and large intestines, spleen, both kidneys were found congested. Three deep laceration marks were found on the lower abdominal wall, few cm above the vaginal wall. Semisolid food particle was found in the stomach. Rigor mortis was present.

Cause of death was asphyxia as a result of strangulation by a plant ligature material.

Forensic findings

- Vaginal swab analysis reveals the presence of blood of human origin and matched with the victim,
- One stained wooden stick detected on the spot, was also found to contain blood stain of human origin and matched with the victim suggesting its use to inflict injury on the victim,
- The wild creeper plant, a unique strangulating material, first-ever seen in such cases to cause asphyxial death, was also detected to have human blood stain,
- The viscera analysis ruled out the presence of any poison and rape drug in this case,
- A half pant (man's wear) was recovered from the crime spot. This was subsequently identified to be wearing apparel of the suspect. The pant was initially used for sniffer dog to track the wearer and found to be a useful physical evidence during investigation/and forensic examination.

Discussion

This is an inhuman sex act with a kid and the rarest of rare rape-murder crimes. The timely examination of the crime scene by forensic team and police with dog squad could help to collect incriminating physical evidence to establish the crime and criminal. The medico-legal examination of the victim without delay could help to collect biological fluid for forensic examination/ comparison showing encouraging results. Further, injuries found near the genital tract, caused by a foreign body, corroborated the findings of autopsy study and forensic examination. The criminal profile of the accused in this case, appears to be emotionally distressed and aggressive. The accused, no doubt, is a psychopath and further examination is required by a psychiatrist

to know the mental behavior. All section of the people in the society must fight to stop such 'child sexual abuse' as a national mission.

Conclusion

This is a violent crime and the victim and the accused are known to each other being close neighbour. The use of sniffer dog on the spot, forensic analysis of physical evidence and autopsy findings conclusively proved the case to be rape-murder of a kid in this case. The accused is sexually perverted and a psychopath. Psychiatric analyses of all the accused in such cases must be made mandatory for better assessment of criminal profile and suggest appropriate remedies.

Acknowledgement

The authors are thankful to Ms Monica Debbarma, Sr. Scientific Officer for analysis of the viscera samples, Mr. Santanu Debbarma, Sr. Scientific Assistant, for collecting the crime scene photos and autopsy surgeon for autopsy findings in this case.

References

1. National Crime Records Bureau (2018), Ministry of Home Affairs, Government of India.
2. Whealin, Julia M. "Child Sexual Abuse." National Center for Post-Traumatic Stress Disorder, US Department of Veterans Affairs, USA, 2007.
3. Nath Sabyasachi and Hemanta Kumar Pratihari. "Gang Rape and Murder– A Case Report." *J Forensic Sci Criminal Inves* 10 (2018): 1-4.
4. Salfati, Gabrielle C and Paul Taylor. "Differentiating sexual violence: A comparison of sexual homicide and rape." *Psychol Crime Law* 12 (2006): 107-125.
5. Nath, Sabyasachi and Hemanta Kumar Pratihari. "Rape-Murder of a Kid– A Rare Case Report." *J Forensic Sci Criminal Inves* 13 (2019): 1-3.
6. Fisher, Barry AJ. "Techniques of crime scene investigation." Seventh Edition, CRC Press LLC, Boca Raton, Newyork, UK, 2004.
7. Becker, Ronald F. "Criminal Investigation." Third Edition, Jones and Bartlett Publishers, Sudbury, Massachusetts, USA, 2009.

How to cite this article: Sabyasachi Nath and Hemanta K Pratihari. "Rape and Strangulation of a Kid with Creeper Plant ". *J Forensic Res* 11 (2020) doi: 10.37421/2157-7145.11.186