

## Cauda Equina Lymphoma – Case Report and Review of Literature

Pedro R Biasi<sup>1\*</sup>, Luan Lucena<sup>1</sup>, Rafael Augusto Espanhol<sup>1</sup>, Timóteo Abrantes de Lacerda Almeida<sup>1</sup>, Matheus Pintos Brunet<sup>1</sup>, Wellington César de Souza<sup>1</sup>, Eduardo Felipe Martinelli Baldissera<sup>1</sup>, Laura Regyna Toffoli Roso<sup>2</sup>, Lúidia Varrone Giacomini<sup>2</sup>, Fernando Luiz Giacomini<sup>3</sup>, Adroaldo Baseggio Mallmann<sup>4</sup> and Charles André Carazzo<sup>4</sup>

<sup>1</sup>Neurosurgery Resident, Departamento of Neurosurgery, São Vicente de Paulo Hospital, Brazil

<sup>2</sup>Medical student of University of Passo Fundo, Brazil

<sup>3</sup>Neurophysiologist of São Vicente de Paulo Hospital, Brazil

<sup>4</sup>Neurosurgeon of Institute of Neurology and Neurosurgery of Passo Fundo, Brazil

### Abstract

The Primary Central Nervous System Lymphoma is an uncommon disease and rarely affects the spinal cord. The authors present the case of a female patient, 67 year-old, with paresis of the left leg. Lumbosacral MRI depicts focal thickening of the cauda equina roots at L2 level, isointense on T1W and hyperintense on T2W with intense contrast enhancement. Immunohistochemistry analysis of a biopsied root confirmed the diagnosis of Diffuse Large B-cell Lymphoma. The PCNSL, generally represented by Large B-cells subtype, affects the spinal cord in less than one per cent of the cases and are generally associated with cytogenetic changes on BCL-6 gene. The appearance on MRI is not characteristic, evidencing the focal volumetric increase of the cauda equina roots, with intense contrast enhancement, being not possible to differentiate between lesions as schwannomas and meningiomas. For the diagnosis is necessary biopsy of the lesion and after intraoperative confirmation, resection should be suspended because it is not effective. The treatment is based on chemotherapy and radiotherapy, however, the prognosis is poor.

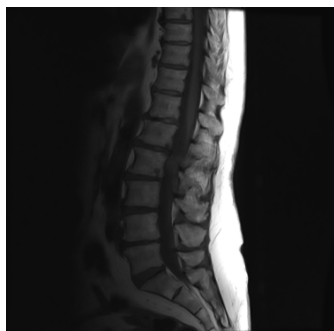**Keywords:** Cancer; Central nervous system; Lymphoma; Cauda equina

### Introduction

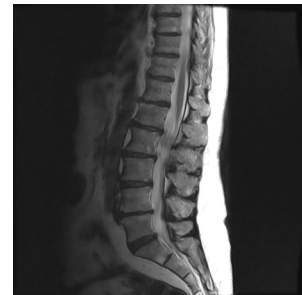Primary central nervous system lymphoma (PCNSL) is an aggressive type of lymphoma that arises in the brain parenchyma or spinal cord, eyes, cranial nerves, and meninges, usually represented by Difuse Large B-Cell subtype. PCNSL can occur in immunocompetent as well as in immunocompromised hosts, including human immunodeficiency virus (HIV)-infected people or posttransplant patients [1-3]. The authors describe a case of primary lymphoma of the cauda equina, making a review of the literature about this disease.

### Case Report

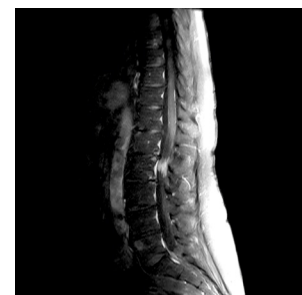Female patient, 67, started paresis of the left leg 2 months ago, slowly progressive, not associated with pain or paresthesias. Physical examination revealed diffuse and asymmetric paresis of the left leg, with the absence of patellar and ankle reflexes. It was held lumbosacral spine magnetic resonance imaging (MRI), which showed focal thickening of the roots of cauda equina at the level of the second lumbar vertebra, appearing isointense on T1W (Figure 1) and isointense on T2W (Figure 2), with marked homogeneous enhancement by gadolinium (Figure 3). It was performed a research for neoplastic cells in a sample of cerebrospinal fluid, being negative. Then, it was performed an open biopsy of the lesion by bilateral laminectomy direct on the site



**Figure 1:** Sagittal T1W MRI shows an isointense lesion affecting the cauda equine roots at L2 level.



**Figure 2:** Sagittal T2W MRI shows an isointense lesion affecting the cauda equine roots at L2 level.



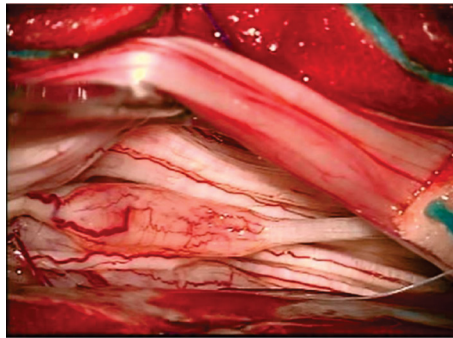
**Figure 3:** Sagittal T1 post-Gd MRI shows the thickened and highly enhanced roots of cauda equina at L2 level.

\*Corresponding author: Pedro Radalle Biasi, Av. Sete de Setembro, 65, ap 101 99010-121, Passo Fundo, RS, Brazil, Tel: +55 54 9617 2514; E-mail: [pedrobiasi@doctor.com](mailto:pedrobiasi@doctor.com)

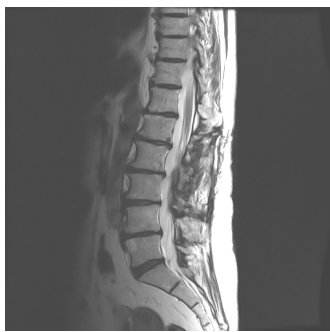Received October 28, 2015; Accepted November 27, 2015; Published November 30, 2015

**Citation:** Biasi PR, Lucena L, Espanhol RA, Almeida TAL, Brunet MP, et al. (2015) Cauda Equina Lymphoma – Case Report and Review of Literature. J Spine 4: 267. doi:10.4172/2165-7939.1000267

**Copyright:** © 2015 Biasi PR, et al. This is an open-access article distributed under the terms of the Creative Commons Attribution License, which permits unrestricted use, distribution, and reproduction in any medium, provided the original author and source are credited.



**Figure 4:** Open biopsy shows the thickened and swollen roots with anomalous and intense vascularization.



**Figure 5:** Sagittal T2W MRI shows the reduction of the thickening of the roots of cauda equina after chemotherapy and radiotherapy.

of the lesion, with intraoperative neurophysiological monitoring, being identified a nonfunctioning root for removal and analysis by freezing (Figure 4), which was suggestive of lymphoma, and then the procedure was interrupted. Immunohistochemistry analysis confirmed the diagnosis of Diffuse Large B-Cell Lymphoma. The patient underwent chemotherapy treatment based on 4 cycles of R-CHOP scheme - Rituximab, Cyclophosphamide, Vincristine, Doxorubicin and Prednisolone. A MRI performed 3 months after initiation of treatment shows reduction in the thickness of the affected roots (Figure 5). She remains stable until the date of this report.

## Discussion

A search by PCNSL and cauda equina lymphoma on the MEDLINE database shows only 17 cases reported to date [1-17]. The PCNSL is an extranodal non-Hodgkin Lymphoma (NHL) that may lie in the brain parenchyma, eyes, meninges or spinal cord in the absence of systemic disease. The central nervous system (CNS) is a rare site of involvement, accounting for 1-2% of NHL, which account for 1-7% of primary brain tumors. Less than one percent of cases of PCNSL affects the spinal cord, being more rarely affected the roots of cauda equina [1-6].

About 90-95% of PCNSL are histologically classified as diffuse large B-cell lymphoma which consistently express B-cell antigens and monotypic surface immunoglobulin light chains, and usually display positivity for MUM1 and BCL6 gene on chromosome 3q27 [2,3,5,7]. The symptoms are nonspecific and result from direct involvement or compression of the neural roots of cauda equina, with sub-acute evolution [2-4].

The MRI appearance is not characteristic, but can be evidenced the focal increase in volume of the roots of cauda equina, with intense contrast enhancement [2,3,15,18,19]. However, because most

tumors have abnormal contrast enhancement, it may not be possible to differentiate between lesions. Schwannomas have isointense signal on T1W and hyperintense on T2W, and usually shows more irregular enhancement compared with meningiomas due to internal necrosis and cystic degeneration. Meningiomas shows isointense signal on T1W and T2W, with intense contrast enhancement; and ependymomas are isointense on T1W and hyperintense on T2W, also with intense contrast enhancement. The differential diagnosis also occurs with other non-solid intradural lesions such as metastases, tuberculosis granuloma, toxoplasmosis and cryptococcosis, among others [2,3,6,18,19].

The CSF analysis plays important role in the diagnose of PCNSL. At least one of the routine CSF indices is abnormal in more than 80% of CNS lymphomas at the time of diagnosis. Elevated cell count (>10 cells/ $\mu$ L) or low CSF glucose level can be correlated with positive cytology results. Cerebrospinal fluid cytology can provide definitive diagnostic information in CNS lymphoma, and, with the aid of immunohistochemical studies, it has been possible to identify atypical lymphoid cells as monoclonal or neoplastic. The sensitivity of CSF cytology varies widely, and several technical factors can affect the yield of cytology as well as other CSF studies. Sensitivity improves when a larger volume ( $\geq 10.5$  mL) is analyzed and when serial CSF samples are evaluated; and is reduced when there are delays in processing or after exposure to corticosteroids, causing cytolysis [20].

Thus, it is essential for the diagnosis obtaining tissue for analysis [2-4]. In the open surgery, are evident thickened and swollen roots with anomalous and intense vascularization. After identification of affected roots, one piece should be removed and sent for analysis by freezing; this technique achieves about 90% of accuracy in the diagnose of lymphomas [21]. After intraoperative diagnostic confirmation, resection should be stopped because it is not effective and does not increase the chances of cure or survival [3,6]. The treatment is based on chemotherapy and radiotherapy, with methotrexate being the main agent [2,3,5,19].

As the prognosis is unfavorable, early diagnosis followed by combined treatment should be recommended, increasing the chances of survival and improvement of symptoms.

## References

1. Knopp EA, Chynn KY, Hughes J (1994) Primary lymphoma of the cauda equina: myelographic, CT myelographic, and MR appearance. *AJNR Am J Neuroradiol* 15: 1187-1189.
2. Morita M, Osawa M, Naruse H, Nakamura H (2009) Primary NK/T-cell lymphoma of the cauda equina: a case report and literature review. *Spine (Phila Pa 1976)* 34: E882-885.
3. Nakashima H, Imagama S, Ito Z, Ando K, Kobayashi K, et al. (2014) Primary cauda equina lymphoma: case report and literature review. *Nagoya J Med Sci* 76: 349-354.
4. Broen M, Draak T, Riedl RG, Weber WE (2014) Diffuse large B-cell lymphoma of the cauda equina. *BMJ Case Rep* 2014.
5. Nishida H, Hori M, Obara K (2012) Primary B-cell lymphoma of the cauda equina, successfully treated with high-dose methotrexate plus high-dose cytarabine: a case report with MRI findings. *Neurol Sci* 33: 403-407.
6. Teo MK, Mathieson C, Carruthers R, Stewart W, Alakandy L (2012) Cauda equina lymphoma-a rare presentation of primary central nervous system lymphoma: case report and literature review. *British Journal of Neurosurgery*. 26: 868-871.
7. Beitzke M, Enzinger C, Beitzke D, Neureiter D, Ladurner G, et al. (2010) Primary leptomeningeal lymphoma of the cauda equina: a rare cause of radiculopathy. *J Neurol* 257: 1734-1737.
8. Cugati G, Singh M, Symss NP, Pande A, Vasudevan MC, et al. (2012) Primary spinal intradural extramedullary lymphoma causing cauda equina syndrome. *J Craniovertebr Junction Spine* 3: 58-61.

9. Giobbia M, Carniato A, Scotton PG, Vaglia A, Marchiori GC (1999) Primary EBV-associated cauda equina lymphoma. *J Neurol* 246: 739-740.
10. Iwasaki M, Hida K, Yano S, Aoyama T, Kaneko S, et al. (2012) Primary cauda equina lymphoma treated with high-dose methotrexate. *Neurol Med Chir (Tokyo)* 52: 679-683.
11. Khong P, Pitham T, Owler B (2008) Isolated neurolymphomatosis of the cauda equina and filum terminale: case report. *Spine (Phila Pa 1976)* 33: E807-811.
12. Klein P, Zientek G, VandenBerg SR, Lothman E (1990) Primary CNS lymphoma: lymphomatous meningitis presenting as a cauda equina lesion in an AIDS patient. *Can J Neurol Sci* 17: 329-331.
13. Mauney M, Sciotto CG (1983) Primary malignant lymphoma of the cauda equina. *Am J Surg Pathol* 7: 185-190.
14. Ooi GC, Peh WC, Fung CF (1996) Case report: magnetic resonance imaging of primary lymphoma of the cauda equina. *Br J Radiol* 69: 1057-1060.
15. Tajima Y, Sudo K, Matumoto A (2007) Malignant lymphoma originating in the cauda equina mimicking the inflammatory polyradiculoneuropathy. *Internal Medicine* 46: 1029-1032.
16. Toner GC, Holmes R, Sinclair RA, Tang SK, Schwarz MA (1989) Central nervous system lymphoma: primary lumbar nerve root infiltration. *Acta Haematol* 81: 44-47.
17. Zagami AS, Granot R (2003) Non-Hodgkin's lymphoma involving the cauda equina and ocular cranial nerves: case reports and literature review. *J Clin Neurosci* 10: 696-699.
18. Zelenetz AD, Abramson JS, Advani RH, Andreadis CB, Byrd JC, et al. (2010) NCCN Clinical Practice Guidelines in Oncology: non-Hodgkin's lymphomas. *J Natl Compr Canc Netw* 8: 288-334.
19. Wager M, Lapierre F, Blanc JL, Listrat A, Bataille B (2000) Cauda equina tumors: a French multicenter retrospective review of 231 adult cases and review of the literature. *Neurosurg Rev* 23: 119-129.
20. Scott BJ, Douglas VC, Tihan T, Rubenstein JL, Josephson SA (2013) A systematic approach to the diagnosis of suspected central nervous system lymphoma. *JAMA Neurol* 70: 311-319.
21. Sugita Y, Terasaki M, Nakashima S, Ohshima K, Morioka M, et al. (2014) Intraoperative rapid diagnosis of primary central nervous system lymphomas: advantages and pitfalls. *Neuropathology* 34: 438-445.