

Case Report: The Clinical Application of a Surgical Navigation System for Implant-Prosthetic Rehabilitation of the Patient with Maxillary Lateral Incisors Agenesis

Patryk Kownacki¹, Tadeusz Morawiec¹, Iwona Niedzielska², Zbigniew Nawrat³, Rafał Rój^{4*} and Stefan Baron⁵

¹Department of Oral and Maxillo-Facial Surgery, Medical University of Silesia, Poland

²Department of Oral and Maxillo-Facial Surgery, Medical University of Silesia in Katowice, School of Medicine with the Division of Dentistry, Poland

³Foundation of Cardiac Surgery Development, Medical University of Silesia, Poland

⁴Department of Prosthetics and Dental Materials, Medical University of Silesia, Poland

⁵Department of Orthodontics and Temporomandibular Joint Dysfunction, Medical University of Silesia in Katowice, Poland

Abstract

Introduction: A precise transfer of planned procedures to a real operative field can be provided by surgical robots. This technology, still unique, is increasingly applied in new medical specialties. The aim of this paper was to describe the clinical application of an active navigation in the dental implant treatment.

Case Report: The patient was imaged by CBCT computed tomography Gendex GXCB-500/i-CAT while wearing an individually fitted interfacing acrylic splint. Thereafter, CT data were imported to the Image Guided Implantology System and precise 3-dimensional implant treatment plan was contemplated. This system allows real-time interactive carrying out of implantological procedures with three-dimensional visualization of the anatomical structures during the procedure.

Conclusions: The system of active navigation ensures the coordination of prosthetic and surgical treatment which guarantees optimal surgical and prosthetic effect of the therapy, including both anatomical structures and prosthetic requirements.

Keywords: Image guided implant surgery; Optical navigation; Tracking system; Intra-operative navigation.

Introduction

The rapid development of diagnostic methods enhanced by technical progress in medicine, coupled with the introduction of digital technology into everyday life, has changed an approach to planning and carrying out surgical procedures. Computer tomography images of high resolution with the use of suitable software allow virtual simulation of a planned procedure. A precise transfer of planned procedures to a real operative field can be provided by surgical robots [1,2]. This technology, still unique, is increasingly applied in new medical specialties. In oral surgery, likewise, the tendency is observed to decrease the number of surgeries with simultaneous increase in their precision [3]. It is realized by progressively wider application of microsurgical techniques, systems magnifying a microscopic image (micro-lenses, magnifiers), endoscopic techniques (sinusoscopy, arthroscopy, sialoendoscopy) and, recently introduced, surgical navigation (surgical templates, surgical robots) allowing for much more minimally invasive surgeries [4]. Surgical navigation has become applicable in dental implantology

where because of restricted operative field, and numerous adjacent structures (teeth and their buds, the nasal cavity, maxillary sinuses, the mandibular canal, mental foramina, the nasopalatal canal), the precision of surgical procedures is of special importance. It particularly refers to the cases of jaw bone atrophy. Slight errors during implant bed preparation may cause improper implant insertion which results in a number of complications [5-7]. Hence the need for precise planning of the surgery based on a detailed visualization of an operative field coupled with watching of the procedure progress on a monitor, and the possibility of correction of the performed procedure with reference to a planned pattern. Such a procedure is essential in the case of implantation carried out in the so-called "esthetic zone", that is, in the anterior part of the maxilla. Implantological restorations of congenital absence of maxillary lateral incisors is a great challenge for a surgeon. This genetic defect is usually accompanied by maxillary hypoplasia and underdeveloped alveolar process [8].

Case Report

The patient was imaged by CBCT computed tomography while wearing an individually fitted interfacing acrylic splint (Figure 1). Thereafter, CT data were imported to the Image Guided Implantology System (IGI; DenX Advanced Dental Systems Ltd, Moshav Ora, Israel),

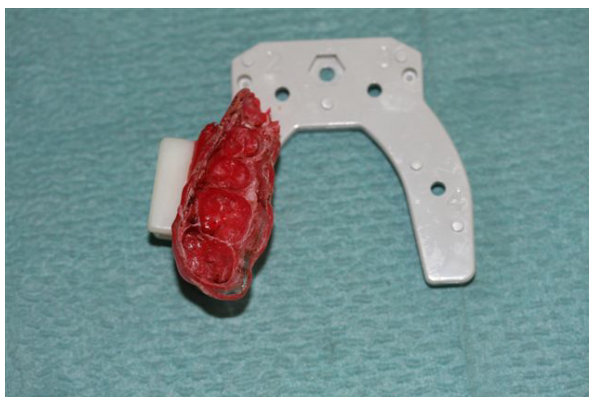

Figure 1: Individually fitted acrylic splint with interfacing template.

***Corresponding author:** Rafał Rój, Department of Prosthetics and Dental Materials, Medical University of Silesia, Poland, Tel: +48 32 252 17 39; E-mail: rafstoma@gmail.com

Received October 01, 2015; **Accepted** November 10, 2015; **Published** November 17, 2015

Citation: Kownacki P, Morawiec T, Niedzielska I, Nawrat Z, Rój R, et al. (2015) Case Report: The Clinical Application of a Surgical Navigation System for Implant-Prosthetic Rehabilitation of the Patient with Maxillary Lateral Incisors Agenesis. J Clin Case Rep 5: 650. doi:[10.4172/2165-7920.1000650](https://doi.org/10.4172/2165-7920.1000650)

Copyright: © 2015 Kownacki P, et al. This is an open-access article distributed under the terms of the Creative Commons Attribution License, which permits unrestricted use, distribution, and reproduction in any medium, provided the original author and source are credited.

and precise 3-dimensional implant treatment plan was contemplated considering the compromised anatomy and the anticipated prosthetic restoration (Figures 2 and 3). The surgeon selects the appropriate implant from the software menu. The IGI system for implant placement requires a fixed interfacing template to be mounted in the patient's mouth for the duration of surgery. This template creates the interface between the real patient and related dental computerized tomography data, enabling the intra-operative navigation. The template is then attached to a horseshoe shaped element consisting of ceramic markers. These markers are used as reference points between the CT data and a real patient. This template is supported by existing natural teeth. Following fabrication of the template, the patient undergoes a CT scan with the template

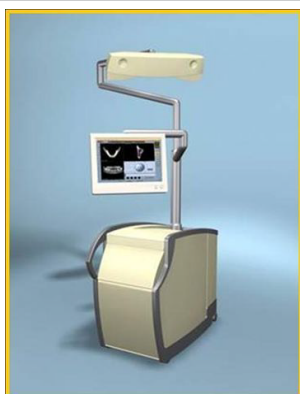

Figure 2: IGI system.

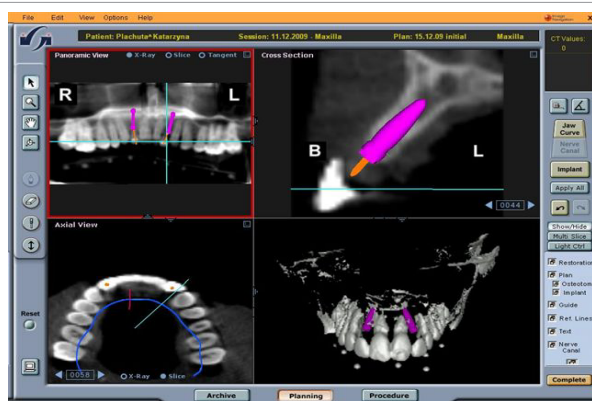


Figure 3: Computerized 3 dimensional implant planning stage in IGI software.

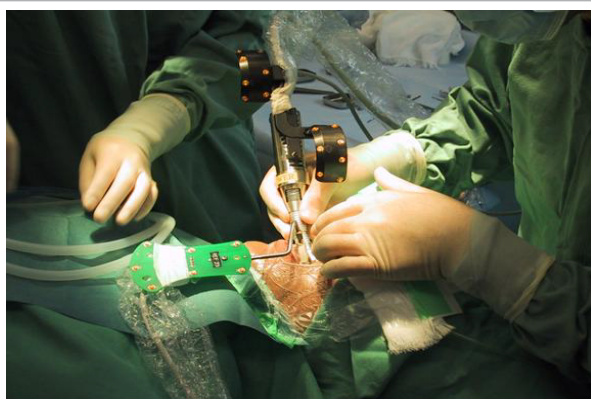


Figure 4: Handpiece and patient navigational tracker.

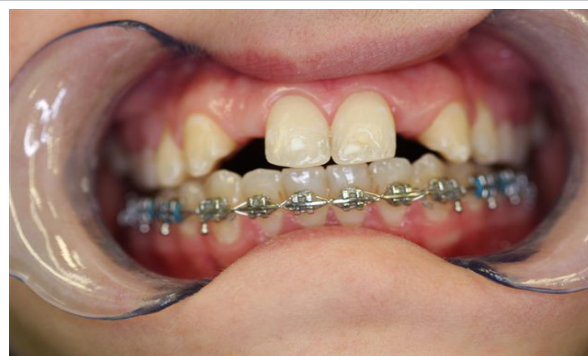

Figure 5: Intraoral radiograph of missing teeth 12 and 22.

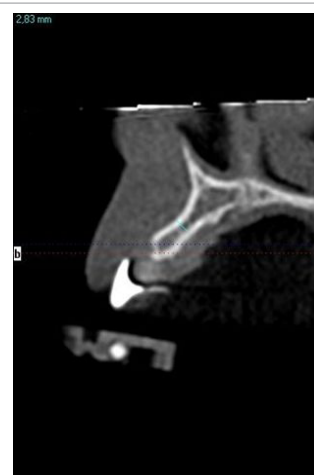

Figure 6: CBCT tomogram of deficient alveolar maxillary ridge.

mounted. A digital implant plan is based on the reconstructed dental scan of the patient and is created before the surgical procedure. The image of radiopaque teeth, which are part of the acrylic resin splint guides the decision on the planned position, angulation of the implants. Following registration the template with markers is detached from the acrylic splint leaving only the acrylic splint with the attachment of caps connected to the optical sensor. This enables ongoing monitoring of patients head position. Real imaging of dental drill is integrated with the anatomic structures and is consistently available to the surgeon with update progress of drilling. The surgeon uses an handpiece to which a Handpiece tracker is attached to enable real-time tracking by the system (Figure 4). The 28-year-old female patient with congenital absence of maxillary incisors was presented for implant-borne restoration. The gap for implant placement was opened at the end of orthodontic treatment. The CBCT examination revealed significantly reduced horizontally alveolar ridge in the region of missing teeth 12 and 22 (Figure 5). The CBCT image of hypoplasia resulting from agenesis of lateral maxillary incisors (Figure 6). To establish an appropriate implant site with a such reduced bone volume the initial indication was to augment the alveolar ridge in the region of tooth 12 and to perform the procedure with the use of surgical navigation system. Operation was performed under local anesthesia consisted of 4% articain (Ubistesin) solution. Full thickness mucoperiosteal flaps were reflected in the region of tooth 13-11 and 21-23 (Figure 7). Then considering the dimension of edentulous space, the osteotomies were prepared by means of cone-shaped bur according to the 3i drilling protocol for placement of two Nano Tite Implants (3,25 diameter x 11.5 mm length) with the use

of surgical navigation approach and precise coordination to the pre-surgical treatment plan (Figures 8a-b). The high primary stability was achieved in both implants. In region of 12 tooth the augmentation procedure was performed simultaneously with implant placement using Bio-oss material and Biogide membrane in GBR technique. The primary closure was performed with 4.0 GoreTex sutures. Six months post implant placement, the patient was then seen by prosthodontist for restorative treatment. Subsequently both implants were restored with full ceramic cement retained definitive crowns, using a pre-machined titanium alloy abutment, GingiHue Posts. Follow-up x-ray after 15 months shows a stable peri-implant bone situation (Figure 9). Clinical examination after 9 months revealed nice soft-tissue healing around the abutments and quite acceptable esthetic result (Figure 10a-10c).

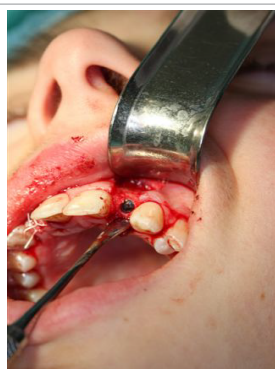


Figure 7: Intraoral radiograph of implant inserted in the tooth 22 position.

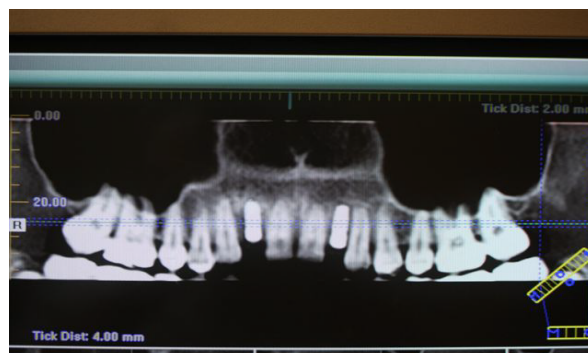

Figure 9: Orthopantomogram 15 months after implant restoration treatment.

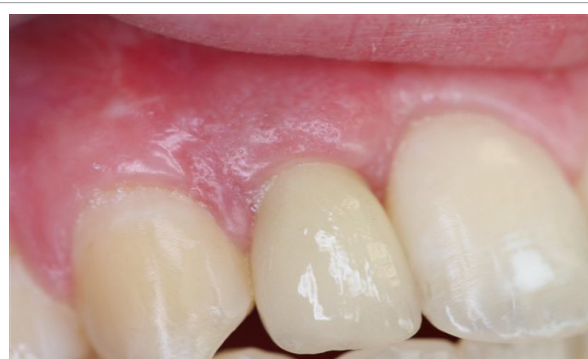

Figure 10a. Intraoral radiograph- Final outcome of the treatment. Final implant restoration in position 12.

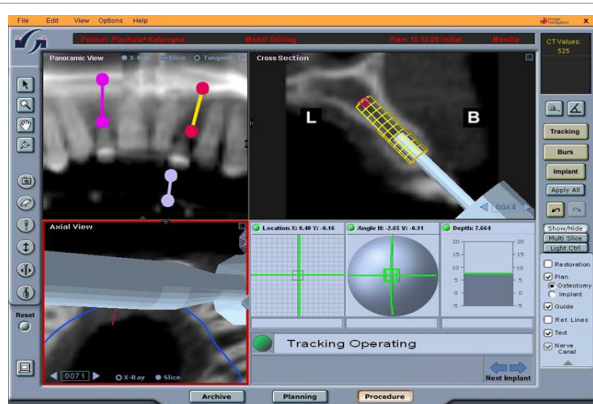


Figure 8a: Stages of implant bed preparation with the use of IGI navigation screen. Virtually planned implant position.

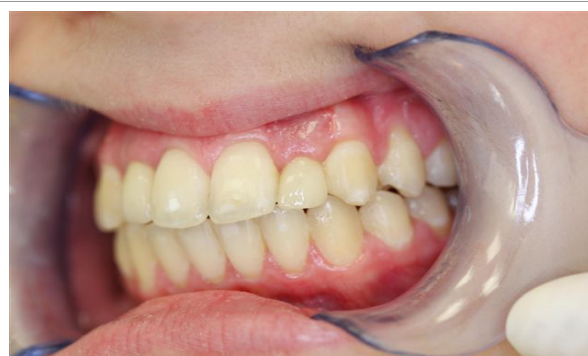

Figure 10b: Final restoration in position 22.

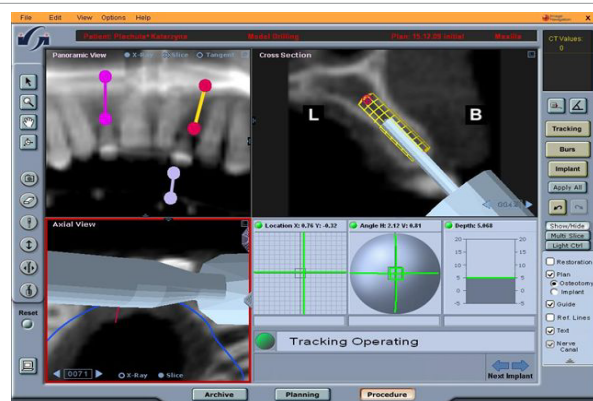


Figure 8b: Initial stage of implant bed preparation.

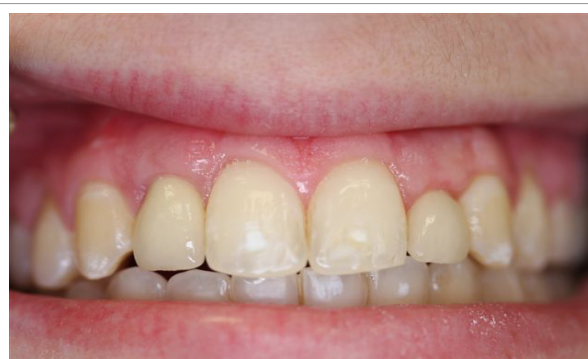

Figure 10c: Final implant supported crowns.

Discussion

Congenital absence of the second maxillary buds is a developmental defect occurring in about 10% of population, and in about 1.6% of the European population alone [9]. Hypodontia as a developmental defect of unknown etiology has been reported to be a result of dentition reduction during phylogenetic development. Computer guided surgeries with the use of optical navigation systems started their application with the development of neurosurgical surgeries requiring extreme precision [10,11]. Subsequently, due to the evolution of digitalization and progress in the application of computer software in reconstructive procedures and tooling of computer tomography imaging, these surgeries were introduced to various invasive specialties [12-14]. Intra-operative computer navigation allows precise transfer of the data from the planned surgery pattern onto the actual operative field. Success in the dentition reconstruction in esthetic zones with the use of dental implants depends on a number of factors. They include, among others, proper patient selection, the choice of a proper surgical technique, detailed analysis of the patient's anatomical features, concerning the soft tissues and underlying bone. However, the precision of the positioning of dental implants plays an essential role. The advantage of computer-assisted planning and carrying out of implantological procedures is three-dimensional visualization of the anatomical structures during the procedure. The surgery planning starts with the crowns of the missing teeth. The localization of the future crowns is visualized and all the details related to it are considered, including the positioning of implants, the depth of their insertion and the inclination angles in relation to the future prosthetic restoration and anatomical structures. Since the implant insertion takes into account prosthetic effect, this approach is called "prosthodontic-driven implant placement". It is based on the assumption that the dental implant is only the medium for the reconstruction of the absent tooth, and the expected prosthetic effect of the whole tooth should be taken into consideration. This integrates anatomical, biomechanical and esthetic effects. Surgeries with the use of the direct navigation technique facilitate precise implant positioning at the angle of future prosthetic reconstruction, which creates favourable conditions for full accommodation of the reconstruction, and not for the adaptation of the future prosthetic reconstruction to the implant position [15-17]. A navigation technique allows the operator to achieve full spatial orientation at every moment of the surgery and does not require surgical templates, which is known as a blind preparation through faucets in stereo-lithographic templates [18]. The interactive nature of full direct navigation with the use of the IGI optical system should be underlined since it ensures the possibility of intra-operative modifications. Such modifications are frequently necessary because virtual planning is made on the basis of computer tomography alone without a direct insight into the operative field. An experienced surgeon with appropriate knowledge and skills is able to evaluate whether the applied position of a drill is clinically acceptable and can make a correction of an already prepared plan (if necessary). In the case of indirect navigation, the use of templates limits a surgical procedure and the surgeon is not able to make any modifications [19-21]. Scientific and clinical investigations carried out on patients confirmed a mean linear accuracy of implant positioning in the IGI system which was less than 1 mm on the level of the implant neck and its apex and mean angular deviation was less than 4 degrees on condition that implantation was unrestricted by surgical templates equipped with faucets for implant insertion [22,23].

Conclusions

The system ensures the coordination of prosthetic and surgical

treatment which guarantees optimal surgical and prosthetic effect of the therapy, including both anatomical structures and prosthetic requirements. It is consistent with an accepted principle of three-dimensional implant localization, depending on a planned prosthetic reconstruction, and not on anatomical conditions alone. Moreover, this system during the procedure allows for the observation and control of the surgery, ensuring optimal surgical results, and in justifiable cases, allows for flapless surgery. For the first time navigation system enables the surgeon to show the actual drill position in the operation site on the 3D reconstructed image data set of the patient. Due to it the invasiveness of the procedure can be diminished, which is a proper surgical approach and satisfies the patients' expectations. On the basis of the above-presented considerations, the reports in the specialist literature as well as own clinical experience, we can conclude that the optical active navigation system is a unique tool which allows the surgeon to evaluate the diagnosis and prepare virtual simulation of all aspects of implantological treatment. Due to a precise planning of the whole treatment, the realization of the surgical protocol in a detailed and safe way becomes possible. It should also be noted that image-guided surgery in dental implantology is still infrequently used in routine dental practice, and the future will show whether it will become a standard procedure.

References

- Chen X, Wu Y, Wang C (2011) Application of a surgical navigation system in the rehabilitation of maxillary defects using zygoma implants: report of one case. *Int J Oral Maxillofac Implants* 2: e29-34.
- Nawrat Z (2012) State of the art in medical robotics in Poland: development of the Robin Heart and other robots. *Expert Rev Med Devices* 9: 353-359.
- Kang SH, Lee JW, Lim SH, Kim YH, Kim MK (2014) Verification of the usability of a navigation method in dental implant surgery: in vitro comparison with the stereolithographic surgical guide template method. *J Craniomaxillofac Surg* 42: 1530-1535.
- Falco A, Amoroso C, Berardini M, D'Archivio L (2015) A retrospective study of clinical and radiologic outcomes of 69 consecutive maxillary sinus augmentations associated with functional endoscopic sinus surgery. *Int J Oral Maxillofac Implants* 30: 633-638.
- Kurt BR (2014) Template guided surgery with the open-access software "smop". *Swiss Dent J* 124: 305-323.
- Kalra M, Aparna IN, Dhanasekar B (2013) Evolution of surgical guidance in implant dentistry. *Dent Update* 40: 577-578, 581-582.
- Rodríguez-Tizcareño MH, Barajas L, Pérez-Gásque M, Gómez S (2012) Esthetic considerations for the treatment of the edentulous maxilla based on current informatic alternatives: a case report. *J Calif Dent Assoc* 40: 509-517.
- Poeschl PW, Schmidt N, Guevara-Rojas G, Seemann R, Ewers R, et al. (2013) Comparison of cone-beam and conventional multislice computed tomography for image-guided dental implant planning. *Clin Oral Invest* 17: 317-324.
- Flores-Mir C (2006) Increased hypodontia through the twentieth century. *Evid Based Dent* 7: 15.
- Nardy C, Tarazi E, Wexler A, Sonnenfeld U, Lustmann J (2005) Intraoperative Computerized Navigation for Flapless Implant Surgery and Immediate Loading in the Edentulous Mandible. *The Int J Oral Maxillofac Implants* 20: 192-197.
- Rubio-Serano M, Albalat-Estela S, Penarrocha-Diago M, Penarrocha-Diago M (2008) Software applied to oral implantology: Update. *Med. Oral Patol Oral Cir Bucal* 13: 661-665.
- Yu HB, Shen GF, Zhang SL, Wang XD, Wang CT, et al. (2009) Navigation-guided gap arthroplasty in the treatment of temporomandibular joint ankylosis. *Int J Oral Maxillofac Surg* 38: 1030-1035.
- Nakamura K, Naya Y, Zenbutsu S, Araki K (2010) Surgical navigation using three-dimensional computed tomography images fused intraoperatively with live video. *Int J Endourol* 24: 521-524.
- Keereweer S, Sterenborg HJ, Kerrebijn JD, Va Driel PB (2011) Image-guided surgery in head and neck cancer: Current practice and future directions of optical imaging. *J Otolaryng Head Neck Surg* 31: 254-268.

15. Garber DA, Belser UC (1995) Restoration-driven implant placement with restoration-generated site development. *Compend Contin Educ Dent* 16: 796, 798-80, 804.
16. Siessegger M, Schnaider BT, Mischowski RA, Lazar F (2001) Use of image-guided navigation system in dental implant surgery in anatomical complex sites. *Int. J. Oral Maxillofac Surg* 29: 276-281.
17. Brief J, Edinger D, Hassfeld S, Eggers G (2005) Accuracy of image-guided implantology. *Clin Oral Implants Res* 16: 495-501.
18. Hassfeld S, Mühling J (2001) Computer assisted oral and maxillofacial surgery- a review and an assessment of technology. *Int J Oral Maxillofac Surg* 30: 2-13.
19. Wanschitz F, Birkfellner W, Watzinger F, Schopper C, Patruta S, et al. (2002) Evaluation of accuracy of computer-aided intraoperative positioning of endosseous oral implants in the edentulous mandible. *Clin Oral Implants Res* 13: 59-64.
20. Ewers R, Schicho K, Truppe M, Seemann R, Reichwein A, et al. (2004) Computer-aided navigation in dental implantology: 7 years of clinical experience. *J Oral Maxillofac Surg* 62: 329-334.
21. Nijmeh AD, Goodger NM, Hawkes D, Edwards PJ, McGurk M (2005) Image-guided navigation in oral and maxillofacial surgery. *Br J Oral Maxillofac Surg* 43: 294-302.
22. Casap N, Wexler A, Persky N, Schnaider A, Lustmann J (2004) Navigation surgery for dental implants: assessment of accuracy of the image guided implantology system. *Int. J. Cranio Maxillofac Surg* 62: 116-119.
23. Elian N, Jalbout ZN, Classi AJ, Wexler A, Sarment D, et al. (2009) Precision of flapless implant placement using real-time surgical navigation: a case series. *Int. J. Oral Maxillofac implants* 23: 1123-1127.