

Case Report: A Rare Presentation of Crohn's Disease and Thyroid Dyscrasias in A 51-Year-Old Female

Shawn Jaikaran M* and Rachel O Byrne

St. John's Hospital and Medical Centre, USA

Abstract

Reports have linked thyroid dyscrasias with inflammatory bowel disease and papillary carcinoma of the thyroid with Crohn's disease. Here is presented a rare case of a patient with co-existing hyperthyroidism, papillary carcinoma of the thyroid and Crohn's disease. After a 7-year history of Crohn's disease that was resistant to medical management our patient developed hyperthyroidism and through a thyroidectomy her pathology report relieved papillary carcinoma of the thyroid. To the best of our knowledge these three pathologies have not simultaneously been presented in the current literature. This association is a novel finding and with further advances in research, our approach towards patients with Crohn's disease might change.

Keywords: Inflammatory bowel; Papillary carcinoma of the thyroid; Crohn's disease; Thyroid

Introduction

Recent literature highlights an increased prevalence of thyroid dyscrasias and inflammatory bowel diseases. This association is better described in patients with ulcerative colitis and hyperthyroidism [1]. Other reports suggest an association between thyroid dyscrasias, such as hyperthyroidism and Crohn's disease [2-4]. Additionally, an emerging association has been reported between papillary carcinoma of the thyroid and Crohn's disease [5].

Case Report

The following is a rare case of a 51-year-old African American female with a coexisting hyperthyroidism, papillary carcinoma of the thyroid and Crohn's disease. This patient presented to the family medicine clinic in March of 2014 with the chief complaint of brittle hair. Her history of presenting illness was did not demonstrate any other symptoms of a thyroid dyscrasia. She also had no family history of thyroid disease. Her history was significant for a 7-year history of Crohn's disease since March of 2006 where she had ongoing medical and surgical treatment without relief. She also had a history of subclinical hyperthyroidism, since 2010. Thyroid studies were done periodically and did not show any signs of overt hyperthyroidism prior to her current visit. Her physical exam was only remarkable for a slightly enlarged thyroid gland upon palpation, with no palpable nodules.

A more detailed history of our patient's Crohn's disease reveals that following her diagnosis of Crohn's disease in 2006 her condition was medically managed with mesalamine and budesonide. In 2009, her medical treatment was advanced to adalimumab after severe abdominal pain and thin stools, but resulted in no significant relief. This prompted a CT scan in April of 2013, which demonstrated fistulas involving the distal ileum, adjacent colon, and multiple loops of the ileum (Figure 1). A decision was made to perform an ileocolic resection in June of 2013. Following surgery, the patient continued to have persistent loose bowel movements and she was advised to promptly continue adalimumab.

Following our patient's presentation to the family medicine clinic for brittle hair a thyroid dyscrasia was suspected, resulting in laboratory investigations. Her laboratory workup was significant for a TSH<0.01 mcunits/mL, FT3=5.32 pg/mL, FT4=1.92 ng/dL (normal values: TSH: 0.47-4.53 mcunits/mL, FT3 2.50-4.30 pg/mL, FT4 0.84-2.26 ng/dL), which indicated overt hyperthyroidism. Further lab

studies showed negative thyroglobulin antibodies and negative thyroid peroxidase antibodies. These findings prompted imaging studies that included a thyroid ultrasound showing a multi nodular goiter and a nuclear medicine scan. The nuclear medicine exam was remarkable for 4 hot nodules and a hyper functioning autonomous adenoma on the inferior aspect of the left thyroid (Figure 2). Shortly after this discovery, a total thyroidectomy was performed. The pathology report from her thyroidectomy relieved papillary carcinoma of the thyroid. It should also be noted that around this time the adalimumab injections were discontinued and infliximab infusions were started.

Discussion

To the best of our knowledge there are no case reports or studies

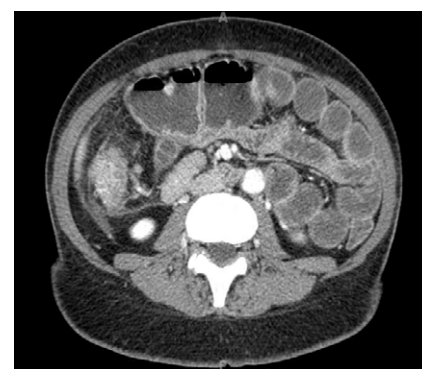


Figure 1: A CT scan with IV and PO contrast of the abdomen. This section of the abdomen represents the approximant level of the cecum. This particular image demonstrates a dilated segment of the small bowel that is tethered to an enteric fistula. The small bowel dilation measures approximately 5.1cm in diameter. This CT scan also demonstrates significant inflammation of the cecum that is depicted by fat stranding.

*Corresponding author: Shawn Jaikaran M, St John's Hospital and Medical Centre, USA, Tel: (313) 343-4000; E-mail: shawnjaikaran@gmail.com

Received August 07, 2014; Accepted September 11, 2014; Published September 15, 2014

Citation: Shawn Jaikaran M, Byrne RO (2014) Case Report: A Rare Presentation of Crohn's Disease and Thyroid Dyscrasias in A 51-Year-Old Female. J Clin Case Rep 4: 415. doi:10.4172/2165-7920.1000415

Copyright: © 2014 Shawn Jaikaran M, et al. This is an open-access article distributed under the terms of the Creative Commons Attribution License, which permits unrestricted use, distribution, and reproduction in any medium, provided the original author and source are credited.

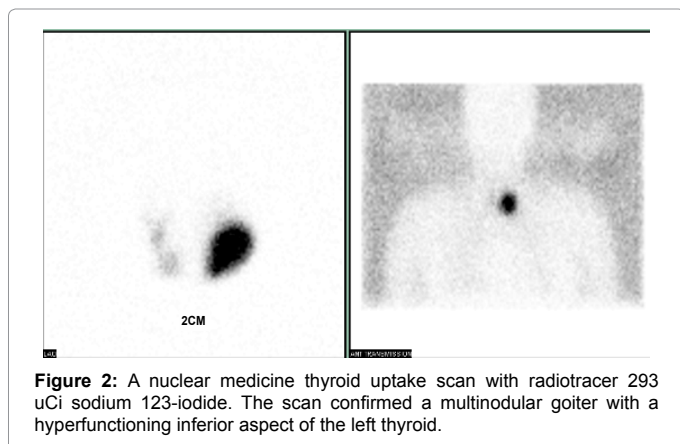


Figure 2: A nuclear medicine thyroid uptake scan with radiotracer 293 uCi sodium 123-iodide. The scan confirmed a multinodular goiter with a hyperfunctioning inferior aspect of the left thyroid.

in the literature that present a single patient with hyperthyroidism, papillary carcinoma of the thyroid and Crohn's disease. Proposed pathogenesis includes underlying immunological, non-immunological and even environmental factors; however none have been confirmed [2-5]. Within this rare association, particular attention should be paid to co-existing her hyperthyroidism and papillary carcinoma of the thyroid. These two pathologies co-occurring are noted to be very rare. Current literature suggests that thyroid cancer in a patient with a hyper functioning multi nodular carries an incidence as low as 1.8-8.8% [6].

With further advances in research, our approach towards

patients with Crohn's disease might change. For example, it might be appropriate for someone with newly diagnosed Crohn's disease to do a thyroid study to screen for subclinical or overt hyperthyroidism and address it accordingly. Our approach to treating Crohn's disease or hyperthyroidism in this fashion could potentially bypass the need for surgery and halt the progression of Crohn's disease or thyroid dyscrasias so that patients can live lives that are more comfortable.

References

1. Yakut M, Ustun Y, Kabacan G, Soykan I (2011) Thyroid Disorders in Patients with Inflammatory Bowel Diseases. *International Journal of Clinical Medicine*, 2: 89-92.
2. Inokuchi T, Moriwaki Y, Takahashi S, Tsutsumi Z, KA T, et al. (2005) Autoimmune thyroid disease (Graves' disease and hashimoto's thyroiditis) in two patients with Crohn's disease: case reports and literature review. *Intern Med* 44: 303-306.
3. Pachiadakis I, Nakos A, Tatsi P, Moschos J, Miliadis S, et al. (2009) Simultaneous occurrence of hyperthyroidism and fistulizing Crohn's disease complicated with intra-abdominal fistulas and abscess: a case report and review of the literature. *Cases J* 2: 8541.
4. Kettaneh A, Prevot S, Biaggi A, Stirnemann J, Fain O, et al. (2003) Hyperthyroidism in two patients with Crohn disease and Takayasu arteritis. *Scand J Gastroenterol* 38: 901-903.
5. Sonu IS, Blonski W, Lin MV, Lewis J, Aberra F, et al. (2013) Papillary thyroid cancer and inflammatory bowel disease: is there a relationship? *World J Gastroenterol* 19: 1079-1084.
6. Pazaitou-Panayiotou K, Michalakis K, Paschke R (2012) Thyroid cancer in patients with hyperthyroidism. *Horm Metab Res* 44: 255-262.