

Carotid Artery Injury: Up-to-Date Management

George Galyfos*, Ioannis Stefanidis, Stavros Kerasidis, Ioannis Stamatatos, Georgios Geropapas, Sotirios Giannakakis, Georgios Kastrisios, Gerasimos Papacharalampous and Chrisostomos Maltezos

Department of Vascular Surgery, KAT General Hospital, Athens, Greece

Abstract

Carotid artery injuries are not common in trauma patients although they are associated with a high morbidity and mortality. The practitioner needs to have a high level of suspicion in trauma patients with injuries of the neck and skull, and always taking into consideration the mechanism of injury. Prompt diagnosis and treatment are imperative for optimal results. This review aims to focus on main diagnostic and therapeutic strategies and produce useful conclusions on proper management.

Keywords: Carotid artery injury; Penetrating; Blunt; Open repair; Endovascular repair

Introduction

Vascular trauma of the neck is classified into two major categories, namely blunt or penetrating, according to the mechanism of vascular injury. Penetrating vascular trauma of the neck is observed mainly in males, and in 70-90% of all carotid injuries the damage is located in the common carotid artery. Morbidity and mortality rates are quite high in such cases. Concurrent injuries of adjacent structures are frequently observed, such as injury of the larynx or trachea (9%), larynx or oesophagus (4%), cervical spine (1%) and brachial neural plexus (2%). The types of carotid injury that could present in such patients include partial or full transection, formation of pseudoaneurysm, arteriovenous fistula, thrombosis, carotid dissection/intimal flap and peripheral embolism [1,2]. Additionally, blunt vascular injuries of the cervix present certain challenges concerning their management. They occur in 1-2.6% of blunt trauma cases. Moreover, blunt carotid injury has been associated with a high stroke rate (up to 60%) and mortality rate (19-43%). Many of these cases are asymptomatic and they remain undetected until symptoms of cerebrovascular ischemia present. Therefore, early screening and detection of such patients is justified. Finally, there is no consensus so far regarding proper therapy. Common mechanisms of such injuries are cervical overexpansion or rotation, immediate injury to the cervix, trauma within the oral cavity, base skull fracture or even trivial trauma in certain groups of patients (hypertension, Marfan syndrome, fibromuscular dysplasia etc.) [1,3]. Therefore, proper diagnostic and therapeutic management is imperative for optimal results.

Clinical Examination

Regarding clinical examination in cases with penetrating wounds, the identification of responsible instrument/weapon and mechanism of the injury, as well as the evaluation of the route and direction of damage are cornerstones for the prognosis of each case. External hemorrhage, pulsatile hematoma and auscultation of a murmur are obvious signs of bleeding. However, reduced pulses in the temporal or facial arteries, signs of hemothorax or bleeding from the larynx are subtle signs of cervical vascular trauma (Table 1). When an injury of the spine or a significant cerebral injury/ischemia coexists, neurological signs could be present such as paresis, paresthesias or even paralysis [1,2]. In cases of blunt injury, pain within the areas of the neck, ears or face can present in 60% of all patients. Bleeding through the oral cavity, nostrils or ears could be detected as well. Physical examination could reveal Horner syndrome due to pressure by the increasing hematoma. The auscultation of a cervical murmur in patients under 50 years of

Hard signs	Soft signs
Shock	History of bleeding (at the scene of the injury)
Refractory hypotension	Stable hematoma
Pulsatile bleeding	Nerve injury
Enlarging hematoma	Proximity of the injury track
Bruit	Unequal upper extremity blood pressure measurements.
Loss of pulse with stable or evolving neurologic deficit	

Table 1: Signs indicating carotid artery injury.

age should raise suspicion of a blunt carotid injury. Almost one third of such patients could present with a cerebrovascular infarct that could not be justified otherwise. Over 80% of these patients will present a cerebrovascular event within the first 7 days from the injury, according to literature. In cases of blunt carotid trauma and dissection, only 10% of cases present symptoms immediately although most clinical signs occur within 24 hours of the cervical injury [1,4].

Furthermore, the classification of cervical vascular injuries into zones has added a very important and useful algorithm into everyday clinical practice (Figure 1). Zone I extends from the level of the clavicles up to the level of the cricoids cartilage, zone II from the cricoids cartilage up to the angle of the jaw, and finally zone III begins over the level of the jaw angle. Injuries of the Zone II could be evaluated with physical examination where a major vascular injury can be verified or excluded without difficulty. However, immediate clinical evaluation of injuries located in Zones I and III is difficult, and therefore further diagnostic imaging is required. It is estimated that physical examination yields a 93% sensitivity and 97% negative prognostic value for the prediction of angiographic results independently from the zone of trauma [2,5].

Regarding prognosis, there are also several clinical risk scores in order to predict the possibility of carotid artery injury in patients with blunt cervical trauma (Table 2). The Denver group has produced the most widely used classification for blunt cervical trauma in the literature [1]. Although this index seems to be the most efficient and complete to date, several other indices such as the Memphis or Kerwin

***Corresponding author:** George Galyfos, 2 Nikis Street, Kifisia, 14561, Athens, Greece, Tel: +302132086243; Fax: +30210770757; E-mail: georgegalyfos@hotmail.com

Received January 05, 2016; **Accepted** January 25, 2016; **Published** January 28, 2016

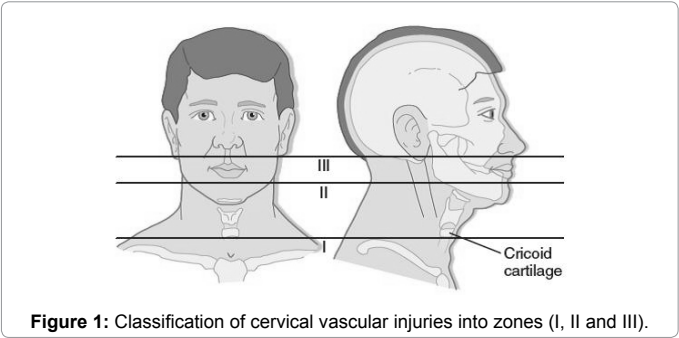
Citation: Galyfos G, Stefanidis I, Kerasidis S, Stamatatos I, Geropapas G, et al. (2016) Carotid Artery Injury: Up-to-Date Management. J Trauma Treat 5: 283. doi:10.4172/2167-1222.1000283

Copyright: © 2016 Galyfos G, et al. This is an open-access article distributed under the terms of the Creative Commons Attribution License, which permits unrestricted use, distribution, and reproduction in any medium, provided the original author and source are credited.

criteria (Table 2) have been proposed. Although the aforementioned indices share most of the included risk factors such as neurologic status inconsistent with computed tomography imaging, severe soft tissue injury/hematoma of the neck, high grade facial fractures and high risk mechanism of injury, they show some differences as well. Biffi et al have added some new criteria such as Glasgow Coma Scale < 6 or diffuse axonal injury [6]. In the latter algorithm, when one of the included risk factors is present, there is 41% risk for carotid injury although the risk

risks to 93% when all the factors are present. More important is that the number of risk factors present is strongly associated with increasing stroke and mortality risk [6]. Hence, cerebrovascular spasm remains a major factor for outcome as well as it occurs right after injury and it worsens cerebrovascular ischemia [1,6].

Finally, research data indicate that progression rate of carotid injury is strongly associated with the severity of the injury [1]. Moreover, data show that the median time to diagnosis of carotid injury is estimated to be 12.5 hours for survivors and 19.5 hours for nonsurvivors. Therefore, according to many authors, early aggressive screening of trauma patients is justified. However, certain criteria should be utilized in order to identify certain candidates with the highest possibility for vascular trauma and thus reduce costs as well as the necessity for resources. The aforementioned risk indices can be utilized to facilitate such screening strategies yielding a high sensitivity and specificity. Data indicate that aggressive screening yields a diagnostic performance of 30-45% in some series [7]. The identification of patients in higher risk should indicate further diagnostic investigation utilizing imaging modalities in order to verify the carotid injury and proceed with proper treatment.



	Denver criteria	Memphis criteria	Kerwin criteria	Biffi's modified criteria
Signs/symptoms	<ul style="list-style-type: none">-Arterial hemorrhage from neck/nose/oral cavity-Expanding hematoma-Cervical bruit (age < 50)-Focal neurologic deficits-Neurologic deficits inconsistent with CT findings-Stroke on CT/MRI	<ul style="list-style-type: none">-Neurologic exam not explained by brain imaging-Horner syndrome-Neck soft tissue injury	<ul style="list-style-type: none">-Massive epistaxis-Neck hematoma-Anisocoria-Unexplained mono-/hemiparesis-Neurologic exam not explained by brain imaging-Cerebrovascular accident or TIA	<ul style="list-style-type: none">-GCS < 6
Risk factors	<ul style="list-style-type: none">-Displaced LeFort II or III fracture-Mandible fracture-Complex skull fracture with involvement of carotid canal-Closed head injury with diffuse axonal injury and GCS < 6-Cervical spine fracture-Brain injury with thoracic injuries-Scalp degloving-Blunt cardiac rupture-Thoracic vascular injuries-Clothes line-type injury or seat belt abrasion	<ul style="list-style-type: none">-LeFort II or III fracture-Skull base fractures involving foramen lacerum-Cervical spine fracture-Neck soft tissue injury	<ul style="list-style-type: none">-Massive facial fractures-Basilar skull base fracture through or near carotid canal-Foramen transversarium fracture-Severe flexion or extension of cervical fracture	<ul style="list-style-type: none">-LeFort II or III fractures-Petrous fracture-Diffuse axonal injury

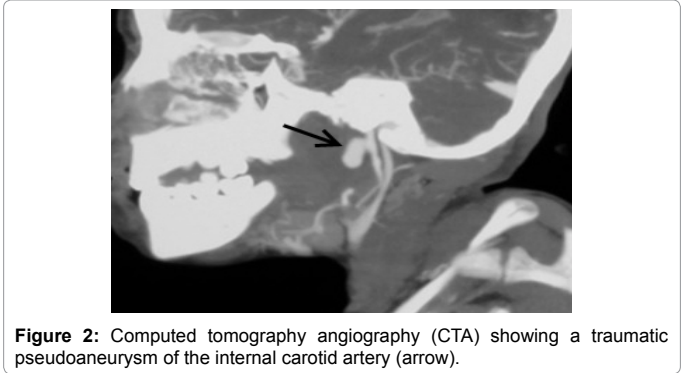
CT: Computed Tomography; MRI: Magnetic Resonance Imaging; GCS: Glasgow Coma Scale; TIA: Transient Ischemic Attack

Table 2: Comparison of major screening risk scores for carotid artery injury [1,13].

Diagnostic Imaging

Regarding proper diagnostic investigation, coloured duplex ultrasonography is an operator-dependent method and therefore, it is not always a standard choice although reliable results are reported by experienced operators [1,8]. However, it remains a non-invasive modality with a high disposability even in smaller rural hospitals. Especially for blunt injuries, it provides a poor vision of the intracranial aspects of a dissection and it also gives limited information about small intimal tears. Finally, when it comes to dissections of the ICA, the sensitivity of diagnostic ultrasound is even lower [9]. According to Guidelines, computed tomography angiography (CTA) is suggested as an initial screening modality, although there are studies showing a low sensitivity and specificity [6]. However, CTA gives important information concerning the injury of adjacent structures as well as distal perfusion, and therefore it is justified in severely injured patients who would undergo plain CT for excluding concomitant cerebral or vertebral injury [10,11]. Additionally, CTA could be utilized as a screening tool for patients with penetrating cervical trauma. According to Harrigan et al, the most popular imaging method for patients with blunt cervical injuries was CTA as it was selected in almost 60% of cases in a large series of more than 11,000 patients (Figure 2) [12].

However, the golden standard for patients with blunt injuries remains digital angiography (DSA) according to many authors [1]. DSA offers the clinician the ability to accurately rule out the presence of carotid injury with a 97% diagnostic performance and can also permit intervention via endovascular techniques when indicated [13].



However, DSA remains an invasive method with a complication rate of approximately 1%, resource intensive, and is not readily available at many hospitals, especially small institutions without an endovascular suite. Therefore, many suggest CTA followed by DSA for inconclusive cases or when an endovascular repair is indicated (Figure 3) [6].

Another useful imaging modality is magnetic resonance angiography (MRA). Especially for blunt trauma, it determines dissections in up to 99% and provides additional information about concomitant injuries (i.e. brain injuries, fractures, etc.). A recent review demonstrates that MRA is equal to CTA in the diagnosis of carotid and vertebral dissection [14]. However, there are limited data concerning penetrating vascular trauma of the neck in literature. Furthermore, MRA is not available in all institutions as an emergency diagnostic tool and there are certain limitations regarding the longer duration of the scan and the existence of metal objects within the trauma or the upper body of the patient such as fragments, implants or pacemakers [1].

Finally, there is an extracranial carotid artery injury classification that is based on radiologic findings (Grades):

- I. Luminal irregularity with <25% luminal narrowing
- II. >25% Luminal narrowing, intraluminal thrombus or related intimal flap
- III. Pseudoaneurysm formation
- IV. Occlusion of the vessel
- V. Vessel transection; each of the aforementioned groups is associated with certain stroke and mortality rates as well. The most common groups are I) and III). However, occlusion (group IV) is associated with almost 44% stroke rate and 22% mortality rate. As expected patients with transection show almost 100% stroke and mortality rates [4].

Treatment

Treatment of carotid artery injury has been described in literature almost four centuries ago. Ligation of carotid artery has been reported from the early 1600s (Ambrose Pare), and it was preferred as the major

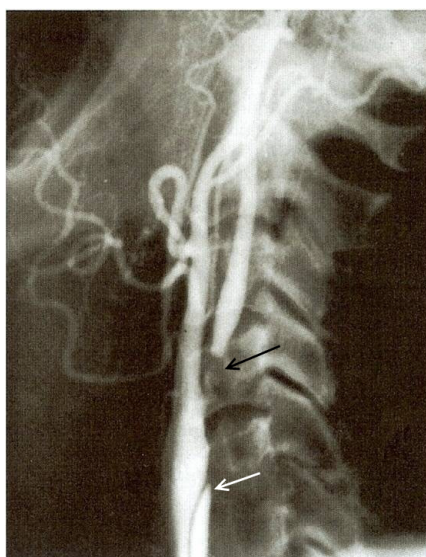


Figure 3: Digital angiography showing a posttraumatic obstruction of the internal carotid artery (black arrow) and a dissection of the common carotid artery (string sign; white arrow).

surgical treatment until almost fifty years ago. During both World Wars, many case series have been reported of vascular arterial trauma in the neck. In the series described by Makins in 1919, 128 cases of carotid ligation were presented with 30% of them showing irreversible neurologic deficit postoperatively. During the second World War, however, the first reports of surgical repair without ligation were recorded [1,15].

Penetrating injuries

When signs of external hemorrhage are present, applying an external immediate pressure on the wound and cervix is the first and most important measure. However, when the patient is in coma, its status deteriorates significantly or a long transportation is scheduled, tracheal intubation should be taken into consideration [1]. Nowadays, surgical repair of penetrating injuries includes primary suturing, end-to-end anastomosis, suturing of a venous patch or interposition of a venous or synthetic graft when the carotid wall is significantly damaged (Grades III-V). Most of penetrating injuries in Zone II need to be investigated on the operating table. According to Reva et al. [16], surgical repair should be pursued even in asymptomatic patients with a penetrating injury. Concerning small pseudoaneurysms or endothelial flaps (Grades II-III), almost one third of them recover without any interference or any complication. However, serial evaluation with duplex ultrasonography is imperative in such cases. Finally, the initiation of antiplatelet treatment in cases of penetrating injuries remains still controversial. Furthermore, there is still a certain debate concerning the surgical management of patients with concomitant neurologic deficit. Several authors used to advocate that the restoration of carotid flow could transform an ischemic infarct caused by the injury into a hemorrhagic lesion [17]. However, a large number of studies have questioned this theory and therefore, it is now recommended to proceed with operation even in such patients [16].

Finally, endovascular treatment of penetrating carotid injuries has been increasingly supported in the literature recently [18], especially in stable patients and cases with injuries of Zone III. However, only small studies have been published so far. According to du Toit et al. [19], relative contraindications include uncontrollable hemorrhage, injuries of the respiratory and digestive tract, infected wounds and a threatened airway.

Blunt injuries

Regarding the proper treatment of blunt injuries, there is no recommendation suggesting plain observation anymore. Accumulated data based on level III evidence have shown a beneficial effect of antithrombotic therapy in preventing cerebral infarction [8]. In minor injuries (Grade I-II), antiplatelet or anticoagulative treatment should be initiated. In Grades III or higher, antithrombotic treatment in combination with endovascular repair is suggested. However, Grade V injuries request immediate open repair, as expected [13]. Recent data show that antiplatelet and anticoagulative agents show similar efficacy in such injuries [20]. Unfortunately, contraindications to anticoagulants and antiplatelet agents in patients with multisystem injury, including the presence of intracranial hemorrhage, often complicate the treatment paradigm within the trauma population. Therefore, the time to start with the anticoagulation should be considered in an interdisciplinary approach (vascular surgeons, orthopedic surgeons, neurologists, neurosurgeons and radiologists) in such high-risk cases.

Concerning the proper management of a dissection, thrombosis or pseudoaneurysm (Grades II-III) due to blunt trauma, data have been controversial. Although older research literature suggested that surgical

repair yielded better results compared to conservative treatment, more recent data recommend conservative therapy with heparin administration followed by per os anticoagulants for 3-6 months [8,21]. However, anticoagulants are contraindicated in polytrauma patients due to the high complication risk (up to 33%) in such patients [1,13]. Therefore, endovascular stenting has been suggested in patients with refractory or expanding pseudoaneurysms, cases under conservative treatment that present new neurologic deficits, and cases with contraindication for anticoagulant treatment [15].

Finally, Moulakakis et al. [8] have developed a very useful algorithm according to which an imaging examination should be repeated after 7-10 days of conservative treatment, and based on the aforementioned indications, endovascular treatment could be considered. This strategy is justified as the endovascular repair carries certain risks as well. Intraoperative adverse events as well as long-term stent occlusion in patients with blunt injuries that is more common than in patients treated conservatively, should be taken into consideration [8]. Therefore, endovascular stenting also requires pre- and posttreatment antiplatelet coverage to avoid embolic complications or stent occlusion. This often results in a frustrating clinical conundrum because many patients are referred for endovascular repair specifically due to contraindications to antithrombotic therapy such as severe intracranial injury or multisystem trauma.

Conclusions

Careful initial examination and diagnostic investigation is imperative in carotid artery injuries management. Proper treatment includes conservative, open as well as endovascular repair, according to patient's characteristics and status, mechanism and type of injury as well as findings in diagnostic imaging. Therefore, treatment of such patients should be individualized in order to yield optimal outcome.

References

- Lee TS, Ducic Y, Gordin E, Stroman D (2014) Management of carotid artery trauma. *Craniofac Trauma Reconstr* 7: 175-189.
- Azuaje RE, Jacobson LE, Glover J, Gomez GA, Rodman GH Jr, et al. (2003) Reliability of physical examination as a predictor of vascular injury after penetrating neck trauma. *Am Surg* 69: 804-807.
- Kessoku H, Umibe A, Anazawa U, Takaishi S, Hachisu T, et al. (2014) A case of blunt common carotid artery injury following minor trauma. *Nihon Jibiinkoka Gakkai Kaiho* 117: 1115-1119.
- Scott WW, Sharp S, Figueroa SA, Eastman AL, Hatchette CV, et al. (2015) Clinical and radiographic outcomes following traumatic Grade 3 and 4 carotid artery injuries: a 10-year retrospective analysis from a Level 1 trauma center. The Parkland Carotid and Vertebral Artery Injury Survey. *J Neurosurg* 122: 610-615.
- Asensio JA, Valenziano CP, Falcone RE, Grosh JD (1991) Management of penetrating neck injuries. The controversy surrounding zone II injuries. *Surg Clin North Am* 71: 267-296.
- Biffi WL, Cothren CC, Moore EE, Kozar R, Cocanour C, et al. (2009) Western Trauma Association critical decisions in trauma: screening for and treatment of blunt cerebrovascular injuries. *J Trauma* 67: 1150-1153.
- Miller PR, Fabian TC, Croce MA, Cagiannos C, Williams JS, et al. (2002) Prospective screening for blunt cerebrovascular injuries: analysis of diagnostic modalities and outcomes. *Ann Surg* 236: 386-393.
- Moulakakis KG, Mylonas S, Avgerinos E, Kotsis T, Liapis CD (2010) An update of the role of endovascular repair in blunt carotid artery trauma. *Eur J Vasc Endovasc Surg* 40: 312-319.
- Mohan IV (2014) Current optimal assessment and management of carotid and vertebral spontaneous and traumatic dissection. *Angiology* 65: 274-283.
- Bodanapally UK, Dreizin D, Sliker CW, Boscak AR, Reddy RP (2015) Vascular Injuries to the Neck After Penetrating Trauma: Diagnostic Performance of 40- and 64-MDCT Angiography. *AJR Am J Roentgenol* 205: 866-872.
- Ofer A, Nitecki SS, Braun J, Daitzchman M, Goldsher D, et al. (2001) CT angiography of the carotid arteries in trauma to the neck. *Eur J Vasc Endovasc Surg* 21: 401-407.
- Harrigan MR, Weinberg JA, Peaks YS, Taylor SM, Cava LP, et al. (2011) Management of blunt extracranial traumatic cerebrovascular injury: a multidisciplinary survey of current practice. *World J Emerg Surg* 6: 11.
- Bromberg WJ, Collier BC, Diebel LN, Dwyer KM, Holevar MR, et al. (2010) Blunt cerebrovascular injury practice management guidelines: the Eastern Association for the Surgery of Trauma. *J Trauma* 68: 471-477.
- Provenzale JM, Sarikaya B (2009) Comparison of test performance characteristics of MRI, MR angiography, and CT angiography in the diagnosis of carotid and vertebral artery dissection: a review of the medical literature. *AJR Am J Roentgenol* 193: 1167-1174.
- Martinakis VG, Dalainas I, Katsikas VC, Xiromeritis K (2013) Endovascular treatment of carotid injury. *Eur Rev Med Pharmacol Sci* 17: 673-688.
- Reva VA, Pronchenko AA, Samokhvalov IM (2011) Operative management of penetrating carotid artery injuries. *Eur J Vasc Endovasc Surg* 42: 16-20.
- Navsaria P, Omoshoro-Jones J, Nicol A (2002) An analysis of 32 surgically managed penetrating carotid artery injuries. *Eur J Vasc Endovasc Surg* 24: 349-355.
- Herrera DA, Vargas SA, Dublin AB (2011) Endovascular treatment of penetrating traumatic injuries of the extracranial carotid artery. *J Vasc Interv Radiol* 22: 28-33.
- du Toit DF, Coolen D, Lambrechts A, de V Odendaal J, Warren BL (2009) The endovascular management of penetrating carotid artery injuries: long-term follow-up. *Eur J Vasc Endovasc Surg* 38: 267-272.
- Wahl WL, Brandt MM, Thompson BG, Taheri PA, Greenfield LJ (2002) Antiplatelet therapy: an alternative to heparin for blunt carotid injury. *J Trauma* 52: 896-901.
- Burlew CC, Biffi WL, Moore EE, Pieracci FM, Beauchamp KM, et al. (2014) Endovascular stenting is rarely necessary for the management of blunt cerebrovascular injuries. *J Am Coll Surg* 218: 1012-1017.