

Cardiac Surgery in a Patient with Influenza Pneumonia

Sowmya Sridharan¹, Nitin Bansal¹, P Senthur Nambi², Dhamodharan³, and M Ytsuf

Department of Cardiology Institute of Infectious Diseases, Apollo Hospitals, Tamil Nadu, Chennai

Abstract

Managing a patient with active influenza with surgical emergencies poses a challenge to both treating clinician and infection control preventionist. Active influenza in the perioperative period is known to increase morbidity, but very little literature exists which describes the infection control aspect of the same. Here, we present the infection control aspect of a patient of acute coronary syndrome requiring emergency cardiac bypass surgery who also had influenza A (H3N2).

Keywords: Surgical emergency • Influenza • Infection control

Introduction

Influenza infection during surgery have shown to affect the outcomes in terms of increased length of stay and increased chances of admission into critical care unit [1]. Apart from the post-op complications, these patients also throw a challenge in terms of infection control. It is a general consensus to delay the elective surgery till patient recovers from active influenza, but delaying surgery may not be feasible in case of emergency situations like the case presented here.

Case Study

This 63 year old diabetic gentleman was referred to our hospital (tertiary care centre in South India) as a case of inferior wall myocardial infarction with failed thrombolysis. On arrival to the emergency department he was found to be in cardiogenic shock (BP - 80/50 mmHg, PR- 120/min) and severe respiratory distress with hypoxia (SpO₂- 88% on room air) (Figure 1). He underwent an emergency coronary angiography which revealed critical triple vessel disease An intra-aortic balloon pump was placed and he was shifted to coronary care unit for further management. On review of history he had fever, cough followed by breathlessness 2 days prior to this event. As, there was an on-going epidemic of influenza, we tested him for the same and he was found to have H3N2 infection (confirmed by PCR from endotracheal tube secretion). He was started on oseltamivir and was shifted to a respiratory isolation room (negative pressure with health care personnel wearing N95 masks for patient care contacts). Considering his triple vessel disease and his unstable hemodynamics, he needed urgent coronary bypass surgery. He was shifted to operation theatre after 3rd day of hospitalization where we ensured that all healthcare personnel involved in the surgery were vaccinated prior for influenza that year and HCPs involved wore N95 masks. His case was taken in the evening session of the OT, and it was ensured that no other case was on-going during that time. In addition, all healthcare professionals (HCP) involved in his care were offered oseltamivir post exposure prophylaxis. He recovered well and was discharged after 7 days of stay in the hospital. We did not encounter any in-hospital transmission of influenza during his stay.

***Address for Correspondence:** Sowmya Sridharan, Department of Cardiology Institute of Infectious Diseases, Apollo Hospitals, Tamil Nadu, Chennai, Tel : +91 99622 31818, E-mail: kesowmya@yahoo.com

Copyright: © 2021 Bansal N, et al. This is an open-access article distributed under the terms of the Creative Commons Attribution License, which permits unrestricted use, distribution, and reproduction in any medium, provided the original author and source are credited.

Received 22 February 2021; Accepted 08 March 2021; Published 15 March 2021

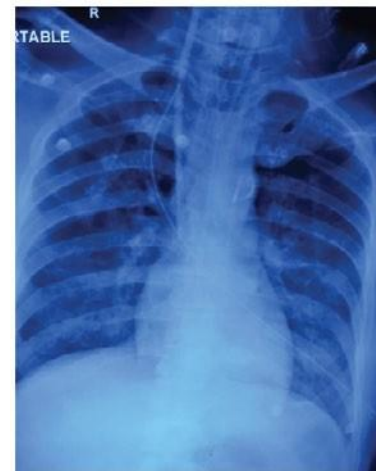


Figure 1. Chest X ray (AP view) of the patient showing bilateral interstitial infiltrates.

Result and Discussion

Medical literature is flooded with data on various epidemiological, clinical and prevention strategies on influenza but very little literature is available on surgical issues on patients with active influenza. Study done by Spaeder et. al showed that pediatric patients with active influenza and respiratory syncytial virus infection in the perioperative period had increased length of stay and increased chances of unplanned ICU admission [1]. In another case series, patients with common surgical emergencies (traumatic epidural hematoma, intestinal obstruction and cutaneous mucormycosis) along with influenza infection had poor outcomes [2]. Galbraith et. al also reported a case of influenza and acute appendicitis which had a prolonged hospital stay [3].

Influenza is a primarily a community based infection and is transmitted among households and in community settings. Transmission of influenza occurs through large particle droplets which require close contact between source and recipients (6 feet). Indirect transmission can also occur through hand transfer via contaminated surfaces. However, in healthcare settings, especially when patient is on mechanical ventilation, aerosolization can occur leading to air-borne transmission [4]. Administration of influenza vaccine and strict adherence to infection-control practices during patient-care activities and aerosol-generating procedures are pillars to prevent health care personnel from acquiring influenza infection and onwards transmission [5]. Aerosol generating procedures like, bronchoscopy or endotracheal tube suctioning should be done preferably in a room with negative pressure (minimum of 12 air exchanges per hour), air from these rooms should be exhausted directly to the outside or be filtered through a high-efficiency particulate air (HEPA) filter before recirculation, minimize human traffic into the room, and all HCP should wear respiratory protection equivalent to a fitted N95 filtering face piece respirator and have received yearly influenza vaccination [6]. The challenge

in this case was prevention of transmission in an operating room with positive pressure ventilation.

Although, there are small studies and case reports on surgical emergencies in patients with active influenza, but none highlight the aspect of infection control [1-3].

Conclusion

This case highlights the importance of infection control in operation theatres and also emphasizes that active influenza infection should not be a hindrance in surgical emergencies.

Acknowledgement

Conflict of Interest

Nil

References

1. Spaeder, Michael C, Lockman Justin L, Greenberg Robert S, and Fackler James C, et al. "Impact of perioperative RSV or Influenza Infection on Length of Stay and Risk of Unplanned ICU Admission in Children: A Case-Control Study." *BMC anesthesiy* 11 (2011): 1-4.
2. Person, Benjamin, Bahouth Hany, Brauner Eran, and Ben-Ishay Offir, et al. "Surgical Emergencies Confounded by H1N1 Influenza Infection-A Plea for Concern" *World J Emerg Surg* 5 (2010): 1-4.
3. Galbraith, JG, Butler J S, Pead M, and Twomey A. "H1N1 Infection in Emergency Surgery: A Cautionary Tale." *Int J Surg Case Rep* 1 (2010): 4-6.
4. Killingley, Ben, and Nguyen-Van-Tam Jonathan. "Routes of Influenza Transmission." *Influenza and other respiratory viruses* 7 (2013): 42-51.
5. Jones, Rachael M. "Critical Review and Uncertainty Analysis of Factors Influencing Influenza Transmission." *Risk Analy: An Int J* 31 (2011): 1226-1242.
6. Voirin, Nicolas, Cécile Payet, Alain Barrat, and Ciro Cattuto, et al. "Combining High-Resolution Contact Data with Virological Data to Investigate Influenza Transmission in a Tertiary Care Hospital." *Infect Control Hosp Epidemiol* 36 (2015): 254-60.

How to cite this article: Sridharan, Sowmya, Nitin Bansal, P Senthur Nambi, Dhamodharan and MYusuf. "Cardiac Surgery in a Patient with Influenza Pneumonia." *J Interv Gen Cardiol* 5(2021):122.