

# Cardiac Hydatidosis in a 57-Year-Old Woman

Milouchi R<sup>1</sup>, Sghaier A<sup>1\*</sup>, Ajmi H<sup>1</sup>, Jabloun TY<sup>1</sup>, Ferjani S<sup>1</sup>, Ben Habib A<sup>2</sup> and Zidi A<sup>2</sup>

<sup>1</sup>Habib Bourguiba Hospital, Tunisia

<sup>2</sup>Charles Nicole Hospital, Tunisia

## Abstract

Hydatidosis is a parasitic infection due to the development of the larval form of *Echinococcus granulosus*. It is still a public health problem in endemic countries, particularly around the Mediterranean. The diagnosis is sometimes delayed. This depends on the hydatid site and the on the symptoms. But it relies essentially on the existing imaging techniques. The cardiac localization is rare. In most of the cases it is found on the left ventricle (LV). We report the case of an intramyocardial hydatidosis in a 57-year-old patient who had been suffering from an on-exertion dyspnea with chest pain for over 5 years. The patient underwent a resection of the cyst by sternotomy under extracorporeal circulation. Albendazole, an anti-parasitic medical treatment, was prescribed postoperatively. Histopathological examination confirmed the diagnosis of pericardial hydatid cyst. Postoperative control imaging demonstrated an intra-myocardial residual cyst.

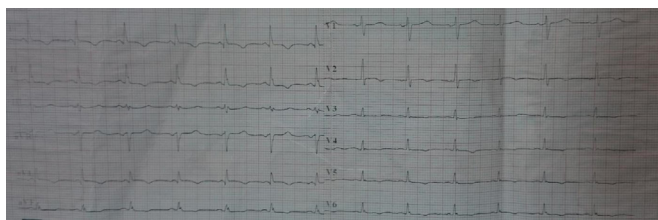
**Keywords:** Cardiac hydatid cyst; Extracorporeal circulation; Pulmonary embolism

## Introduction

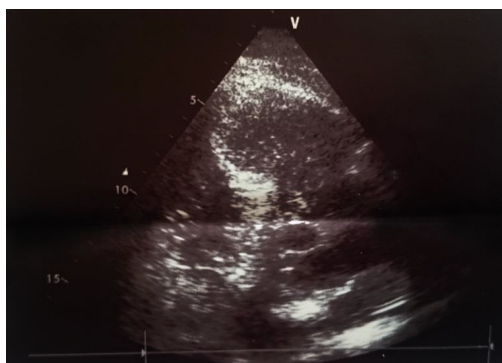Cardiac hydatidosis is extremely rare even in endemic countries (<3%). Main symptoms are dyspnea, chest pain, and altered general status. The Diagnosis is mainly based on imaging data. The LV localization is the most frequent (50% to 60%). Dreaded complications consist mainly of a rupture in the cardiac cavities with the parasite dissemination into the pulmonary or systemic circulation and a rupture in the pericardium. The treatment is essentially surgical. Medical treatment is useful as an adjuvant therapy or in case of non-operability.

## Case Report

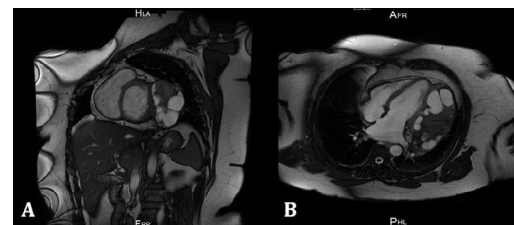
A 57-year-old patient, from a rural environment, had been experiencing on-exertion dyspnea of progressive aggravation and chest pain since 2010. The medical examination found a good general



**Figure 1:** Poor R wave progression with negative lateral side T waves.



**Figure 2:** An anechoic formation measuring 10.2 cm of diameter, located at the apex of the LV lateral wall.



**Figure 3:** Cardiac MRI revealing a multi-vesicular-intra-myocardial hydatid cyst, developed on the side wall of the LV.

condition, the cardiopulmonary auscultation was without abnormalities and there were no signs of heart failure. Chest X-rays showed cardiomegaly. On the ECG, there were poor R wave progression with lateral negative side T waves (Figure 1). Hypereosinophilia at 2000 E/L was observed, and the CRP was negative. On the echocardiography, an anechoic formation measuring 10.2 cm of diameter, located at the apex of the LV lateral wall was noted (Figure 2). A thoracic CT-scan had found a mediastinal mass attached to the LV free wall, coming into contact with the anterior thoracic aorta measuring 12.5 × 5.5 × 8.5 cm. It is multi-partitioned and surrounded by a thick wall without contrast enhancement, presenting some calcifications on its posterior pole. An MRI revealed a multi-vesicular-intra-myocardial hydatid cyst, developed on the side wall of the LV. The Spur sign was present. The thickness of the myocardium was preserved, calculated at 1 cm. This cyst was 13 cm long. It had an extension to the posterior mediastinal space and to the anterior cardiophrenic angle, having an intimate contact with the anterior interventricular artery without any sign of invasion. No pericardial effusion was objectified (Figure 3).

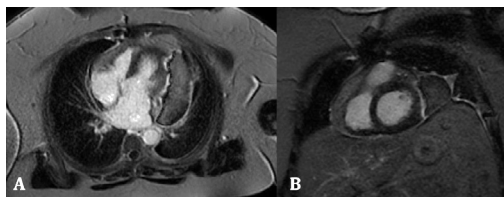
The patient was operated on October 28<sup>th</sup>, 2015 by median sternotomy under extracorporeal circulation. The cyst had intimate relations with the pericardium and the left phrenic nerve. Its aspiration

**\*Corresponding author:** Ahmed Sghaier, Habib Bourguiba Hospital, Tunisia, Tel: +21674241511; E-mail: [sghahmed991@gmail.com](mailto:sghahmed991@gmail.com)

**Received** April 13, 2017; **Accepted** May 22, 2017; **Published** May 27, 2017

**Citation:** Milouchi R, Sghaier A, Ajmi H, Jabloun TY, Ferjani S, et al. (2017) Cardiac Hydatidosis in a 57-Year-Old Woman. J Clin Case Rep 7: 967. doi: [10.4172/2165-7920.1000967](https://doi.org/10.4172/2165-7920.1000967)

**Copyright:** © 2017 Milouchi R, et al. This is an open-access article distributed under the terms of the Creative Commons Attribution License, which permits unrestricted use, distribution, and reproduction in any medium, provided the original author and source are credited.



**Figure 4:** Cardiac MRI revealing a persistent 10 × 3 cm hydatid cyst on the side wall of the LV: Long axis 4 chamber view 2D mode (A) small axis view 2D mode (B).

brought back a gelatinous liquid and thousands of vesicles. The toilet was made by oxygenated water. The dissection of some secondary masses contained several cysts especially posteriorly connected to each other by few millimeters-long collars. The resection of the outer-shell was only made on the apical half as the rest of it was very thick and well adherent to the various structures evoked. Anatomopathological examination confirmed the diagnosis of cardiac hydatidosis. Surgical outcome was marked by the installation at the 4th day of a dyspnea with desaturation. A thoracic angio-scan showed a distal pulmonary embolism. The patient was ultimately put on Albendazol. A 4-month MRI control found a persistent 10cmx3cm hydatid cyst on the side wall of the LV with an extension to the posterior inframediaastinal space, containing floating membranes. The side wall of the VG is thinned to a minimum thickness of 4mm. A postoperative recurrence is likely to be (Figure 4).

## Discussion

Cardiac hydatidosis remains a rare disease even in endemic areas. It represents <3% of the usual sites. After passing through the hepatic filter, the larval form of *Echinococcus granulosus* reaches the right atrium and hence the left heart by the pulmonary circulation or even by a permeable foramen ovale. From the left ventricle, the larvae are expelled in the systemic circulation. Through the coronary arteries, the parasite invades the myocardium [1]. The parasite is located, in order of frequency, in the left ventricle (50% to 60%), the interventricular septum (10% to 20%), the right ventricle (5% to 15%), the pericardium (10% to 15%) and the atria (5% to 8%) [2].

The symptomatology is non-specific and varied, and it's related to the number, size and site of the cysts [3]. It includes chest pain, palpitations, on-exertion dyspnea and signs of congestive heart failure

mimicking valvulopathy [3] or anaphylactic reaction [4]. Asymptomatic forms have also been reported [2-4].

The evolving risk to serious complications requires a rapid diagnosis and a surgical management. The transesophageal echocardiography [5] is an efficient examination, showing an anechoic-thin-walled formation and can define its topography. Floating membranes or a multi-vesicular aspect are highly suggestive of the diagnosis. If echocardiography is the key examination, the use of CT scan or MRI is necessary to rule out other diagnoses of cystic masses [3,6]. To other authors, intraoperative echocardiography is of an inestimable value [5].

The treatment of cardiac hydatidosis is essentially surgical. It consists of the cyst excision to avoid complications that can be fatal in case of rupture, even when it comes to asymptomatic patients [1,2,6]. Medical treatment is the treatment of choice for patients who are not operable due to excessive hydatid cysts or to a certain debility, or as a complementary treatment for surgery when there is a risk of spread. The most commonly used product is Albendazole® at a dose of 10 mg/kg/day to 15 mg/kg/day. The postoperative prognosis is generally favorable but the recurrence is described [3] as is in the case of our patient.

## Conclusion

Cardiac localization of hydatidosis is rare, the symptomatology is not specific and sometimes delayed. The diagnosis is based on imaging data, and the treatment is surgical.

## References

1. Rosenberg T, Panayiotopoulos YP, Bastounis E, Papalambros E, Balas P (1993) Acute abdominal aorta embolism caused by primary cardiac echinococcus cyst. Eur J Vasc Surg 7: 582.
2. Cantoni S, Frola C, Gatto R (1993) Hydatid cyst of the intraventricular septum of the heart: MR Findings. AJR 161: 753-754.
3. Orhan G, Ozay B, Tartanet Z (2008) Cardiac hydatid cyst surgery: Thirty-nine years' experience. Anna Cardiol Angei 57: 58-61.
4. Kardaras F, Kardara D, Tselikos D (1996) Fifteen-year surveillance of echinococcal heart disease from a referral hospital in Greece. Eur Heart J 17: 1265-1270.
5. Birincioglu CL, Bardakci H, Kucuker SA (1999) A clinical dilemma: Cardiac and pericardiac echinococcosis. Ann Thorac Surg 68: 1290-1294.
6. Chellaoui M, Bouhouch R, Akjouj M (2003) Pericardial hydatidosis: About 3 cases. J Radiol 3: 329-331.