

# Buerger's Disease: Autoimmune Disease Involving Multiple Hypersensitivity Types

Portia Ping Zheng\* and Wanchao Wang

Department of Immunology, School of Medicine affiliated Ruijin Hospital, Shanghai Jiao Tong University, Buffalo, NY, USA

## Abstract

**Background:** Buerger's disease is an autoimmune disease? And what is the immunological pathogenesis? It has not been deeply researched but still attracts the attention of scholars. In our early study we reported that TAO may be an autoimmune disease involving hypersensitivity Type III and Type IV.

**Methods:** In this study we further explored the immune pathogenesis of TAO based on initial research.

**Results:** We detected humoral immunity (Ig E) in 28 cases using Enzyme-Linked Immunosorbent Assay (ELISA). Antigen-antibody complex depositing on the vessel wall in 18 cases, and anti-vessel antibodies in 28 cases using three kinds of immune-labeling techniques (immunofluorescence labeling, immunoenzymatic staining and immuno-gold-silver staining). The result shows Ig E levels were significantly high ( $P < 0.01$ ). As high as 86% of anti-vessel antibodies in serum were found ( $P < 0.001$ ), and the auto-antibodies against the vessel were combined directly with vascular collagen. Antigen-antibody complexes deposited on the vascular wall.

**Conclusions:** These findings further confirm TAO is an autoimmune disease involving multiple hypersensitivity reactions. This is mainly Type III hypersensitivity and type II in addition to type IV. The elevated Ig E suggest that TAO may a type I hypersensitivity involved.

Trial registration: Not applicable.

**Keywords:** Thromboangiitis obliterans • Autoimmune disease • Humoral immunity • Immune-labeling techniques • Type III, IV, II, I hypersensitivity reaction

## Introduction

### Definition

Leo Buerger first described Buerger's disease (TAO or thromboangiitis obliterans) in 1908. TAO is an inflammatory disease of small and medium-sized blood vessel walls accompanied by thrombosis, and it primarily involves the limbs. Historically, the disease occurs more often in young men, and the severe pain from TAO has led to drug abuse and limb loss; Major limb amputation occurs in nearly 20% of cases [1]. TAO has a global yet uneven distribution [1]. In North America and Western Europe, TAO accounts for 0.75% to 5.6% of peripheral vascular diseases. However, in Eastern Europe, the Middle East, the Mediterranean, and Asia, it accounts for 60% to 80% of peripheral vascular diseases and may be associated with the use of certain types of tobacco [1]. Interestingly, the incidence of TAO in women has risen in accordance with an increase in cigarette smoking among women [1]. The incidence of TAO is also associated with economic development, as evidence suggests a correlation with improvements in nutrition; most patients in these populations are malnourished [2,3].

It is more difficult to treat TAO in its acute stages; therefore, it is important to study its pathogenesis. Researchers have recently paid special attention to immune pathogenesis. We conducted a previous study exploring TAO as an autoimmune disease involving type III related to antigen-antibody complex deposited on the vessel wall and type IV delayed hypersensitivity related to sensitized T cells and releasing lymphokines [4]. This study further explores the pathogenesis of TAO as an autoimmune disease and its mechanism.

**\*Address for Correspondence:** Dr. Portia ping Zheng, Department of Immunology, Shanghai Jiao Tong University, School of Medicine affiliated Ruijin Hospital, Buffalo, NY, USA

**Copyright:** © 2022 Zheng PP, et al. This is an open-access article distributed under the terms of the creative commons attribution license which permits unrestricted use, distribution and reproduction in any medium, provided the original author and source are credited.

**Received:** 11-May-2022, Manuscript No. JCRE-22-63530; **Editor assigned:** 16-May-2022, Pre QC No. JCRE-22-63530 (PQ); **Reviewed:** 02-June-2022, QC No. JCRE-22-63530; **Revised:** 09-June-2022, Manuscript No. JCRE-22-63530 (R); **Published:** 16-June-2022, DOI: 10.37421/2795-6172.2022.S1.003.

## Materials and Methods

### Patients

Our study included 74 men patients, aged 21 to 50 years, with a history of TAO lasting 2 to 28 years. Patients had a recurrence history ranging from 1 to 6 times, with a recent onset within 1 to 10 months. The diagnosis of TAO was based on the following criteria: the onset occurred when the patient was 20 to 40 years old, the patient reported being a smoker, the symptoms were usually accompanied by migratory superficial phlebitis in an extremity, symptoms and signs of ischemia in the limbs were present, and other peripheral vascular diseases (such as arteriosclerosis obliterans, diabetic foot) were excluded. In some cases, a TAO diagnosis was confirmed by pathological findings.

We obtained biopsy blood vessel tissue from superficial phlebitis and from limb amputation from TAO patients. 18 cases of antigen-antibody (Ag-Ab) complex deposition, and 28 cases of anti-vessel auto-antibodies detected. Patients in this study were in the acute and sub-acute stages. 28 cases of Ig E patients were assigned to 3 groups: acute TAO (n=5), sub-acute TAO (n=17), and chronic TAO (n=6).

### Observations and methods

We used Enzyme-Linked Immunosorbent Assay (ELISA) to detect humoral immunity (IgE) in 28 patients who had no other allergic disorders. There are healthy people as a control group.

We used 3 types of immune labeling techniques to accurately detect Ag-Ab complex depositions on the vessel walls for 18 patients. We used Immunofluorescence (IF) labeling, where samples of patient vessels were fixed in cooling alcohol (95%) and embedded in low-temperature paraffin. The specimens were then sectioned via pancreatic digestion and direct immunofluorescence staining. Prepared samples were observed under fluorescent microscopy. Using a similar technique, we also evaluated samples using immunoenzymatic staining (avidin-biotin complex, ABC staining) and Immuno-Gold-Silver Staining (IGSS), assessed via a light microscope.

For the detection of anti-vessel autoantibodies, healthy vessel tissue

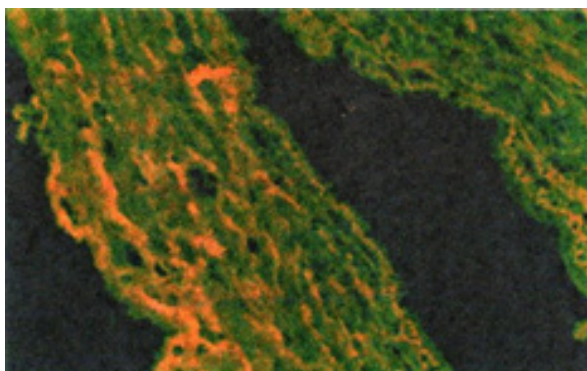
served as an antigen substitute. The serum from 28 TAO patients was used as the first antibody, rabbit antihuman Fluorescein Isothiocyanate (FITC-Ig), ABC-Ig, and IGSS-Ig were used as secondary antibodies. We used indirect staining for all samples.

The control serum was obtained from healthy volunteer blood donors at Shanghai Rui-Jin Hospital. The healthy vessel tissue was obtained from healthy controls through biopsy or amputation from patients at Shanghai Rui-Jin Hospital. Other control comparators included rabbit serum substitution for human serum, buffer solution substitution for human serum, anti-mouse Ab substitution for Ab labeling, buffer solution substitution for Ab labeling, and saline as a blank control. We conducted paired t-tests and determined the mean and standard deviations. P-values <0.05 were considered statistically significant, P<0.01 was highly significant, and P<0.001 was extremely significant.

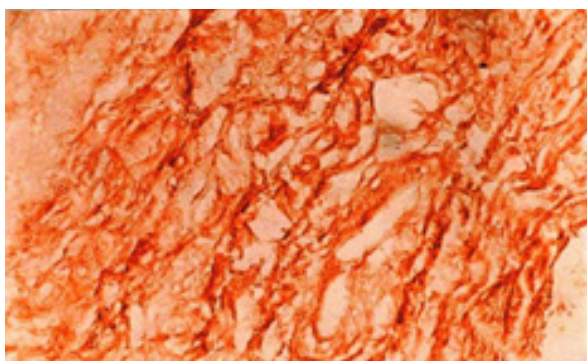
## Results

Ig E levels were highly significantly elevated in all groups (P<0.01) and significantly elevated in the subacute and chronic TAO groups (P <0.05).

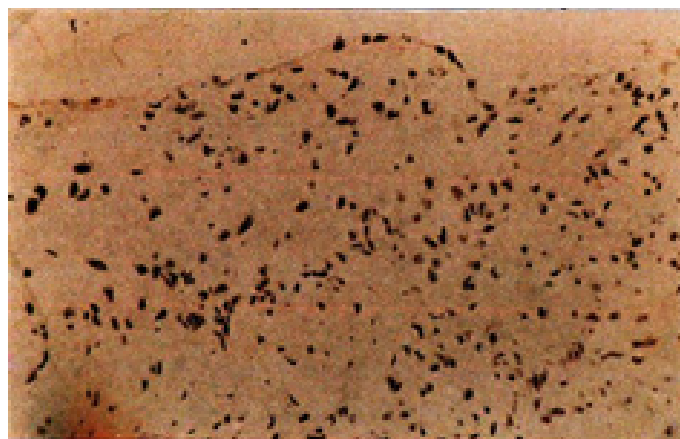
All immune-labeling techniques found Ag-Ab complex deposition on the vessel walls. IF staining findings are illustrated in Figure 1. ABC labeling results are illustrated in Figure 2. To demonstrate the results of IF and to exclude the nonspecific cross-reaction, we observed section staining with the ABC method simultaneously. The ABC results were identical to those found with IF staining. The results of the IGSS evaluation are illustrated in Figure 3 and were identical to the IF and ABC findings. The IGSS technique showed good specificity and sensitivity. In most vessels, we could see thickening of the intima, stenosis of the cavity, and the organization and recanalization of the thrombus in the vascular cavity. We also noted disorder of the structure, changing of media, fiber proliferation, and pathological changes of all layers to various degrees along with local damage, breakdown, disappearance, and a large number of streaky particles or patches deposited in all layers-among which the fluorescent intensity of IgG and IgM was strong. The controls were negative.



**Figure 1.** Deposits with yellowish-green striped, lumpy and particle-shaped immunofluorescence on TAO vascular wall (IF 400X).

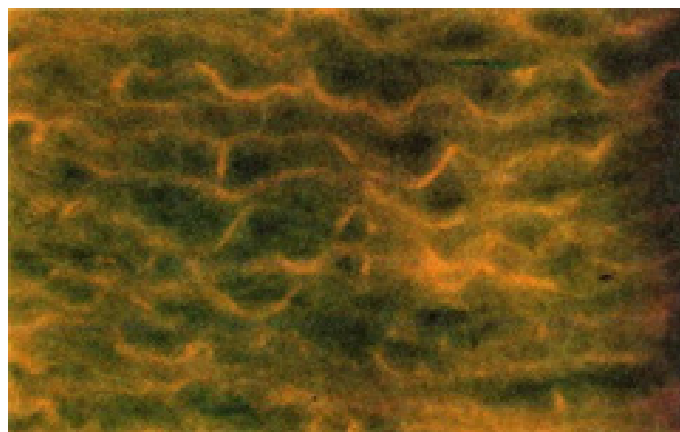


**Figure 2.** Deposits with striped, lumpy substance of brown-yellowish on TAO vascular wall in immunoenzymatic staining (ABC 400X).

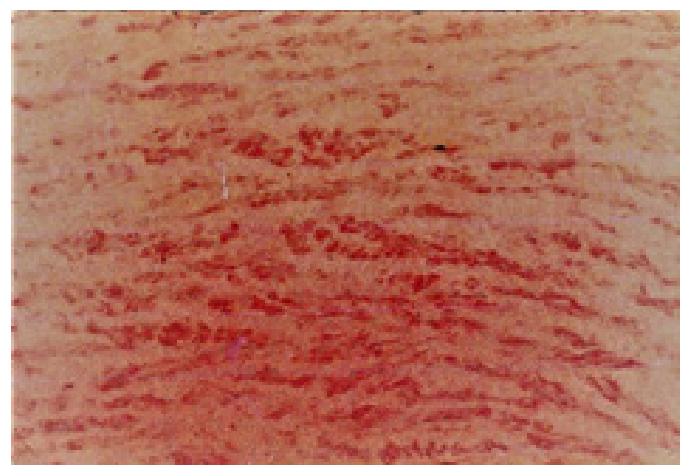


**Figure 3.** Deposits with particles and small black stripes substance on TAO vascular wall in immuno-gold-silver staining (IGSS 400X).

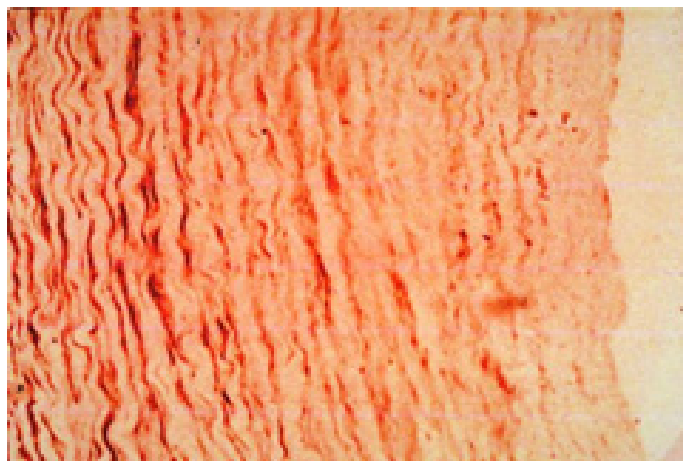
The results of our anti-vessel auto-antibodies assessments are illustrated in Figures 4-6. Anti-vessel auto-antibodies were presented in 72% to 86% of TAO samples (P<0.001). The auto-antibodies against the vessel were combined directly with vascular collagen (as seen in Figures 4-6). The specificity and sensitivity of the IGSS method were better than those of the IF and ABC methods.



**Figure 4.** FITC-Ig appears yellow-green combined with the healthy vessel wall (IF 200X).



**Figure 5.** ABC-anti-Ig appears brownish-red combined with the healthy vessel wall (avidin-biotin complex stain, ABC 200X).



**Figure 6.** Gold-anti-Ig appears as small, black stripes and particles combined with the healthy vessel wall (IGSS 200X).

## Discussion

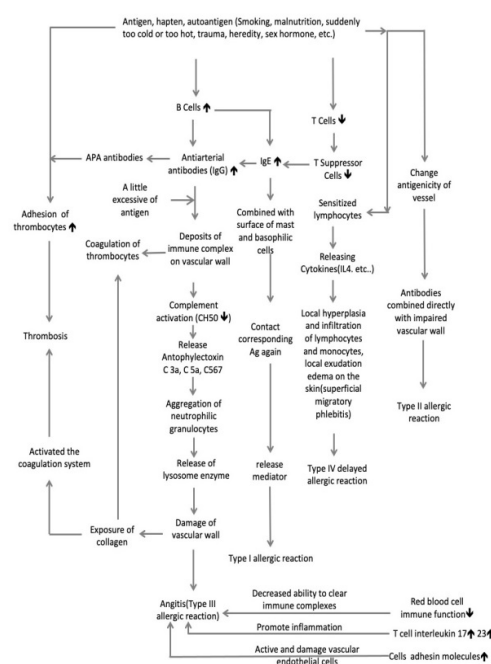
Various antibodies in TAO have been reported, including anti-endothelial cell antibodies, anti-neutrophil cytoplasmic antibodies, anti-phospholipid antibodies, anti-cardiolipin antibodies, and agonistic auto-antibodies directly against the G-protein coupled receptor [5-9]. TAO is associated with elevated cytokine levels of Tumor Necrosis Factor (TNF)-, Interleukin (IL)-1 $\beta$ , IL-4, IL-6, IL-17, and IL-23 [10,11]. TAO is also associated with an increased expression of vascular cell adhesion molecules, intracellular adhesion molecules, and E-selectin on the endothelial cells of the affected arteries [12]. Kobayashi et al. reported IgG, IgA, IgM, and complement factors C3d and C4c deposit along the internal elastic lamina, and cell infiltration was observed in the thrombus and the intima of patients with TAO (CD3+ T cells greatly outnumbered CD20+ B cells, CD68+ macrophages or S-100+ dendritic cells) [13]. Fu, et al. found that TAO patients have low erythrocyte immune function, so the erythrocytes are less able to adhere to the circulating immune complex, and Cui, et al. found an immune complex deposit in the vessel wall under electron microscopy, which aligns with our findings [4,14,15]. The evidence suggests TAO pathogenesis involves humoral and cellular immunity, with TAO vessel cell immune response activation, inflammation, damage, and thrombosis. Immunosuppressive agents suppress the immune response in TAO patients [16]. The use of immunoabsorption to remove TAO antibodies from the blood showed promising results in the clinic [17,18].

In the present study, TAO humoral immunology showed a highly significant increase in IgE. Combined with TAO clinical manifestations, repeated acute episodes, and the initiating factors (e.g. tobacco use, climate, trauma, and malnutrition) [3]. It has long been recognized that persistent cigarette smoking is a major risk factor for TAO persistence, progression, recurrence, and amputation. TAO patients seem to be in a sensitized state to cigarette smoking, indicating the presence of a Type I allergy. Elevated IgE levels may play some role in the pathogenesis of TAO as an autoimmune disease, but this should be further explored for confirmation [19]. Three types of immuno-labeling techniques all confirmed anti-vessel auto-antibodies in the sera of TAO patients. Furthermore, Ag-Ab complex deposits were observed directly on the vessel wall in multiple immune label samples. The existence of Type III hypersensitivity reaction was again confirmed. The auto-antibodies against the vessel were combined directly with damaged vascular collagen, which reflects a Type II hypersensitivity reaction (as noted in Figures 4-6).

According to the etiology analysis in our previous study of 876 cases, cigarette smoking was the greatest factor, but we also found other factors closely related to the disease. Most patients (80%) had a history of exposure to dampness and sudden temperature changes (e.g. intense exercise with sweating followed by freezing), and exposure to hot or cold extremes [3]. 29% of patients had a history of trauma, and 70% of patients had a history

of malnutrition. Also, 17% of TAO patients were not smokers but shared other risk factors as described above-risk factors that induce damage to the vessel walls to become auto-antigen or/and become sensitive factors to induce an allergic reaction. Cigarette smoking can not only introduce an allergic antigen, which may induce a Type I allergic reaction in TAO, but nicotine is also a hapten with blood red cells, intracellular histones or DNA binding, and therefore alters their composition, resulting in the production of auto-antibodies [20].

TAO shares many characteristics with autoimmune diseases. For example, TAO patients have autoantibodies and sensitized lymphocytes, high levels of  $\gamma$ -globulin in serum; deposition of the Ag-Ab complex in damaged vessels; and lymphocyte, plasma cell, and monocyte infiltration in the target vessels [4]. TAO patients also have a variety of auto-antibodies, and TAO has a genetic component [21,22]. In the clinic, patients with TAO often have repeated recurrences and chronic stability stage. In acute episodes of TAO, the course of the disease is managed using immunosuppressive agents and immunoabsorption agents to remove TAO antibodies [16-18]. TAO patients will sometimes experience damage to both extremities and viscera, which indicates TAO may be a systemic autoimmune disease [23,24]. Changes in sex hormones have an impact on immune function and may lead to autoimmune diseases [25]. Although most autoimmune diseases occur in women, TAO is more common in men, suggesting that man hormones may play a role Figure 7.



**Figure 7.** Schematic diagram of TAO pathogenesis-immune mechanism involving multiple hypersensitivity reactions (Designed by Ping Zheng and Wanchao Wang, 2020).

## Conclusion

Overall, this study provides further evidence to classify TAO as an autoimmune disease involving multiple hypersensitivities reaction. Mainly Type III hypersensitivity. However, Type IV and type II reactions are also involved. This study found IgE elevated in the sera of TAO patients, suggesting a Type I hypersensitivity reaction may be involved or plays some role in TAO autoimmunity. TAO vascular wall inflammation, blood hypercoagulation and thrombosis in the vascular lumen are considered a consequence of TAO autoimmune pathogenesis. This study not only elucidates the autoimmune pathogenesis of TAO. But also provides a new approach for clinical treatment.



## Declarations

Not applicable. (We both retired from China).

## Ethics Approval and Consent to Participate

At that time "yes".

## Consent for Publication

We both Ping Zheng and Wanchao Wang retired from China and all came to USA.

## Availability of Data and Materials

All data are available in the article text and figures.

## Competing Interests

The authors declare that they have no competing interests.

## Funding

This study was funded by the Shanghai Institute of Immunology with support from the World Health Organization.

## Authors' Contributions

Ping Zheng was responsible for the design of the study and drafting the article. Wanchao Wang provided assistance with the study design, performed immunological techniques, and reviewed and edited the draft article.

## Acknowledgements

We are sincerely grateful to Li Li, Xie YL of Shanghai Institute of immunology for their collaboration in some immunological techniques; Professor Ma BL, former director, Chief of the department in Shanghai Institute of Immunology for her instruction and Professor Su BH for statistical processing. We appreciate Professor Yang BH, Director of Peripheral Vascular Surgery, Dongzhimen Hospital, Beijing University of Chinese Medicine, Chairman of the Peripheral Vascular Disease Committee of China for his review and input. We also appreciate Dr. Mao M, principle immunological scientist of California Antagene Corp for his review.

## Authors' Information

None.

## References

- DL Mills, Joseph. "Buerger's Disease in the 21st Century: Diagnosis, Clinical Features, and Therapy". *Semin Vasc Surg* 16(2003): 179-189.
- Wang JJ, Zao WG, Sun SQ and Zhang Y. Changes in the Incidence of Thromboangiitis Obliterans. *Chin J Vasc Surg* 1(2009): 9-12.
- Zheng P. Etiology and Pathogenesis of Thromboangiitis Obliterans (TAO). *North Med* 5(1983): 13-15.
- Ping, Zheng, Fu Pei-Bin, Wang Wan-Chao and Xu Wen-Yu, et al. "Immunological Studies on Thromboangiitis Obliterans". *Chin Med J (Engl)* 102(1989): 129-136.
- Eichhorn, Jens, Dagmar Sima, Carsten Lindschau and Andreas Turowski, et al. "Anti-endothelial Cell Antibodies in Thromboangiitis Obliterans". *Am J Med Sci* 315(1998): 17-23.
- KS Halacheva, IM Manolova, DP Petkov and AP Andreev. "Study of Anti-Neutrophil Cytoplasmic Antibodies in Patients with Thromboangiitis Obliterans (Buerger's disease)". *Scand J Immunol* 48(1998): 544-550.
- Maslowski, Lezek, Robert McBane, Pawel Alexewicz and Waldemar E Wysokinski. "Antiphospholipid Antibodies in Thromboangiitis Obliterans". *Vasc Med* 7(2002): 259-264.
- de Godoy, José Maria Pereira and Domingo Marcolino Braille. "Buerger's Disease and Anticardiolipin Antibodies". *J Cardiovasc Med* 10(2009): 792-794.
- Klein-Weigel, Peter F, Marion Bimmler, Petra Hempel and Sebastian Schöpp, et al. "G-Protein Coupled Receptor Auto-Antibodies in Thromboangiitis Obliterans (Buerger's disease) and their Removal by Immunoabsorption". *Vasa* 43(2014): 347-352.
- Dellalibera-Joviliano R, EE Joviliano, JS Silva and PRB Evora. "Activation of Cytokines Corroborate with Development of Inflammation and Autoimmunity in Thromboangiitis Obliterans Patients". *Clin Exp Immunol* 170(2012): 28-35.
- Wei, Zheng, Wenjing Jiang, Hengzhen Wang and Hali Li, et al. "The IL-6/STAT3 Pathway Regulates Adhesion Molecules and Cytoskeleton of Endothelial Cells in Thromboangiitis Obliterans". *Cell Signal* 44(2018): 118-126.
- Halacheva, Krasimira, Maya V Gulubova, Irena Manolova and Dimitar Petkov. "Expression of ICAM-1, VCAM-1, E-Selectin and TNF- $\alpha$  on the Endothelium of Femoral and Iliac Arteries in Thromboangiitis Obliterans". *Acta Histochem* 104(2002): 177-184.
- Kobayashi, Masayoshi, Masafumi Ito, Atsuko Nakagawa and Naomichi Nishikimi, et al. "Immunohistochemical Analysis of Arterial Wall Cellular Infiltration in Buerger's Disease (Endarteritis Obliterans)". *J Vasc Surg* 29(1999): 451-458.
- Fu XM, Jing ZP and Guo F. Erythrocyte Immune Function and Regulatory Factors in Patients with Thromboangiitis Obliterans. *Shanghai Med* 20(1997): 403-404.
- Cui XM, Chen Y and Pan L. Vascular Medial Membrane Deposition of Immune Complexes in Thromboangiitis Observed by Electron Microscopy. *Bethune Med Univ* 27(2001): 379-380.
- Saha, Kunal, Navdeep Chhabra and Surindra Mohan Gulati. "Treatment of Patients with Thromboangiitis Obliterans with Cyclophosphamide". *Angiology* 52(2001): 399-407.
- Baumann, Gert, Verena Stangl, Peter Klein-Weigel and Karl Stangl, et al. "Successful Treatment of Thromboangiitis Obliterans (Buerger's disease) with Immunoabsorption: Results of a Pilot Study". *Clin Res Cardiol* 100(2011): 683-690.
- Klein-Weigel, Peter, Theresa Sophia Volz, Beate Gutsche-Petrak and Joana M. Boehnlein, et al. "Immunoabsorption in Buerger's Disease (Thromboangiitis Obliterans): A Promising Therapeutic Option: Results of a Consecutive Patient Cohort Treated in Clinical Routine Care". *Lupus* 1(2016): 111-4.
- Zhu W, Cao MD, Zhou YJ, Meng, Wei JF. Role of Ig E Against Autoantigens in Autoimmune Diseases. *Chin J Allergy Clin Immunol* 11(2017): 57-60.
- Papa M, Bass A, Adar R and Halperin Z, et al. "Autoimmune Mechanisms in Thromboangiitis Obliterans (Buerger's Disease): The Role of Tobacco Antigen and the Major Histocompatibility Complex". *Surgery* 111(1992): 527-31.
- Vijayakumar, Abhishek, Rahul Tiwari and Vinod Kumar Prabhswamy. "Thromboangiitis Obliterans (Buerger's Disease)-Current Practices". *Int J Inflam* 2013(2013): 156905.
- Kimura, Akinori, Yasushi Kobayashi, Megumi Takahashi and Nobuhisa Ohbuchi, et al. "MICA Gene Polymorphism in Takayasu's Arteritis and Buerger's Disease". *Int J Cardiol* 66(1998): S107-13.
- Fakour, Faeze and Bahare Fazeli. "Visceral Bed Involvement in Thromboangiitis Obliterans: A Systematic Review". *Vasc Health Risk Manag* 15(2019): 317-353.
- Zheng P and Zhang LN. "Thromboangiitis Obliterans with Myocardial Infarction in 3 Cases". *Cardiovasc Dis* 6(1978): 19-21.
- Zheng P, SJ Chen and HZ Shao. "Studies on Hypercoagulation State in Thromboangiitis Obliterans". *Chin Med J (Engl)* 102(1989): 67-71.

**How to cite this article:** Zheng, Portia Ping and Wanchao Wang. "Buerger's Disease: Autoimmune Disease Involving Multiple Hypersensitivity Types." *J Clin Res* 6 (2022): 003.