

## Bridging the Gap: A Novel Method for Hemorrhage Control

John Chovanes<sup>1</sup>, David J Schneider<sup>2</sup>, Jessica L McKee<sup>3\*</sup> and Ju-Lin Wang<sup>1</sup>

<sup>1</sup>Division of Trauma, Surgical Critical Care and Acute Care Surgery, Cooper University Hospital, 1 Cooper Plaza, Camden, NJ 08103, USA

<sup>2</sup>Directorate of Operational Medicine, US Department of State, 2401 E Street, NW, SA1 Washington, DC 20522-0102, USA

<sup>3</sup>Innovative Trauma Care, Suite 343, 6556-28 Ave NW, Edmonton, Alberta, T6L 6N3, Canada

### Introduction

There are six important vital structures in the neck providing aerodigestive, nervous, endocrine, and circulatory functions and they are minimally protected by the skeletal system unlike other areas of the body [1]. This lack of protection in the neck not only contributes to physician angst during treatment, but also to the high mortality and complication rate when injury occurs [2-4]. Airway compromise and exsanguination are both very high priorities and the time required to deal with one can be to the detriment of the other. Rapidly controlling hemorrhage provides the time required to establish a definitive airway without further blood loss of an already depleted intravascular volume. Delays in establishing definitive control of the airway can make the task of subsequent airway control difficult or impossible because of hematoma formation or injury/resuscitation induced edema leading to subsequent catastrophic airway obstruction [2,5]. The Western Trauma Association (WTA) Critical Decisions in Trauma recommends direct manual pressure (DMP) be used as a first line response to penetrating neck injury [6]. However, this approach has been associated with a low efficacy rate due to re-bleeding and exsanguination prior to reaching definitive operative care [7].

### Case Report

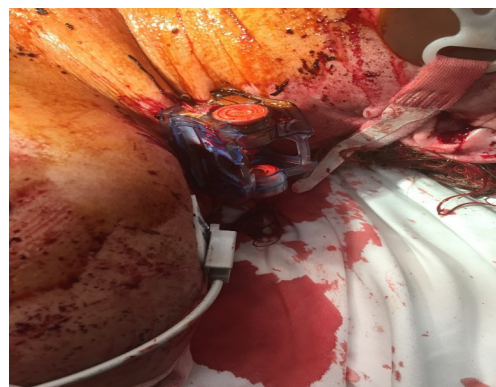
In the latter half of 2016 a 44-year-old female was brought into the Cooper Medical Trauma Center in Camden, New Jersey, USA after sustaining 25 stab wounds to the chest and neck. When the patient arrived at Cooper Medical Trauma Center she was unresponsive with a systolic blood pressure of 70. The patient was quickly assessed and consequently received four units of packed red blood cells and six units of fresh frozen plasma. During her assessment, physicians discovered two close proximity stab wounds at the base of the neck about one centimeter above the clavicle, with uncontrolled hemorrhage. The wound was packed with Combat Gauze but the gauze became saturated with blood. The blood soaked Combat Gauze was removed and a single iTClamp was placed over both stab wounds. Physicians noted that there was still some leaking around the iTClamp. The iTClamp was then removed, the wound was re-packed with Combat Gauze and the iTClamp was then used to seal the wound. Physicians remarked that the combination of wound packing and iTClamp allowed them to decrease the wound cavity and close the skin which resulted in good hemostasis (Figure 1). This entire protocol took less than two minutes to gain hemorrhage control, and the combination allowed physicians to seal both of the close proximity stab wounds. The patient stabilized and the surgeon took the patient to CT scan for further assessment. The ability to perform the CT scan prior to the OR allowed the surgeon to assess other potential bleeding sites and to ascertain where to begin surgical exploration of the 25 stab wounds. There was virtually no scatter (except a very small amount from the suture needles) and even less scatter than would have been seen from staples (Figures 2 and 3). After confirming that there was no arterial bleeding they focused on the neck wound and took the patient to the operating room. Surgeons were able to do the whole surgical prep with the device in place and removed

the iTClamp at the start of the surgical exploration. Surgeons opened up the close proximity neck wounds and explored deep to the clavicle in order to ligate the first branch of the subclavian vein.

### Discussion

PNI's have a high mortality and complication rate [2,3], and appropriate and timely management of these junctional injuries is time critical [2,3], including the completion of adjunctive measures such as CT scan. DMP is suggested as a first line response to PNI [6-9], but is also associated with a low efficacy rate [7]. The low efficacy rate of DMP is not just associated with modest to minimally trained care providers and care location [7,9], but is associated with the skill set required to perform the task [10]. This case report was able to further demonstrate the low efficacy of DMP as wound packing alone was ineffective at controlling hemorrhage even when performed by experienced physicians in an urban trauma center.

Another interesting point that merits further discussion is the fact that there was very little linear artifact or scatter on the CT scan from the iTClamp. The issue of linear artifact with metallic sutures or staples is not a new one [11] and while there are programs that have been created that can correct this issue [12], these programs may not



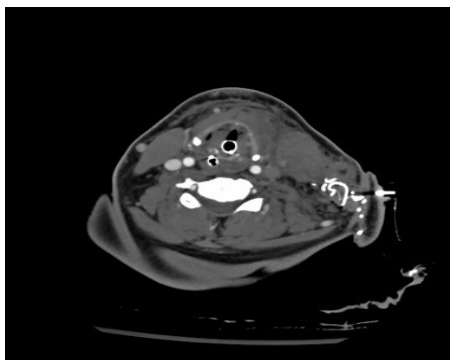
**Figure 1:** Combination of Combat Gauze and iTClamp to control hemorrhage in a penetrating neck injury from a stab wound.

**\*Corresponding author:** Jessica L McKee, Innovative Trauma Care, Suite 343, 6556-28 Ave NW, Edmonton, Alberta, T6L 6N3, Canada, Tel: 7809064947; E-mail: [jmckee@itraumacare.com](mailto:jmckee@itraumacare.com)

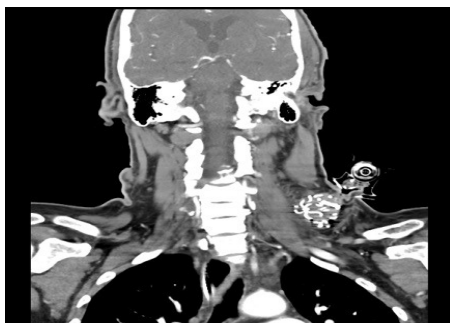
**Received** January 04, 2017; **Accepted** February 21, 2017; **Published** February 23, 2017

**Citation:** Chovanes J, Schneider DJ, McKee JL, Wang JL (2017) Bridging the Gap: A Novel Method for Hemorrhage Control. J Health Educ Res Dev 5: 211. doi: 10.4172/2380-5439.1000211

**Copyright:** © 2017 Chovanes J, et al. This is an open-access article distributed under the terms of the Creative Commons Attribution License, which permits unrestricted use, distribution, and reproduction in any medium, provided the original author and source are credited.



**Figure 2:** Superior CT scan image of hemorrhage control in a penetrating neck injury using Combat Gauze and the iTClamp.



**Figure 3:** Anterior CT scan image of hemorrhage control in a penetrating neck injury using Combat Gauze and the iTClamp.

always be available or the higher than average beam hardening makes the correction not possible [11,12]. Iterative reconstruction is cited as a means to address this issue, however, if the metal blocks all the photons soft tissue information cannot be retrieved with scatter correction [12]. Despite the fact the iTClamp contains eight metal needles, the physician on this case report commented that there was virtually no scatter and even less scatter than would have been seen from staples. This information definitely warrants further discussion and study as the ability to quickly stop hemorrhage and maintain CT scan integrity has its merits especially in a trauma setting where time is of the essence.

It has been demonstrated in the literature that the iTClamp is able to control bleeding in any compressible zone [13-17]. This case report adds to that body of knowledge and shows that the iTClamp may be a viable option to DMP or wound packing alone to controlling hemorrhage in junctional/penetrating neck injury, especially when combined with packing. It is however recommended as with any modality for controlling hemorrhage in the neck that the patient is continually monitored for hematoma, edema and any airway issues [3]. While no airway issues were seen in this case, it is recommended that care providers continue to monitor the airway after iTClamp application with the same care and jurisprudence as it would be if DMP were utilized.

## Conclusion

Hemorrhage accounts for up to 50% of mortality in PNI and DMP has a low efficacy rate for treating it. This case report suggests the iTClamp may be considered as an alternative or adjunct to DMP/packing for use in controlling exsanguination from junctional PNI injuries.

## Conflict of Interest

Jessica McKee is the clinical director for Innovative Trauma Care. The company that manufactures the iTClamp used in this case report. David Schneider is a contract educator for Innovative Trauma Care. The Other two authors do not have any relevant disclosures.

## References

- Kim JP, Park JJ, Won SJ, Woo SH (2011) Penetrating carotid artery injuries treated by an urgent endovascular stent technique: Report of two cases. *Chonnam Medical Journal* 47: 134-137.
- Tisherman SA, Bokhari F, Collier B, Cumming J, Ebert J, et al. (2008) Clinical practice guideline: penetrating zone II neck trauma. *Journal of Trauma and Acute Care Surgery* 64: 1392-1405.
- Kaya KH, Koç AK, Uzun M, Altıntaş A, Yeğin Y, et al. (2013) Timely management of penetrating neck trauma: Report of three cases. *Journal of Emergencies, Trauma and Shock* 6: 289.
- Ball CG (2015) Penetrating nontorso trauma: the head and the neck. *Canadian Journal of Surgery* 58: 284.
- Meghoo CA, Dennis JW, Tuman C, Fang R (2012) Diagnosis and management of evacuated casualties with cervical vascular injuries resulting from combat-related explosive blasts. *Journal of Vascular Surgery* 55: 1329-1337.
- Sperry JL, Moore EE, Coimbra R, Croce M, Davis JW, et al. (2013) Western Trauma Association critical decisions in trauma: penetrating neck trauma. *Journal of Trauma and Acute Care Surgery* 75: 936-940.
- Weppner J (2013) Improved mortality from penetrating neck and maxillofacial trauma using Foley catheter balloon tamponade in combat. *Journal of Trauma and Acute Care Surgery* 75: 220-224.
- Ball CG, Wyrzykowski AD, Nicholas JM, Rozycki GS, Feliciano DV (2011) A decade's experience with balloon catheter tamponade for the emergency control of hemorrhage. *Journal of Trauma and Acute Care Surgery* 70: 330-333.
- Wade AL, Dye JL, Mohrle CR, Galarneau MR (2007) Head, face, and neck injuries during Operation Iraqi Freedom II: results from the US navy-marine corps combat trauma registry. *Journal of Trauma and Acute Care Surgery* 63: 836-840.
- Littlejohn LF, Devlin JJ, Kircher SS, Lueken R, Melia MR, et al. (2011) Comparison of Celox-A, ChitoFlex, WoundStat, and Combat Gauze Hemostatic Agents Versus Standard Gauze Dressing in Control of Hemorrhage in a Swine Model of Penetrating Trauma. *Academic Emergency Medicine* 18: 340-350.
- Golding RP (1983) Suture materials under the CT and NMR scanner. *Lancet* 321: 541.
- Boas FE, Fleischmann D (2012) CT artifacts: causes and reduction techniques. *Imaging in Medicine* 4: 229-240.
- Barnung S, Steinmetz J (2014) A prehospital use of iTClamp for haemostatic control and fixation of a chest tube. *Acta Anaesthesiologica Scandinavica* 58: 251-253.
- Filips D, Mottet K, Lakshminarasimhan P, Atkinson I (2014) The iTClamp 50, a hemorrhage control solution for care under fire. *ICMM World Congress on Military Medicine*.
- Filips D, Logsetty S, Tan J, Atkinson I, Mottet K (2013) The iTClamp controls junctional bleeding in a lethal swine exsanguination model. *Prehospital Emergency Care* 17: 526-532.
- Kirkpatrick AW, McKee JL (2013) Tactical Hemorrhage Control Case Studies Using a Point-of-Care Mechanical Direct Pressure Device. *Journal of Special Operations Medicine: A Peer Reviewed Journal for SOF Medical Professionals* 14: 7-10.
- Mottet K, Filips D, Logsetty S, Atkinson I (2014) Evaluation of the iTClamp 50 in a human cadaver model of severe compressible bleeding. *Journal of Trauma and Acute Care Surgery* 76: 791-797.