

# Brain Injury and SARS-CoV-2 Infection: Bidirectional Pathways

Hayder M. Al-kuraishy<sup>1\*</sup>, Ali I. Al-Gareeb<sup>1</sup>, Marta Chagas Monteiro<sup>2</sup> and Hanan J. Al-Saidy<sup>3</sup>

<sup>1</sup>Department of Clinical Pharmacology, Medicine and Therapeutic, Al-Mustansiriya University, Baghdad, Iraq

<sup>2</sup>Department of Clinical Microbiology and Immunology, Federal University of Pará/UFP, Para, Brazil

<sup>3</sup>Department of Medicine, Armstrong Institute for Patient Safety and Quality, Baghdad, Iraq

## Abstract

Coronavirus Infection Disease (COVID-19) is a recent pandemic infectious disease caused by Severe Acute Respiratory Syndrome Coronavirus (SARS-CoV2), ongoing in Wuhan, China that earlier known as Wuhan pneumonia. COVID-19 was declared by the World Health Organization (WHO) as a pandemic disease on March 11th, 2020. As of October, 2020, there have been total of 34,392,166 confirmed cases with 1,022,391 deaths globally.

**Keywords:** Neurological disorders • Parasthesia • Headache • Cold extremities • Neuroinvasive viruses

## Description

COVID-19 is associated with different neurological manifestations, as one third of COVID-19 patients have some neurological disorders, including parasthesia, headache, cold extremities and disturbances of consciousness, that are more evident in severely affected patients [1]. In addition, SARS-CoV-2 (Figure 1) may leads to viral encephalitis, brain edema and neuronal degenerations [2]. In COVID-19, the neurological manifestations of infected patients have not been usually reported, since elderly patients that are commonly affected have altered level of consciousness, which might confusing with the disturbances of patients with COVID-19. It has been reported that 6% of patients with COVID-19 presented with Acute Ischemic Stroke (AIS), 15% with disturbances of consciousness, and 19% with movement disorders [3].

Viral infections have detrimental impacts on neurological functions, and even to cause severe neurological damage. Very recently, coronaviruses (CoV), particularly SARS-CoV-2 display neurotropic properties and may also cause neurological diseases. It is reported that CoV can be found in the brain or cerebrospinal fluid [4]. The pathobiology of these neuroinvasive viruses is still incompletely known, and it is therefore important to explore the impact of CoV infections on the nervous system. Here, we review the research into neurological complications in SARS-CoV-2 infections and the possible mechanisms of damage to the nervous system.

Given the taxonomic similarity between SARS-CoV and SARS-CoV-2, it is plausible that patients with COVID-19 might also exhibit CNS damage related to the infecting coronavirus. It remains unclear to what extent SARS-CoV-2 is able to infect the CNS and, if it does, how the virus reaches the brain, but the possible theories have emerged: spread across the cribriform plate of the ethmoid bone in proximity to the olfactory bulb in patients at the early stage of the disease, resulting in the relatively common loss of sense of smell, or a later-occurring hematogenous spread on the setting of accompanied hypoxia, respiratory, and metabolic acidosis. Direct CNS infection by SARS-CoV has also been shown in mice, but whether SARS-CoV-2 infects the brain of humans remains unknown [5].

The pathogenesis of these CNS effects of COVID-19 is not known, although direct invasion of the virus may be unlikely. The entry of SARS-CoV-2 into human host cells is mediated mainly by the cellular receptor Angiotensin-Converting Enzyme 2 (ACE2), which is expressed at very low levels in the CNS under normal conditions [6]. CNS hypoxia due to respiratory failure caused by COVID-19, thrombotic microangiopathy, and an indirect effect of the vigorous inflammatory response with extensive cytokine activation that is commonly found in severe COVID-19 are more probable explanations, although further study is needed to examine these factors [7].

Many authors have suggested that the virus enters the Central Nervous System (CNS) through olfactory neurons, as SARS-CoV-1 invades the brains of mice brain in experimental models. This mode of entry could also explain the frequency of anosmia observed during the onset of COVID-19

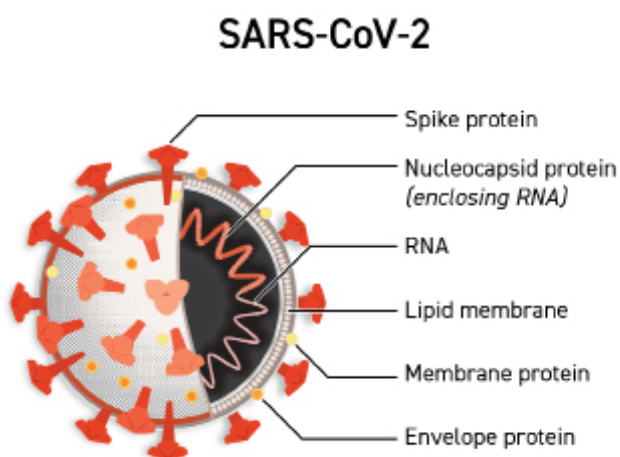


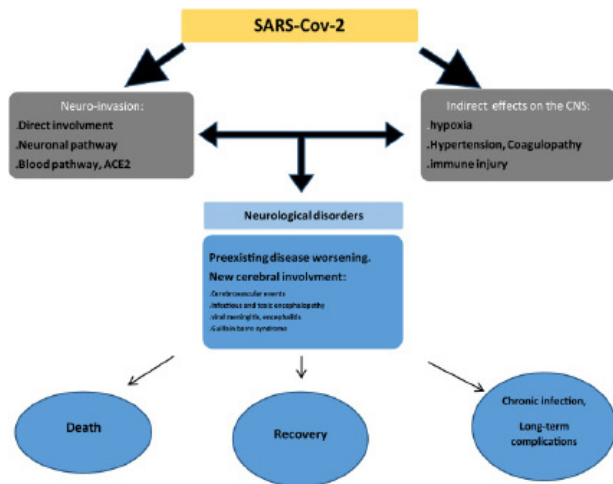
Figure 1. Structure of SARS-CoV2.

\*Corresponding Author: Hayder M. Al-kuraishy, Department of Clinical Pharmacology, Medicine and Therapeutic, Al-Mustansiriya University, Baghdad, Iraq, Tel: 96407906230487; E-mail: Hayderm36@Yahoo.com

Copyright: © 2020 Al-kuraishy HM, et al. This is an open-access article distributed under the terms of the Creative Commons Attribution License, which permits unrestricted use, distribution, and reproduction in any medium, provided the original author and source are credited.

Received: October 02, 2020; Accepted: October 16, 2020; Published: October 23, 2020

(Figure 2) [8]. However, after several months of a worldwide COVID-19 pandemic, there is no substantial evidence for the presence of SARS-CoV-2 in the brain, with the exception of two patients with SARS-CoV-2 RNA detected in their Cerebrospinal Fluid (CSF) [9].



**Figure 2.** Pathways and outcomes of brain SARS-CoV-2 infection.

If we assume that SARS-CoV-2 invades the brain through the olfactory pathway, the orbital prefrontal cortex, adjacent to the olfactory bulb, should be the first region of the brain affected. This hypothesis is supported by brain 18fluoro-2-deoxy-D-glucose (18FDG) Positron Emission Tomography Computed Tomography (PET-CT) that showed hypometabolism within the orbitofrontal cortex in a COVID-19 patient with isolated anosmia [10]. In addition, another recent study found that 88.9% of electroencephalography (EEG) studies performed in COVID-19 patients for suspected encephalopathy and/or seizure-like events revealed epileptiform discharges, mostly within the frontal lobes [11].

The dissemination of COVID-19 in the systemic circulation or across the cribriform plate of the ethmoid bone during an early or later phase of the infection can lead to cerebral involvement as has been reported in the past for SARS-CoV affected patients. The presence of the COVID-19 virus in the general circulation understandably enables it to pass into the cerebral circulation where the sluggish movement of the blood within the microcirculation could be one of the factors that may facilitate the interaction of the COVID-19 virus spike protein with ACE2 expressed in the capillary endothelium [12]. Subsequent budding of the viral particles from the capillary endothelium and damage to the endothelial lining can favor viral access to the brain. Once within the milieu of the neuronal tissues, its interaction with ACE2 receptors expressed in neurons can initiate a cycle of viral budding accompanied by neuronal damage without substantial inflammation as has been seen with cases of SARS-CoV in the past [13].

According to our cell-type distribution analysis, nuclear expression of ACE2 was found in many neurons (both excitatory and inhibitory neurons) and some non-neuron cells (mainly astrocytes, oligodendrocytes and endothelial cells) in human middle temporal gyrus and posterior cingulate cortex. A few ACE2-expressing nuclei were found in a hippocampal dataset, and none were detected in the prefrontal cortex. Except for the additional high expression of ACE2 in the olfactory bulb areas for spatial distribution as well as in the pericytes and endothelial cells for cell-type distribution, the distribution of ACE2 in mouse brain was similar to that in the human brain [14].

It is important to mention here that, long before the proposed anticipated neuronal damages occur, the endothelial ruptures in cerebral capillaries accompanied by bleeding within the cerebral tissue can have fatal consequences in patients with COVID-19 infections [15]. The movement of the COVID-19 virus to the brain via the cribriform plate close to the olfactory bulb can be an additional pathway that could enable the virus to reach and affect the brain. Additionally, the findings like an altered sense of smell or hyposmia in an uncomplicated early stage COVID-19 patient should be

investigated thoroughly for CNS involvement. Autopsies of the COVID-19 patients, detailed neurological investigation, and attempts to isolate SARS-CoV-2 from the endothelium of cerebral microcirculation, cerebrospinal fluid, glial cells, and neuronal tissue can clarify the role played by this novel COVID-19 causing coronavirus in the ongoing mortalities as has been in the recent outbreak [16].

It is important to mention here that although the cerebral damage may complicate a COVID-19 infection, it appears that it is the widespread dysregulation of homeostasis caused by pulmonary, renal, cardiac, and circulatory damage that proves fatal in COVID-19 patients. With that being said, a dominant cerebral involvement alone with the potential of causing cerebral edema in COVID-19 can take a lead in causing death long before systemic homeostatic dysregulation sets in [17]. Access of the COVID-19 virus to the brain via the transcribrial route, could have been the case in a recently reported patient with hyposmia and the cases of acute respiratory failure in COVID-19, which needs to be further elucidated by isolating the SARS-CoV-2 virus from the zones that are in proximity to the olfactory bulb [18].

It is expected that the differences in the sequence of spike proteins between COVID-19 virus and SARS-CoV will enable scientists to identify epitopes in COVID-19 virus for the development of monoclonal antibodies against this virus. With the recent COVID-19 outbreak, there is an urgent need to understand the neurotropic potential of the COVID-19 virus in order to prioritize and individualize the treatment protocols based on the severity of the disease and predominant organ involvement. Also, a staging system based on the severity and organ involvement is needed in COVID-19 in order to rank the patients for aggressive or conventional treatment modalities [19].

Therefore, whether COVID-19-related CNS dysfunction results from direct viral injury, indirect consequences of immune-mediated disease, systemic effects of infection, or local effects of the virus is still a matter of debate and these hypotheses are not mutually exclusive. However, the recent reports of frontal hypometabolism on PET-CT, frontal EEG abnormalities during COVID-19, and our case description are strong arguments in favor of a "SARS-CoV-2-related-frontal involvement," whether direct or indirect [20].

## Conclusion

In the light of substantial body of evidence, this minireview explores and shed light on the potential direct or indirect effect of SARS-CoV-2 on the CNS in patients with COVID-19 pneumonia.

## Conflict of Interest

Nil

## Funding and Sponsorship

Nil

## References

- Al, Kuraishy and Hayder Mutter. "Is Ivermectin–Azithromycin Combination the Next Step for COVID-19?" *Biomed Biotechnol Res J* 4(2020): 101.
- Al, Kuraishy and Hayder Mutter. "COVID-19 Pneumonia in an Iraqi Pregnant Woman with Preterm Delivery." *Asian Pac J Reprod* 9(2020): 156.
- Al, Kuraishy and Hayder Mutter. "The Potential Role of Renin Angiotensin System (RAS) and Dipeptidyl Peptidase-4 (DPP-4) in COVID-19: Navigating the Uncharted. In: Selected Chapters from the Renin-Angiotensin System." *Intech Open* (2020).

4. Al, Kuraishy and Hayder Mutter. "Macrolides and COVID-19: An Optimum Premise." *Biomed Biotechnol Res J* 4(2020): 189.
5. Al, Kuraishy and Hayder Mutter. "Renin–Angiotensin System and Fibrinolytic Pathway in COVID-19: One-Way Skepticism." *Biomed Biotechnol Res J* 4(2020): 33.
6. Al, Kuraishy, Hayder M, Al Gareeb and Ali I. "From SARS-CoV to nCoV-2019: Ruction and Argument." *Arch Clin Infect Dis* 15(2020): e102624.
7. Lu, Ostarinen and Teemu Luostarinen. "Intensive Care of Traumatic Brain Injury and Aneurysmal Subarachnoid Hemorrhage in Helsinki during the Covid-19 Pandemic." *Acta Neurochirurgica* (2020): 1-10.
8. Kumar, Ashutosh. "Possible Routes of SARS CoV 2 Invasion in Brain: In Context of Neurological Symptoms in COVID 19 Patients." *J Neurosci Res* (2020).
9. Paniz, Mondolfi Alberto. "Central Nervous System Involvement by Severe Acute Respiratory Syndrome Coronavirus 2 (SARS CoV 2)." *J Med Virol* 92(2020): 699-702.
10. Kumar, Ashutosh. "Possible Routes of SARS CoV 2 Invasion in Brain: In Context of Neurological Symptoms in COVID 19 Patients." *J Neurosci Res* (2020).
11. Galanopoulou, Aristeia S. "EEG Findings in Acutely ill Patients Investigated for SARS CoV2/COVID 19: A Small Case Series Preliminary Report." *Epilepsia Open* (2020).
12. V, Montalvan. "Neurological Manifestations of COVID-19 and Other Coronavirus Infections: A Systematic Review." *J Clin Neurol Neurosurg* 194(2020): 105921.
13. Chougar, Lydia. "Retrospective Observational Study of Brain Magnetic Resonance Imaging Findings in Patients with Acute SARS-CoV-2 Infection and Neurological Manifestations." *Radiology* (2020): 202422.
14. MA, Anyun. "Overexpression of Central ACE2 (Angiotensin-Converting Enzyme 2) Attenuates the Pressor Response to Chronic Central Infusion of Ang II (Angiotensin II) A Potential Role for Nrf2 (Nuclear Factor [Erythroid-Derived 2]-Like 2)." *Hypertension* 120(2020): 15681.
15. Winkler, Emma S. "SARS-CoV-2 Infection of Human ACE2-Transgenic Mice Causes Severe Lung Inflammation and Impaired Function." *Nature Immunology* (2020): 1-9.
16. Vadhan, Jason D, Speth and Robert C. "The Role of the Brain Renin-Angiotensin System (RAS) in Mild Traumatic Brain Injury (TBI)." *Pharmacology & Therapeutics* (2020): 107684.
17. Paterson, Ross W. "The Emerging Spectrum of COVID-19 Neurology: Clinical, Radiological and Laboratory Findings." *Brain* (2020).
18. Agarwal, Shashank. "Cerebral Microbleeds and Leukoencephalopathy in Critically ill Patients With COVID-19." *Stroke* 51(2020): 2649-2655.
19. Reichard, R. Ross. "Neuropathology of COVID-19: A Spectrum of Vascular and Acute Disseminated Encephalomyelitis (ADEM)-like Pathology." *Acta Neuropathologica* (2020): 1-6.
20. Aghagoli, Ghazal. "Neurological Involvement in COVID-19 and Potential Mechanisms: A Review." *Neurocritical Care* (2020): 1-10.

**How to cite this article:** Hayder M.Al-kuraishy, Ali I. Al-Gareeb, Marta Chaga Monteiro and Hanan J. Al-Saidy. "Brain Injury and SARS-CoV-2 Infection: Bidirectional Pathways." *J Brain Res* 3 (2020): e114.