

# Biomechanics and Immunomediated Mechanisms in the Cochlear Implant Rejection

Navarrete ML<sup>1\*</sup>, Fuentes JF, Herrero T<sup>2</sup>, Velasco M<sup>2</sup>, González M<sup>1</sup> and Moya JR<sup>1</sup>

<sup>1</sup>Autonomous University of Barcelona, Barcelona, Spain

<sup>2</sup>Departments of Otorhinolaryngology and Phoniatrics, Vall d'Hebron Hospital, Autonomous University of Barcelona, Spain

## Abstract

Patients with bilateral and severe neurosensorial hypoacusia are candidates for cochlear implantation. Eventhough it's a relatively modern procedure, it has a very low rate of complications (5-10%), making it a safe surgery. The Cohen classification is currently used to measure and group the complications of this surgery, classifying them according to the moment in which they appear whether it's intraoperative or postoperative time.

We present the case of a female patient who suffered the extrusion of the implant several months after the procedure. She was re-operated successfully, but she returned months later with a second extrusion of the same implant. We did not find any other report of this phenomenon in the revised literature. We present this case with pictures of the repair surgery and the patient's current condition. We also analyze possible causes of this cochlear implant rejection, citing both magnetomechanical and immunomediated factors.

**Keywords:** Cochlear implant; Complications; Extrusion; Biomechanic; Immunity

## Introduction

One of the first published papers about the complications of coclear implants (CI) was written by Thielemeir [1]. The complications can be classified as major and minor, depending on their severity. Using this classification Cohen [2] and Lehnhardt [3], placed major complications around 2.5% to 15%, most of them related to the graft and erosion of the posterior wall of the external auditory conduct. Minor complications (facial palsy, instability, tympanic membrane perforations, seromas, etc) varied from 6.2% to 25%, all of them temporary.

It's interesting to note how various authors state that the rate of complications tends to go down, because of the experience acquired and the correction of flaws in the surgical technique [4,5].

While complications related to rejection of the CI are mentioned in literature, there has been no real analysis of the possible etiopathogeny of the phenomenon.

Local adverse effects of any CI can be immediate: edema; intermediate: abscess formation and late: foreign body- induced granulomas [6].

Inert materials like silicone and ceramics are biologically active. Evidence of their importance in the etiology of implant rejection is provided by the presence of granulomas and autoantibodies in the implant's periphery and the absence of infection in the extruded materials analyzed.

By itself, the cochlear implant has fibrogenic capabilities and can migrate. There is a physiologic response from the host to the foreign body: the biomaterial's placement in the body produces a local acute inflammatory response, similar to a foreign body reaction. Afterwards a fibroblastic reaction, with the presence of collagen an elastin, takes place and finally, the late granuloma formation as an immunomediated reaction occurs [7].

Faced with this rejection phenomenon we can ask ourselves: Why have adverse effects been described only with the CI and not with other uses? Also, what to do when faced with patients with a personal or familial history of autoimmune disease or serum autoantibody presence? Is it possible to look for high risk markers?

## Materials and Methods

We present a 56 year old female patient with a medical history of deep bilateral hypoacusia, depression, type II diabetes and a former pack and a half- a day smoking habit. She had bilateral neurosensorial endocochlear hypoacusia (NSH) proven by brainstem auditory evoked potentials (BERA) with a more severe left-ear deficit. She received a left cochlear implant (Medel model PULSARci 100) on July 2006, with good functional adaptation.

During a routine follow-up visit on March 2008, signs of extrusion of the implant were observed. There were no external signs of infection Figure1 and 2. She was taken to the OR for rotation-relocation of the internal receptor of the same CI in a new bone bed, avoiding the scar lines of the myocutaneous flap and reinforcing it in proximity to the skin.

The macroscopic findings of the bone bed of the internal receptor showed osteogenesis that extruded it towards the surface. There was also atrophy on the internal face of the myocutaneous flap that was in contact with the receptor Figures 3-5.

The intraoperative control telemetry was satisfactory.

## Results

On a follow-up rehabilitation visit, when the CI was reconnected the patient reported that the voices "sounded far away" and that she relied a lot on lipreading. In the following controls, word discrimination was poor in both open and closed spaces and telephone speech intelligibility also declined.

**\*Corresponding author:** M.L. Navarrete, Autonomous University of Barcelona, C/ Balmes 434, 1º A 08022, Barcelona, Spain, E-mail: [mlna@telefonica.net](mailto:mlna@telefonica.net)

**Received** December 22, 2011; **Accepted** January 10, 2012; **Published** January 12, 2012

**Citation:** Navarrete ML, Fuentes JF, Herrero T, Velasco M, González M, et al. (2012) Biomechanics and Immunomediated Mechanisms in the Cochlear Implant Rejection. J Tissue Sci Eng 3:112. doi:[10.4172/2157-7552.1000112](https://doi.org/10.4172/2157-7552.1000112)

**Copyright:** © 2012 Navarrete ML, et al. This is an open-access article distributed under the terms of the Creative Commons Attribution License, which permits unrestricted use, distribution, and reproduction in any medium, provided the original author and source are credited.

The implant's subjective functionality was also poorer than in the original procedure. At the moment, the patient possesses 6 active electrodes and has started rehabilitation, recognizing up to 3 distinct vocal groups.

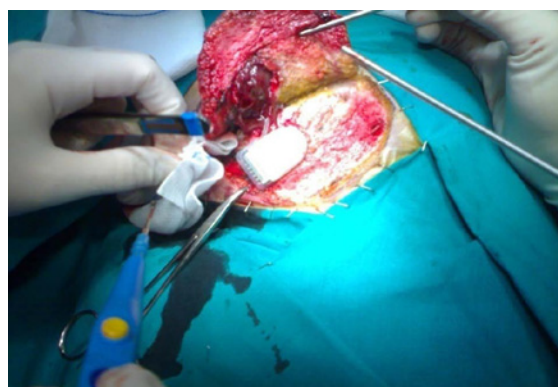During the patient's clinical follow-up, in November 2008, the start of a new CI extrusion was observed Figure 6. There was thinning in some areas of the cutaneous flap and macroscopic granulomas present on its surface. Given the patient's circumstances, we planned a new repair procedure, or even the extraction of the extruded implant and a CI placement on the contralateral ear. The patient, nonetheless, rejected any new surgical procedures.

## Discussion

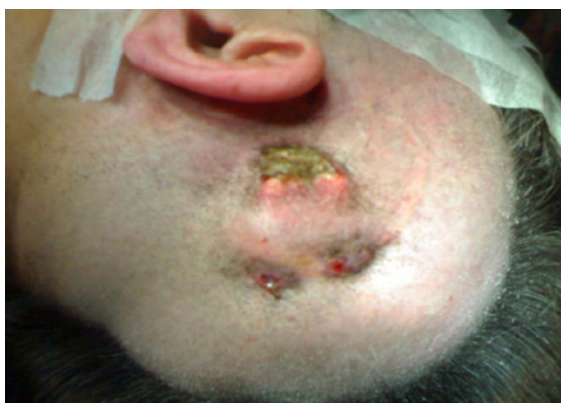Cochlear implant surgery is considered as a safe surgical option that can achieve acceptable results. The complications of the surgery usually follow Cohen's classification: intraoperative or postoperative [8]. Among the intraoperative, the most noteworthy are CSF leaks, facial nerve injuries, electrode placement alterations and excessive thinning of the posterior wall of the external auditory canal. Postoperative complications can have an early or delayed onset [9]. Wound infection, device migration, facial nerve palsy, meningitis and instability are the most important immediate complications [10,11].

Regarding complications immediate to the surgery we would highlight:

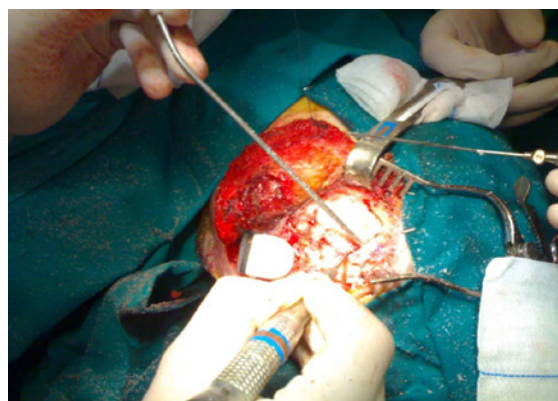
1. Incision: any incision can be used, as long as the flap completely covers the device and it has an adequate blood supply.
2. Flaps: The possible complications include infections and hematomas in the posteroinferior triangle of the flap [12]. It is more likely to occur in adults with an excessive occipito-mastoid curve and children because of their smaller size.
3. The mastoidectomy: Because of the CI antenna's memory, extending the surgery posteriorly could cause a protrusion



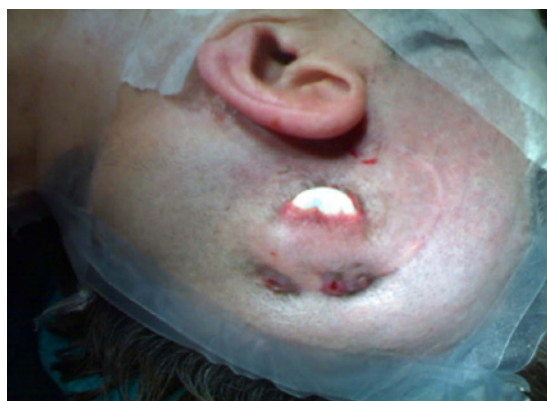**Figure 3:** There was osteogenesis at the receptor's bed and atrophy at the flap's internal face.



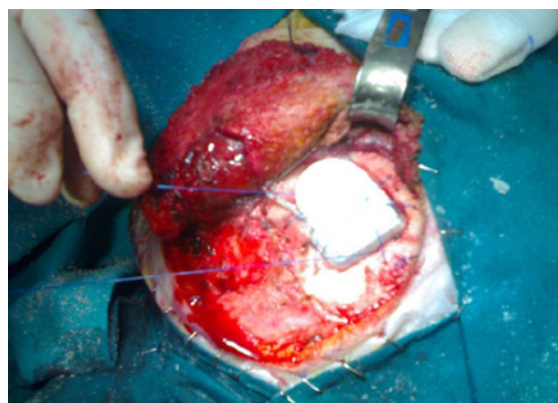
**Figure 1:** Signs of extrusion of the CI on March 2008.



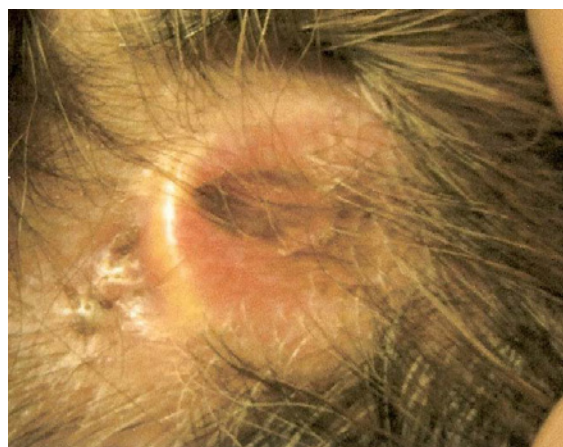**Figure 4:** Relocation of the same CI's internal receptor.



**Figure 2:** Once the detritus are removed, the internal receptor's extrusion can be observed.



**Figure 5:** Rotation of the receptor in a new bone bed.



**Figure 6:** New extrusion of the implant with thinning and granuloma formation at the flap.

of the antenna and its posterior extrusion. This would be a mechanical traction-expulsion process [13].

4. The receptor's anchoring: The receptor needs to always be securely anchored to bone. Failure to do so could cause an attraction from the magnet to the receptor and its extrusion by a mechanomagnetic mechanism.

Regarding the surgery's possible early postoperative complications:

1. Displacement of the coil: if the antenna isn't properly secured to the bone, the material's memory can cause a prolapse at the superficial layers. The incision has to be separate from the internal device to avoid extrusion by traction.
2. Coil extrusion: The internal device's position is very posterior to the occipitomastoid suture. Flaps that are thinned in an attempt to reduce impedance, could leave the coil in contact with the incision.

Regarding the late postoperative complications: The extrusion of the implant is an infrequent form of the set of complications that includes mastoiditis, meningitis, facial nerve stimulation and a technical failure in the implanted system [14,15].

To study the possible complications of a CI, while centering on the one that's the object of this study, that is the extrusion of the implant, we will first analyze the factors that can lead to the rejection of the implant. That is, the pre-surgical factors. After those, the hypothetical factors that could lead to the extrusion of the implant over biological rejection by the host.

Most of the reviewed publications describe that extrusion of the CI is produced by decubitus damage at the myocutaneous flap. On occasions, surgical reintervention is necessary, with a new flap or even re-implantation. In our case, while it's true that the receptor's extrusion occurred as it fistulized through the flap, the receptor wouldn't have been exposed had there been no osteal neogrowth in the receptor's bone bed. This osteogenesis was probably motivated by an immune-mediated rejection by the host and/ or the potent mechanic extrusive effect by the CI's magnet [16-18].

According to the available literature, re-implantation of the receptor by itself is enough to adequately resolve the complication. However, in this particular case, this procedure hasn't solved the problem. That's

why we believe that it might be more appropriate to implant the other ear that to re-implant the ear where the extrusion occurred.

Regarding the biological complications we will say that the local adverse effects of any implant can be immediate: pain, edema; intermediate: swelling, abscess formation, necrosis and altered healing; and late: nodule and granuloma formation.

The different types of granulomas secondary to implants can have different anatomopathological compositions, whether they are sarcoid, tuberculoid, necrobiotic, suppurative or foreign body [6], as was the case in this patient.

If the implant cannot be phagocytized, due to the size of its particles or its vehicle, a foreign body reaction, with granuloma formation and local atrophy, is induced. The anatomopathological base of granulomas is a diffuse infiltrate that affects the dermis, with or without inclusion bodies, histiocytes, and multinucleated cells with sclerotic stroma. They can appear within months or even years. Local and oral treatments with corticosteroids haven't achieved good results [7]. The definitive treatment is the extraction of the implant [19].

Some components of the CI, like the inner receptor, can use silicone or ceramics among other vehicles. In this case it's a model PULSAR ci 100-Mede implant, which has an internal receptor made out of ceramics. The ceramic is a type of clay, a plastic mineral substance made from the hydrated silicates of different metals, routinely used in medicine among other industries.

When used for medical purposes, the material's great hardness can be an advantage or an inconvenience. These compounds, like silicones among others, are inert and biologically active materials. That's the reason why, before the usage of any implant, the following steps should be part of the protocol: mutagenesis testing, cytotoxicity tests, sensibilization testing and trophoblastic activity tests.

This particular case is an extrusion of the CI with ossification of the receptor bone bed and with atrophy and granuloma formation at the flap and surrounding tissues, that had required reintervention, and that has now, once again, presented the same type of late complication. It's the first reported such case of a second extrusion of a CI, according to our bibliographical review. It's also the first article that tries to explain the reasons for these chain rejections.

## Conclusions

1. Cochlear implantation surgery is considered a safe option with an acceptable result. Its complications can be classified as major or minor, depending on their severity and if a second surgery was needed.
2. This case can be helpful in raising certain fundamental questions like: What type of etiopathogeny is involved in osteogenesis? And, is this ossification primary or secondary to the rejection? Also, what role does the magnet play in the establishment and progression of the implant's extrusion? The convexity of the skull could help the antenna's memory to cause an extrusion of it. But, why does this happen in some patients and not in others?
3. The implant has phylogenetic capabilities and can migrate. There is a physiological response from the host to the foreign material (implant). The placement of the biomaterial produces a local foreign-body reaction in the host. But, why does this happen in some patients and not in others?



4. We open a door to a research subject: finding genetic locators that can help identify before the surgery which patients are more likely to reject the implant.

## References

1. Thieleimer M (1985) Status and results of the House Ear Institute Cochlear Implant Project. In *Cochlear Implants*. Ed Schindler R Merzenich MNY: Raven Press 455-460.
2. Cohen N, Waltzman S, Fisher S (1993) A prospective, randomized study of cochlear implants. *N Engl J Med* 328: 233-237.
3. Lehnhardt E, Aschendorff A (1993) Prognostic factors in 187 adults provided with the Nucleus cochlear mini-system 22. *Adv Otorhinolaryngol* 48: 146-152.
4. Weir N (1990) Progress in Otology. In: *Otolaryngology Illustrated History*. Burtterwood 217.
5. García Ibáñez E, Benito M, Rivas P (1990) Selección de los candidatos para implante codear. En: García Ibáñez E. *Implantes Codeares*. Ed Prodisa Barcelona.
6. Janowsky EC, Kupper LL, Hulka BS (2000) Meta-analyses of the relation between silicone breast implants and the risk of connective-tissue diseases. *N Engl J Med* 342: 781-790.
7. Abbas AK (2002) *Inmunología Celular y Molecular*. (3edn) Mc GRAW-HILL.
8. Cohen NL, Roland JT Jr, Marrinan M (2004) Meningitis in cochlear implants recipients: the North American experience. *Otol Neurotol* 25: 275-281.
9. Green KM, Bhatt YM, Saeed SR, Ramsden RT (2004) Complications adult following cochlear implantation: experience in Manchester. *J Laryngol Otol* 118: 417-420.
10. Schwartzman JA (1987) Comparative results with the House vs Nucleus Cochlear Implant. *Proc Inter Coch Sym Denver, West Germany* 645-651.
11. Cohen NL, Hoffmann RA, Stroschein M (1988) Medical or surgical complications related to the Nucleus multichannel cochlear implant. *Ann Otol Rhinol Laryngol suppl* 135:8-13.
12. Xu J, Shepherd RK, Xu SA, Seldon L, Clark GM (1993) Paediatric cochlear implantation radiologic observations of skull growth. *Arch Otolaryngol Head Neck Surg* 119: 525-534.
13. Kennedy DW (1987) Multichannel intracochlear electrodes: Mechanism of insertion trauma. *Laryngoscope* 97: 42-49.
14. Gantz B, Tyler RS, Knutson JF, Woodworth G, Abbas P, et al. (1988) Evaluation of five different cochlear implants designs audiologic assessment and predictors of performance. *Laryngoscope* 98: 1100-1106.
15. Deguine O, Fraysse B, Uziel A, Cochard N, Reuillard-Artières F, et al. (1993) Predictive factors in cochlear implant surgery. *Adv Otorhinolaryngol* 48: 142-145.
16. Webb RL, Lehnhardt E, Clark GM, Laszig R, Pyman BC, et al. (1991) Surgical complications with the cochlear multiple channels intracochlear implant: experience at Hannover and Melbourne. *Ann Otol Rhinol Laryngol* 100: 131-136.
17. Cervera FJ, Manrique M (2002) Complicaciones del implante codear. En: Manrique M, Huarte A *Implantes Cocleares*. Barcelona. Ed Masson 241-248.
18. Bhatia K, Gibbin KP, Nikolopoulos TP, O'Donoghue GM (2004) Surgical complications and their management in a series of 300 consecutive pediatric cochlear implantations. *Otol Neurotol* 25: 730-739.
19. Fayad J, Fraysse B, Otto S, Linthiam F (1989) Histopathological findings in 16 human temporal bones with cochlear implants In: *Cochlear Implants*. Acqu contro Bernard Fraysse 27-31.