

## Bilateral Temporal Bone Fracture Resulting in Expedited Simultaneous Bilateral Cochlear Implantation

Kyle Vankoevering and Gregory J Basura\*

Department of Otolaryngology/Head and Neck Surgery, The University of Michigan, USA

\*Corresponding author: Gregory J Basura, Assistant Professor, Department of Otolaryngology/Head and Neck Surgery, Division of Otolaryngology/Neurotology-Skull Base Surgery, The University of Michigan, 1500 E. Medical Center Drive, Ann Arbor, MI 48109, USA, Tel: (734) 936-8006; Fax: (734) 936-9625; E-mail: gbasura@med.umich.edu

Rec Date: Apr 04, 2014; Acc Date: Aug 27, 2014; Pub Date: Aug 29, 2014

Copyright: © 2014 Vankoevering K, et al. This is an open-access article distributed under the terms of the Creative Commons Attribution License, which permits unrestricted use, distribution, and reproduction in any medium, provided the original author and source are credited.

### Abstract

Temporal bone fractures following blunt force trauma can result in significant morbidity including complete hearing loss. We present the case of a 15 year-old male who suffered traumatic bilateral transverse temporal bone fractures through both cochleae, resulting in profound bilateral hearing loss. Having met criteria for cochlear implantation, he was successfully managed with expedited, simultaneous bilateral cochlear implantation preceded immediately by evoked auditory brainstem response testing. The auditory brainstem response demonstrated weak wave V activity with high-level stimulation, and placement of the cochlear implants albeit it challenging secondary to early ossification of the cochlea, was successfully performed 5 weeks post-trauma. This case underscores the importance of early diagnosis and expedited implantation following otic capsule fractures to optimize chances for meaningful hearing rehabilitation prior to ossification of inner ear structures.

**Keywords:** Auditory brainstem response; Cochlear implantation; Sensorineural hearing Loss; Temporal bone fracture

### Introduction

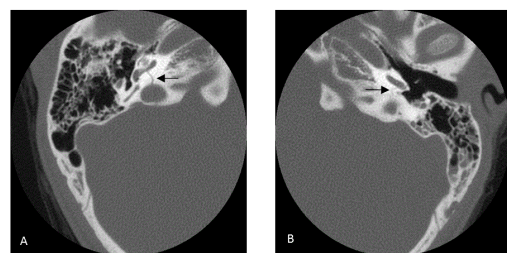
Bilateral temporal bone fractures are relatively rare in trauma due to the significant degree of force required to generate bilateral fracture patterns. These patients may suffer significant audiovestibular dysfunction, particularly in transverse fractures that involve the otic capsule. The management of profound traumatic sensorineural hearing loss (SNHL) has been well described in the literature with the use of cochlear implantation (CI; Chung et al.; Greenberg et al.; Medina et al.; Serin et al.) [1-4]. Outcomes with this approach have been promising in recent case series with the majority of patients achieving elevated sentence scores (Greenberg et al. [2]). More recently, there has been a trend towards bilateral implantation in all patients who qualify for CI owing to the improved sound localization and hearing in background noise. This trend has also recently been described in patients with traumatic deafness (Chung et al. [1]). Part of the debate regarding implantation strategies in traumatic hearing loss has been the timing of implantation, weighing the risks of cochlear ossification over possible restoration of natural hearing. We present the case of a 15 year-old male who suffered bilateral transverse otic capsule violating temporal bone fractures with expedited, simultaneous bilateral CI.

### Case Report

The patient is a 15 year-old previously healthy male who was involved in an unhelmeted ATV versus tree accident. He was found unresponsive with bilateral bloody otorrhea and taken to a local hospital where he was intubated and stabilized. Following stabilization, he was extubated on post-trauma day 3. A head CT at that time demonstrated bilateral otic capsule violating transverse temporal bone fractures and a left tripod zygomatic fracture. As his

neurologic status continued to improve, he noted bilateral profound/complete deafness. Within 10 days, he was discharged from the hospital with intact neurologic function with the exception of his hearing loss. He was subsequently transferred to University Hospital for further evaluation and rehabilitation.

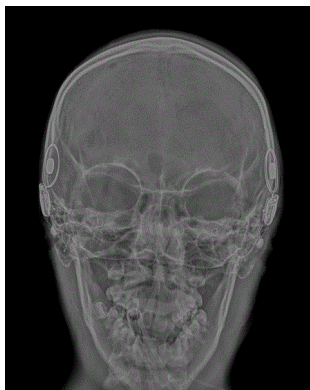Bilateral transverse temporal bone fracture patterns were noted to extend through the otic capsule and cochleae bilaterally (Figure 1). An audiogram was performed that revealed bilateral profound Sensorineural Hearing Loss (SNHL) beyond the detection of the audiometer. Subsequent expedited CI testing batteries in the best-aided conditions yielded Hearing In Noise Testing (HINT) scores of 0% bilaterally.



**Figure 1:** Axial CT scans of the temporal bones through the level of the otic capsule. Note the presence of transverse fracture patterns through the bilateral otic capsules (black arrows). Panel A (right temporal bone) reveals a fracture that extends through the base of the cochlea while panel B (left temporal bone) reveals a fracture pattern near the round window overhang and niche.

Having met criteria for CI in both ears and the known risk of significant intra-cochlear callus formation/ossification following trauma, the decision to proceed with expedited bilateral simultaneous

CI was made. The patient was taken to the OR on post-trauma day 40. In order to determine if sheer injury following the accident affected the modiolus and the connections of the cochlea to the cochlear nerve, intra-operative Electrical Auditory Brainstem Response Testing (EABR) was performed under anesthesia. Small amplitude wave V peaks with elevated thresholds of 800 mA were noted bilaterally. The elevated threshold was felt to be multifactorial, including increased impedance through likely early cochlear fibrosis as well as partial shear injury to the cochlea-cochlear nerve interface. The reproducible EABR response ultimately supported the decision to proceed with bilateral implantation. The left ear was implanted first and as the cochleostomy was performed incorporating the round window, extensive bony fibrosis/callus formation was encountered completely obscuring the lumen of the scala tympani. The cochleostomy was extended anteriomedially for approximately 3 mm into the basal turn until the lumen of the scala tympani was encountered. Given the highly altered anatomy and scar/ossification, a dummy/pilot electrode was first placed in the cochleostomy. An intra-operative X-ray confirmed a well-positioned electrode. The pilot electrode was withdrawn and the CI was inserted uneventfully. The right ear was implanted that also demonstrated bony callus and fibrosis along the cochlear basal turn requiring an extended cochleostomy. The pilot electrode was again utilized prior to definitive CI electrode placement. Following wound closure a final intra-operative X-ray demonstrated well-positioned and fully inserted bilateral implants (Figure 2).



**Figure 2:** Plain trans-orbital skull film taken intra-operatively following placement of the second cochlear implant device confirming full insertion of both electrodes within the respective cochleae.

The patient's post-operative course was uncomplicated and his implants were activated on post-operative day 20. At activation he was found to have normal thresholds at all frequencies bilaterally. The patient continues to be a daily user of his implants despite a small amount of facial nerve stimulation on the right implant but excellent performance from his left implant.

## Discussion

While the management of traumatic SNHL with CI has been well established, the purpose of this report is to discuss the expedited

nature of bilateral CI. For this patient, the extensive fracture lines involved the cochleae bilaterally making the likelihood of any significant spontaneous recovery in hearing or conventional amplification not meaningful. Bilateral CI was deemed the best and only option for hearing rehabilitation. Given the rapid rates of intra-cochlear ossification/callus formation following otic capsule fractures, expedited bilateral simultaneous CI was deemed necessary to achieve optimal auditory rehabilitation. Even at 40 days following trauma, extensive bony fibrosis/callus was found, which made CI technically challenging. To ensure proper electrode placement, pilot electrodes and intra-operative X-ray served as invaluable tools in confirming final CI electrode placement.

Performing simultaneous bilateral CI was also felt to be prudent due to the established benefits of bilateral implantation (sound localization and discrimination in background noise) as well as the challenges of a delayed second implantation given the risks of progressive ossification. Retrospective case reviews have demonstrated of those patients deemed candidates for CI following bilateral otic capsule fracture, meaningful post-implant open set speech recognition can be achieved (Greenberg et al.; Serin et al.) [2,4].

In this case, EABR was utilized in an effort to verify the cochlear nerve was still intact and had not been avulsed in the trauma. Although thresholds were elevated, the reproducible wave V indicated the nerve was still intact bilaterally. In retrospect, absent responses on the EABR would likely not have precluded implantation due to variable reliability of the test, and thus the EABR served primarily as a prognostic marker.

## Conclusion

Cochlear implantation is a well-established management strategy in the restoration of hearing in patients who suffer traumatic hearing loss. In our patient bilateral temporal bone fractures extending through the cochleae were successfully managed with bilateral simultaneous CI in an expedited fashion, due to the risks of progressive ossification of the basal turn and loss of implantable anatomy. We propose utilizing bilateral expedited implantation in all patients who suffer otic capsule violating temporal bone fractures with or without the prognostic use of EABR.

## References

1. Chung J, Shin M, Min H, Park C, Lee S (2011) Bilateral cochlear implantation in a patient with bilateral temporal bone fractures. *Am J Otolaryngol* 32: 256-258.
2. Greenberg S, Shipp D, Lin V, Chen J, Nedzelski J (2010) Cochlear implantation with bilateral severe sensorineural hearing loss after major blunt head trauma. *Otol Neurotol* 32: 48-54.
3. Medina M, Di Lella F, Di Trapani G, Prasad SC, Bacciu A, et al. (2014) Cochlear implantation versus auditory brainstem implantation in bilateral total deafness after head trauma: personal experience and review of the literature. *Otl Neurotol* 35: 260-270.
4. Serin G, Derinsu U, Sari M, Gergin O, Ciprut A, et al. (2010) Cochlear implantation in patients with bilateral cochlear trauma. *Am J Otolaryngol* 31: 350-355.