

Appendiceal Diverticulosis in Acute Appendicitis: Our Experience and Literature Review

Jaume Tur Martínez*, Joaquín Rivero Deniz, Itziar Larrañaga Blanc, Esteban García Olivares, Xavier Rodríguez Alsina and Enrique Veloso Veloso

Department of Surgery, University Hospital MútuaTerrassaa, Barcelona, Spain

*Corresponding author: Jaume Tur Martínez, Terrassa, University Hospital MútuaTerrassaa, Barcelona, Spain, Tel: 937365050/680197422; Fax: 93 736 50 04; E-mail: jaume.tur.martinez@gmail.com

Received: November 13, 2016; Accepted: November 29, 2016; Published: November 30, 2016

Copyright: © 2016 Martínez JT, et al. This is an open-access article distributed under the terms of the Creative Commons Attribution License, which permits unrestricted use, distribution, and reproduction in any medium, provided the original author and source are credited.

Abstract

Background: The appendiceal diverticulum is an uncommon pathology. Its most common clinical presentation is the appendiceal diverticulitis and the symptoms are similar to acute appendicitis. Also, it can be considered as part of differential diagnosis for chronic abdominal pain.

Aim: Analyze the prevalence in our hospital of appendiceal diverticulosis in acute appendicitis and literature review.

Methods: Retrospective description study (January 2004 to December 2013) looking for presence of appendix diverticula in 1526 patients after appendectomy due to suspicion of acute appendicitis. Review of literature for term results: "appendiceal", "appendicular", "diverticulitis", "diverticulosis".

Results: Total sample: 2058 patients operated of appendectomy; 1526 of those were to suspicion of acute appendicitis and in 38 of those we found presence of appendiceal diverticula (2.49% prevalence). Distribution: men/women (68.42%/31.57%), middle age (46.71 years). Lipton classification: Type I (28.94%), type II (34.21%), type III (21.05%) and type IV (15.78%). Other associations: carcinoid tumor (2.36%), villous adenoma (2.63%), serrated adenoma with low grade dysplasia (2.63%), perforated diverticula (7.89%), chronic diverticulitis (5.26%).

Conclusion: Prevalence is slightly higher in our series, probably because we considered only patients with acute appendicitis and not all surgical specimens with cecal appendix. According to reviewed bibliography there is possible relation with appendix neoplasias, more risk of perforation and mortality. It is a difficult pre-operative diagnosis and it has to be considered in the differential diagnosis for (acute and chronic) abdominal pain in right iliac fossa.

Keywords: Coloproctology; Diverticular disease; Diverticulitis; Appendiceal

Introduction

The appendiceal diverticulum is an uncommon pathology, described for the first time in 1893 by Kelynack. Its occurrence ranges between 0.004% and 2.1% of surgical specimen according to the referred series [1]. Appendiceal diverticula can be congenital (true) or acquired (pseudodiverticula); the latter are the more common ones (97%), located mainly at the mesenteric edge of the distal third of the appendix [2]. There are various theories about its origin, e.g. the presence of weak spots in areas of the appendiceal wall with vascular structures, the pressure rise in appendiceal lumen due to (benignant or malignant) obstruction, or secondary to inflammatory reactions [3-5]. Its most common clinical presentation is the appendiceal diverticulitis which appears with symptoms similar to acute appendicitis, though it shows a subacute presentation and absence of gastrointestinal symptoms and evidence of systemic inflammatory response. Contrary to acute appendicitis, appendix diverticulitis is related to older patients (over 30 years old), males, and patients whose history includes cystic fibrosis [6] and Hirschsprung's disease [2]. Other acute presentations can be bleeding due to broken appendix artery or as fistula between the appendix, ileum and the urinary bladder [7-9].

On the other hand, appendix diverticulosis should also be considered as part of differential diagnosis for chronic abdominal pain in right iliac fossa, mainly on those patients with abdominal pain progressing for months and where additional tests offer no results or no pathological findings can be seen even after laparoscopy [10]. Its diagnosis takes normally place in specimen with pathological anatomy, although in some cases it may be a radiologic finding, whereas via echography, CT or opaque enema [11,12]. Pre-operative diagnosis is difficult. But in case of clinical suspicion, the test which seems to provide for more information would be the thin slice CT, since this will allow us makes an appendix diverticulitis apart from an acute appendicitis [11]. Classification was described by Lipton et al. [1] and shown in Table 1.

Type I	Acute diverticulitis without appendicitis (45.7%)
Type II	Acute diverticulitis with acute appendicitis
Type III	Diverticulosis with acute appendicitis
Type IV	Diverticulosis with normal appendix
Note: Types I, II and III are subdivided also in with or without perforation.	

Table 1: Classification for diverticular disease of cecal appendix.

Besides, there are studies which relate presence of appendix diverticulosis with a higher risk of perforation on the appendix in case of appendiceal diverticulitis. Some authors state this is 4 times higher than for acute appendicitis and with a mortality 30 times higher compared to a non-complicated acute appendicitis [13]. It has also been related to pathogenesis of appendix neoplasias, such as pseudomyxoma peritonei, cystadenomas and appendix carcinoid [2,10,14,15]. As with acute appendicitis, treatment consists of an appendectomy [1].

Material and Methods

Retrospective descriptive study for the period from January 2004 to December 2013, including all patients operated at our hospital under suspicion of acute appendicitis and with anatomopathological diagnosis of appendiceal diverticulosis or appendiceal diverticulitis. Appendectomies for other pathologies were excluded. We reviewed all patients at the computerized medical history. Review of literature for term results “appendiceal”, “appendicular”, “diverticulitis” and “diverticulosis” at PubMed database. We included only articles written in English or Spanish.

Results

We completed a retrospective review of appendiceal diverticulosis in all those patients operated at our hospital, due to suspected acute appendicitis, between 2004 and 2013. We have a sample of 2085 patients operated of appendectomy; 1526 of those were due to suspicion of acute appendicitis, and in 38 of those, presence of appendiceal diverticula (Figure 1) was found, which indicates an occurrence of appendiceal diverticulosis of 2.49% with the distribution (Tables 2 and 3). Moreover, we have observed its association with other pathologies described in Table 4.

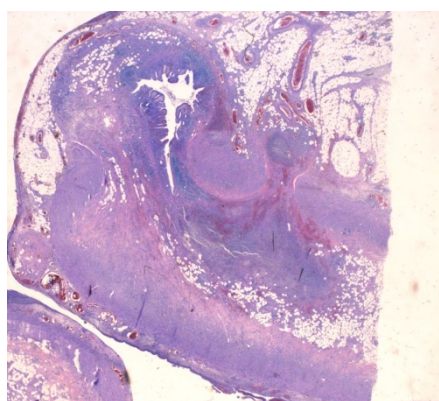


Figure 1: Section of cecal appendix with appendiceal diverticulum which protrudes through muscle layer.

	Number (%)	Age range (years)	Age average (years)
Men	26 (68.42%)	25-87	49.61
Total	38 (100%)	22-87	46.71

Table 2: Patients gender and age distribution.

Type I	28.94%
Type II	34.21%
Type III	21.05%
Type IV	15.78%

Table 3: Patients distribution according Lipton’s classification.

	Number of cases (%)
Carcinoid tumor	1 (2.63%)
Villous adenoma	1 (2.63%)
Serrated adenoma with low grade dysplasia	1 (2.63%)
Perforated diverticula	3 (7.89%)
Chronic diverticulitis	2 (5.26%)

Table 4: Other associations.

Conclusion

Results obtained by our series fulfill the characteristics described in the literature — our patients are mainly males aged over 30 on average. Prevalence stands out with a slightly higher value. This phenomenon could be explained by the fact that our series considers only patients with acute appendicitis and not all surgical specimens with cecal appendix. On the other hand, it should be remarked the presence of one case for carcinoid tumor and three cases for perforated diverticula, which constitute 2.63% and 7.89% of cases with appendiceal diverticulosis respectively. We know this is a retrospective non-comparative study with the biases this entails. According to reviewed bibliography, there is a possible relation between appendiceal diverticulum and pseudomyxoma peritonei [14] a higher probability of perforation in case of acute appendiceal diverticulitis [2,10] and higher risk of mortality [13]. All this articles are retrospective studies or series of cases, so they have a low statistic power, but even so, some authors suggest applying prophylactic appendectomies in cases of incidental finding [2,6,10].

At our series, we can see a low percentage of perforated appendiceal diverticulitis compared to that stated in literature, as happens also with the percentage of neoplasias. It should be underlined the difficulty associated with pre-operative diagnosis, since the radiologic diagnosis rate is very low in spite of the fact of having the appropriate radiologic techniques. This could be explained partly to a low clinical suspicion. For this reason, it is important to consider appendiceal diverticulitis in the differential diagnosis for (acute and chronic) abdominal pain in right iliac fossa in elderly male patients, since we will increase the number of options for a pre-operative diagnosis if we have a high clinical suspicion. It should be also taken into account the fact that appendix neoplasias and a higher risk of perforation can be linked so if we have a high index suspicion we will probably indicate an earlier surgery to avoid major complications.

References

1. Lipton S, Estrin J, Glasser I (1989) Diverticular disease of the appendix. *Surg Gynecol Obstet* 168: 13-16.

2. Abdullgaffar B (2009) Diverticulosis and diverticulitis of the appendix. *Int J Surg Pathol* 17: 231-237.
3. Payan HM (1977) Diverticular disease of the appendix. *Dis Colon Rectum* 20: 473-476.
4. Trollope ML, Lindenauer SM (1974) Diverticulosis of the appendix: a collective review. *Dis Colon Rectum* 17: 200-218.
5. Wilkie DPD (1920) Carcinoma of the appendix causing diverticula of the appendix and acute appendicular obstruction. *Br J Surg* 8: 392-396.
6. Kabiri H, Clarke LE, Tzarnas CD (2006) Appendiceal diverticulitis. *Am Surg* 72: 221-223.
7. Kawamura YJ, Sugamata Y, Yoshino K, Abo Y, Nara S, et al. (1998) Appendico-ileo-vesical fistula. *J Gastroenterol* 33: 868-871.
8. Collins DC (1963) 7000 Human appendix specimens. A final report, summarizing forty years' study. *Am J Proctol* 14: 265-281.
9. Collins DC (1955) A study of 50,000 specimens of the human vermiform appendix. *Surg Gynecol Obstet* 101: 437-445.
10. Majeski J (2003) Diverticulum of the vermiform appendix is associated with chronic abdominal pain. *Am J Surg* 186: 129-131.
11. Lee KH, Lee HS, Park SH, Bajpai V, Choi YS, et al. (2007) Appendiceal diverticulitis: diagnosis and differentiation from usual acute appendicitis using computed tomography. *J Comput Assist Tomogr* 31: 763-769.
12. Kubota T, Omori T, Yamamoto J, Nagai M, Tamaki S, et al. (2006) Sonographic findings of acute appendiceal diverticulitis. *World J Gastroenterol* 12: 4104-4105.
13. Heffernan DS, Saqib N, Terry M (2009) A case of appendiceal diverticulitis, and a review of the literature. *Ir J Med Sci* 178: 519-521.
14. Lamps LW, Gray GF, Dilday BR, Washington MK (2000) The coexistence of low-grade mucinous neoplasms of the appendix and appendiceal diverticula: a possible role in the pathogenesis of pseudomyxoma peritonei. *Mod Pathol* 13: 495-501.
15. Dupre MP, Jadavji I, Matshes E, Urbanski SJ (2008) Diverticular disease of the vermiform appendix: a diagnostic clue to underlying appendiceal neoplasm. *Hum Pathol* 39: 1823-1826.