

Anti-myelin Oligodendrocyte Glycoprotein Autoantibodies in Optic Neuritis and Venous Sinus Thrombosis in a Girl

Victor Soto-Insuga*, Thais Armangué Salvador, Laura Cabrejas Martínez, Rebeca Losada del Pozo, María Rodrigo Moreno, Cristina Ordóñez González and Jesús Rodríguez Catalán

Department of Pediatrics, Jimenez Diaz Foundation, Madrid, Spain

*Corresponding author: Department of Pediatrics, Jimenez Diaz Foundation, Madrid, Spain, Tel: 034660565897; E-mail: victorsotoinsuga@gmail.com

Rec date: January 19, 2016; Acc date: March 8, 2016; Pub date: March 13, 2016

Copyright: © 2016 Soto-Insuga V et al. This is an open-access article distributed under the terms of the Creative Commons Attribution License, which permits unrestricted use, distribution, and reproduction in any medium, provided the original author and source are credited.

Abstract

The anti-myelin oligodendrocyte glycoprotein autoantibody (anti-MOG) is recognized as a new diagnostic and prognostic markers in paediatric acquired demyelinating diseases of the central nervous system. We report a 6 years girl who developed a venous sinus thrombosis and signs of intracranial hypertension after acute otitis media. One month after this infection the patient had an episode of unilateral optic neuritis associated with anti-MOG in serum. Our patient received intravenous steroid treatment and showed a highly favourable response. This is the first case report of demyelinating disease with anti-MOG antibodies associated with thrombophilia.

Keywords: Anti-myelin oligodendrocyte glycoprotein autoantibody (Anti-Mog); Aquaporin-4 antibodies (Aqp-4); Optic neuritis; Venous sinus thrombosis

Introduction

There are numerous paediatric diseases caused by autoimmune mechanisms; in many cases, these diseases present diagnostic challenges. The diagnostic and pathogenic role of neuronal autoantibodies is increasingly recognised both in demyelinating diseases (such as aquaporin-4 [AQP-4] antibodies in neuromyelitis optica) and autoimmune encephalitis (such as N-methyl-D-aspartate receptor [NMDAR] antibodies). Recent data indicate that antibodies directed against myelin oligodendrocyte glycoprotein (MOG) could be useful as diagnostic and prognostic markers in paediatric acquired demyelinating diseases of the central nervous system [1]. We present the first case of demyelinating disease (optic neuritis) with MOG antibodies associated with venous sinus thrombosis.

Case study

A 6-year-old girl with normal psychomotor development and with no family or personal history of importance was admitted for consultation for a headache after an acute otitis media episode 1 month earlier. The headache was frontal, daily and high-intensity and was associated with vomiting and phonophobia/photophobia. For the last three days, the patient had associated intermittent binocular diplopia. The examination revealed the presence of grade 2 bilateral papilloedema. A cranial angio-MR with contrast revealed a venous thrombosis of the transverse sinuses, sigmoid, right sinus and left internal jugular vein, with signs of recanalisation but no signs of mastoiditis or otitis. A lumbar puncture showed mild pleocytosis (82 reactive lymphocytes) and a CSF opening pressure of 23 cm H₂O. Treatment was therefore initiated for intracranial hypertension with oral acetazolamide (10 mg/kg/d) and low-molecular-weight heparin anticoagulation. Fifteen days after the consultation (1.5 months after the acute otitis media episode), the patient reported worsening headache along with dyschromatopsia. The examination revealed an

afferent defect in the right pupil and a severe reduction in visual acuity in the right eye (for light perception), with normal visual acuity in the left eye. A new cranial and orbital MRI revealed thickening and a signal change of the right optical nerve, with no other associated demyelinating lesions (Figure 1), along with a reduction in the amplitude of the visual evoked potentials of the right optical nerve and increased thickness of the retinal nerve fibre layer (RNFL) in the optical coherence tomography (OCT), which was greater in the right eye. The CSF study revealed an increase in opening pressure of 27 cm H₂O, persistence of pleocytosis (60 leukocytes /mm³), absence of oligoclonal bands, normal CSF cytology and normal protein and glucose concentrations. The blood tests revealed immunoglobulin A deficiency (IgA 2 mg/dl), and the sedimentation rate was slightly increased (44 mm/h). The aetiological study was completed through the implementation of the following tests: spine MRI, hepatic, renal, thyroid function tests, ferritin, B12 and A vitamins, echo-Doppler of the heart and jugular veins, autoimmunity study (antinuclear antibodies, antiphospholipid, rheumatoid factor, complement) and serologies (Citomegalovirus, Epstein-Barr Virus, Mycoplasma Pneumoniae, Borrelia Burgdorferi, Human Immunodeficiency Virus, Syphilis), which were normal. The coagulation study, which included PT, PTT, PNP, APT, Factor V Leyden, homocysteine, Protein C, Protein S, antithrombin antigen, MTHFR SNP analysis, was also normal.

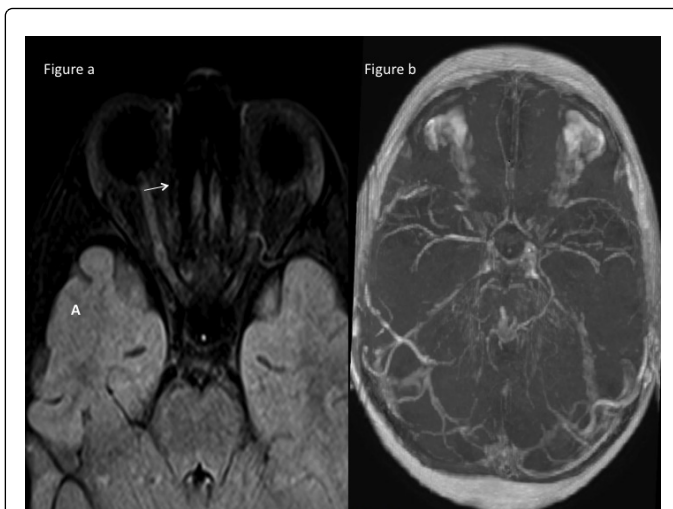


Figure 1: A: IMR 3T; Axial T2 dark-fluid: right optic nerve which appears swollen with high signal (arrow). B: IMR 1,5T; MIP image from IMR venography with filling defects in the transverses sinuses and left sigmoid sinus. Multiples prominent veins are draining to Galeno vein, petrous sinus and cortical veins.

The reading of MOG antibodies in serum and CSF through an assay of live cells transfected with this protein was positive at a titre of 1/1280. No antibodies against AQP4 or against neuronal surface antigens were detected in the patient's serum or CSF.

Suspecting optical neuritis, treatment was initiated with intravenous methylprednisolone (20 mg/kg/d) for three days and subsequently oral prednisone (2 mg/kg/d) for a month, with subsequent progressive withdrawal. The patient showed a highly favourable response, with complete recovery of visual acuity and of the papilloedema 1 month after starting the treatment. Anticoagulation with low-molecular-weight heparin was maintained for 4 months, with subsequent antiplatelet treatment with acetylsalicylic acid (aspirin). After 10 months of follow-up, the patient has remained asymptomatic, with no recurrence of headache or demyelinating or thrombotic phenomena. The patient has reported no thrush or other systemic autoimmune symptoms. The measurement of MOG antibodies in serum at 4 and 8 months remained positive, but titers had a significant progressive decrease over months (1/1280 in the beginning, 1/640 at 4 months and 1/320 at 8 months) (Figure 2).

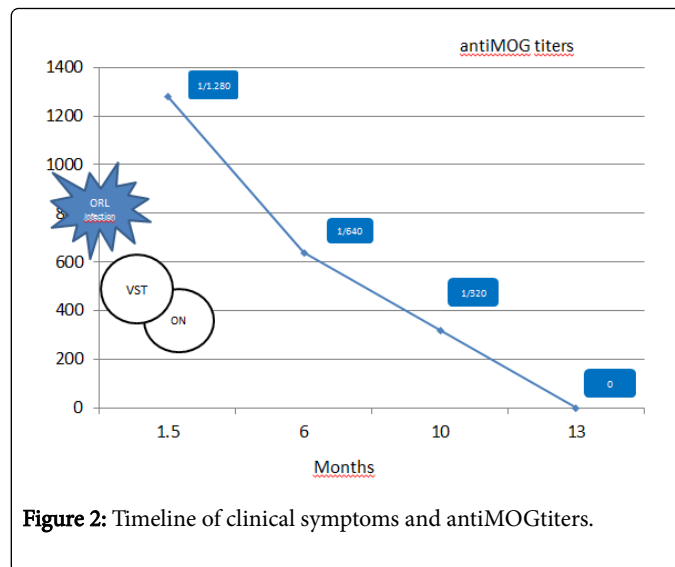


Figure 2: Timeline of clinical symptoms and antiMOG titers.

Discussion

The diagnostic hypothesis of our patient's clinical condition is the activation of an inflammatory mechanism after an acute otitis media episode that caused venous sinus thrombosis (with subsequent development of secondary intracranial hypertension) and unilateral optical neuritis associated with MOG antibodies 1.5 months after the start of the infection. Both venous sinus thrombosis and optic neuritis are uncommon conditions in children, with an incidence of 0.34/100,000 and 3/100,000, respectively (excluding the neonatal period). We believe that the close temporal relationship of these conditions and the presence in the blood of MOG antibodies in this case point to a common pathophysiological mechanism.

Although venous thrombosis is related to parameningeal infections such as otogenic infections, the lack of signs of mastoiditis and the severity of the thrombosis symptoms in our patient required us to rule out other causes of thrombophilia [2]. Therefore, although our patient has not presented thrush or other systemic inflammatory signs, close patient follow-up is necessary to check that she does not develop a rheumatological condition such as Behçet's disease and systemic lupus erythematosus (SLE), which are frequently associated with prothrombotic phenomena and are a common cause of stroke. Additionally, this risk is increased in our case due to the close relationship between rheumatological disorders and a number of demyelinating conditions. This is the case, for example, for lupus myelitis, which has traditionally been assumed to be a vasculopathic complication of SLE but which currently is known as part of the spectrum of neuromyelitisoptica, given that these patients present IgG antibodies against AQP4 [3]. Therefore, it is logical to conclude that a common inflammatory pathway causes demyelinating disorders related to MOG antibodies and also promote hypercoagulability conditions such as venous sinus thrombosis.

Myelin oligodendrocyte glycoprotein (MOG) is a protein exclusively expressed on the surface of oligodendrocytes and myelin in the central nervous system. The presence of MOG antibodies has been demonstrated in recent years in up to 27% of paediatric demyelinating disorders. Initially, these antibodies were related to conditions of acute disseminated encephalomyelitis (27-44%), but MOG antibodies have subsequently been found in the serum of children with anti-AQP4-

negative neuromyelitis optica (0-38%), optic neuritis (12-56%) (Monophasic and recurrent forms), transverse myelitis, multiple sclerosis (0-28%) and clinically isolated syndrome (0-36%) [4-6]. Although there are increasing amounts of clinical data that suggest a pathogenic role for these antibodies. There are several indications that human MOG-IgG antibodies can induce cytotoxicity mediated by complement and cellular antibodies in vitro and in vivo, but convincing in vivo studies using MOG-IgG from patients with acquired central nervous system demyelinating diseases are still lacking [7]. The presence of MOG antibodies could reflect an underlying pathogenic mechanism, a secondary immune reaction, a bystander activation or even a beneficial effect. The use of MOG antibodies as a biological marker in the diagnosis of CNS demyelinating diseases remains limited. Moreover there are more questions that are not responded like the positivity of anti MOG antibodies in pediatric age could be an early marker of disimmune reactions to infections and could it be related to the subsequent develop in adult age of autoimmunity, or even if we could assume that this case is a tip of the iceberg in parallel with elevations of this autoantibodies in very young age after infections. So, prospective studies are needed to assess the clinical relevance of MOG antibodies for diagnosis, prognosis and treatment [8].

The presence of MOG antibodies in our patient supports the hypothesis that venous sinus thrombosis and optic neuritis are autoimmune events triggered by an infection. A sign of good prognosis could be the fact that anti-MOG titers have declined, because it could imply that the demyelinating disorder was something temporary or monophasic.

Although the relationship between thrombophilia and autoimmune disorders is widely known, this is the first published case in which a

thrombotic event (venous sinus thrombosis) and a demyelinating event (optic neuritis) were related to the presence of MOG antibodies.

References

1. Reindl M, Di Pauli F, Rostásy K, Berger T (2013) The spectrum of MOG autoantibody-associated demyelinating diseases. *Nat Rev Neurol* 9: 455-461.
2. Nakashima MO, Rogers HJ (2014) Hypercoagulable states: an algorithmic approach to laboratory testing and update on monitoring of direct oral anticoagulants. *Blood Res* 49: 85-94.
3. Elbers J, Benseler SM (2010) Central nervous system vasculitis. Inflammatory and autoimmune disorders of the nervous system in children (1st edn.), Mac Keith, London.
4. Brilot F, Dale RC, Selter RC, Grummel V, Kalluri SR, et al. (2009) Antibodies to native myelin oligodendrocyte glycoprotein in children with inflammatory demyelinating central nervous system disease. *Ann Neurol* 66: 833-842.
5. Rostasy K, Reindl M (2013) Role of autoantibodies in acquired inflammatory demyelinating diseases of the central nervous system in children. *Neuropediatrics* 44: 297-301.
6. Mader S, Gredler V, Schanda K, Rostasy K, Dujmovic I, et al. (2011) Complement activating antibodies to myelin oligodendrocyte glycoprotein in neuromyelitis optica and related disorders. *J Neuroinflammation* 8: 184.
7. Zhou D, Srivastava R, Nessler S, Grummel V, Sommer N, et al. (2006) Identification of a pathogenic antibody response to native myelin oligodendrocyte glycoprotein in multiple sclerosis. *Proc Natl Acad Sci U S A* 103: 19057-19062.
8. Ramanathan S, Dale RC, Brilot F (2016) Anti-MOG antibody: The history, clinical phenotype, and pathogenicity of a serum biomarker for demyelination. *Autoimmun Rev* 15: 307-324.