

## Anterior Approach for Thoracolumbar Fracture Dislocations: Surgical Management in Poor Resource Region, Record of 7 years Follow-up

Aram Baram<sup>1\*</sup>, Ali A Alwan Al-Tameemi<sup>2</sup> and Warzer Fatah Shali<sup>3</sup>

<sup>1</sup>Department of Surgery, School of Medicine, Faculty of Medical Sciences, University of Sulaimani, Department of Thoracic and Cardiovascular Surgery, Sulaimani Teaching Hospital, Iraq

<sup>2</sup>Department of Surgery, School of Medicine, Faculty of Medical Sciences, University of Sulaimani, Sulaimani Teaching Hospital, Iraq

<sup>3</sup>Department of Orthopedics and Fracture, 46001 Sulaymaniyah, Iraq

### Abstract

**Introduction:** Thoracolumbar fracture dislocation is a trauma of high energy which generally is treated with long-segment stabilization. Anterior spine exposure may be used alone or in combination with a posterior midline approach in a staged or sequential fashion. In this study, we report the 7-years' experience of the anterior approach to the thoracolumbar spine fracture dislocations at a single institution.

**Patients and methods:** Over a 7-year period (2007–2014), 15 patients (9 males and 7 females) with a mean age of 41.1 years ranging between 25 and 61 years, were operated on using an anterior approach at our institution. All patients were submitted to standard anterior spine surgery, thoracotomy (in 9 patients), thoracophrenolombotomy (in 3 patients) and lumbotomy (in 2 patients), one patient required left thoracotomy alone. In all cases, we used heavy duty plate fixation and autologous bone (rib or vertebral bone) inside the cylinder. The criteria for surgical intervention were: partial or progressive neurologic deficit, kyphotic angulation  $\geq 25^\circ$  at one segment, progressive kyphosis, lesion with a loss of 50% of vertebral height with angulation and a residual canal diameter 50% of normal. All patients had a failure of the anterior and middle columns as viewed on a CT scan or MRI if available.

**Results:** The average duration of follow-up was 24 months. One patient died during the follow-up period. Concerning etiology, there were two types of vertebral body lesions, which were traumatic and infectious. There were also 12 patients with traumatic lesions. The mean age was 41.1 years (range 25-61). There were 10 males and 5 female patients. Six patients had a burst fracture (type A3), with compression failure of the anterior and middle columns of the spine (level T12 in 3, level T11 in 1, level L1 in 2). All patients with traumatic lesions underwent single-stage anterior fixation by heavy duty conventional plate and screw and the gap filled with autograft (rib and morselized vertebral bone). Three patients were operated because of the thoracic and lumbar tuberculous spondylitis and Hydatid cyst (one patient T9, one at T10, one T5).

**Discussion:** Initial reports of the anterior thoracotomy approach to the thoracic spine were related to Pott's disease, spine surgery innovations and aging with a more active population resulting in a progressive increase in spine instrumentation. The main indication for anterior decompression is an incomplete neurological injury with radiographically demonstrated neural compression by bone or disk fragments. The anterior surgical treatment allows direct decompression of the neural elements and correction of the deformity.

**Conclusion:** The anterior approaches provide excellent exposure of the relevant bony anatomy and can be used to secure anterior column support with bony fusion. Anterior spinal fusion surgery is a safe procedure and can be used with confidence when the nature of a patient's spinal disorder dictates its use.

**Keywords:** Thoraco-lumbar fracture spine; Anterior approach; Plate; Screw fixation

### Introduction

Thoracolumbar fracture dislocation is a trauma of high energy which is generally is treated with long-segment stabilization. Surgical approach to the spine might be simply classified into anterior, posterior or the combined approach [1]. Open surgical approaches for the treatment of thoracolumbar fractures either by an anterior or posterior techniques require extensive exposure and often lead to significant postoperative pain and morbidity. Each has its role and the choice of the best approach depends on several factors, such as the level of the disease in the spine, the extent of the lesion and the need of spinal reconstruction or stabilization [2,3]. Anterior spine exposure may be used alone or in combination with a posterior midline approach in a staged or sequential fashion. The anterior approach presents several advantages, among which are the direct access to the lesion, less surgical bleeding and low risk of infection and the use of shorter segment fixation devices. Often neurosurgeons and orthopedic surgeons require the assistance of thoracic surgeons to provide an adequate access during the anterior approach to the spine [4]. In this study, we report the 7-years' experience of the anterior approach to the thoracolumbar spine fracture dislocations at a single institution [5,6].

### Patients and Methods

Over a 7-year period (2007–2014), 15 patients (9 males and 7 females) with a mean age of 41.1 years, ranging between 25 and 61 years, were operated on using an anterior approach at our institution. The indication for surgery was fracture dislocations of the thoracolumbar spine (Table 1). A careful assessment of the pulmonary and cardiac function was performed, starting with a clinical evaluation and proceeding to pulmonary function and blood gas analysis.

**\*Corresponding author:** Dr. Aram Baram MD, MRCS Ed., FACS, Department of Surgery, University of Sulaimani, Faculty of Medical Sciences /School of Medicine, François Mitterrand Street, Sulaymaniyah 46001 Iraq, Tel: +964 7701511478, +96453321009; E-mail: [aram.baramm@gmail.com](mailto:aram.baramm@gmail.com)

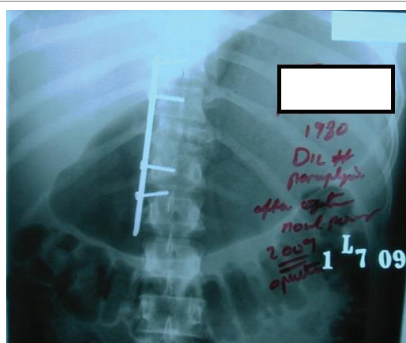
**Received** September 08, 2016; **Accepted** September 19, 2016; **Published** September 21, 2016

**Citation:** Baram A, Al-Tameemi AAA, Shali WF (2016) Anterior Approach for Thoracolumbar Fracture Dislocations: Surgical Management in Poor Resource Region, Record of 7 years Follow-up. J Spine 5: 331. doi: [10.4172/2165-7939.1000331](https://doi.org/10.4172/2165-7939.1000331)

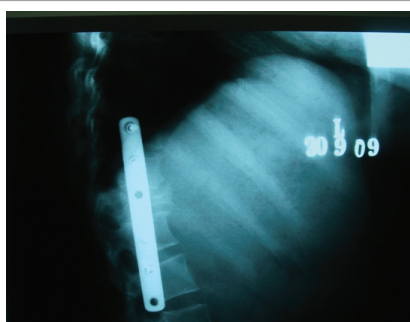
**Copyright:** © 2016 Baram A, et al. This is an open-access article distributed under the terms of the Creative Commons Attribution License, which permits unrestricted use, distribution, and reproduction in any medium, provided the original author and source are credited.

Number	Age(years)/Sex	Clinical finding	Diagnosis	Associated injury	Other Causes	Approach
1	34/ F	Paraparesis/weak sphincters	Wedge # D9	Cranial trauma		Right thoracic
2	56/M	Paraplegia /D9 sensory level	Burst # D7-7	Chest trauma		Right thoracic
3	40/M	Left lower limb monoparesis	Wedge # D11-12			Right thoracic
4	54/M	Paraplegia / D10 sensory level	Wedge D8-9		TB	Right thoracic
5	43/ M	Paraparesis	Wedge L2			Left lumbotomy
6	34/F	Paraplegia / L1 sensory level	Burst# D12	Chest trauma		Right thoracic
7	61/M	Paraparesis / weak respiratory muscles	Burst # D9-8			Right thoracic
8	39/F	Paraplegia /D12 sensory level	Burst 3 D10		Hydatid cyst	Right thoracic
9	42/M	Paraplegia / L2 sensory level	Wedge L1			Left lumbotomy
10	29/M	Paraplegia / L2 sensory level	Wedge L1			Left thoracoabdominal
11	30/F	Paraparesis	Wedge L2			Left thoracoabdominal
12	38/M	Paraplegia / D12 sensory level	Wedge D10			Right thoracic
13	53/M	Right lower limb monoparesis	Wedge L1	Chest trauma		Left thoracoabdominal
14	49/M	Paraplegia/ D10 sensory level	Burst # D8			Right thoracic
15	25/F	Paraplegia / D 9 sensory level	Burst # D5		Hydatid cyst	Left thoracic

**Table 1:** Patients characteristics.



**Figure 1:** Fusion with autologous bone (rib) and metallic osteosynthesis was performed.



**Figure 2:** Radiographic study after surgery showed satisfactory decompression and correction of deformities.

Risk stratification was carried out on all patients prior to operation for both cardiac and pulmonary complications. All patients were submitted to standard anterior spine surgery: thoracotomy (in 9 patients), thoracophrenolumbotomy (in 3 patients) and lumbotomy (in 2 patients), one patient that required thoracotomy was left alone. In all cases, we used heavy duty plate fixation and autologous bone (rib or vertebral bone) inside the cylinder.

The criteria for surgical intervention were: partial or progressive neurologic deficit, kyphotic angulation  $\geq 25^\circ$  at one segment, progressive kyphosis, lesion with a loss of 50% of vertebral height with angulation and a residual canal diameter 50% of normal. All patients had a failure

of the anterior and middle columns as viewed on CT scan or MRI if available. One of the criteria included was severe burst fractures.

Intraoperative fluoroscopy was usually required to confirm the proper level of access placing a spinal needle into the target disc space. The most common procedure was thoracotomy and this was employed in 9 patients (60 %) using single lung ventilation. The preferred approach was from the right side while for patients with lumbar spine fracture, the left lateral muscle lumbotomy incision was decided or according to the spine. An incision was made approximately one or two intercostal spaces above the target vertebral body or disk level. Every attempt was made to avoid segmental artery ligature, especially when approaching the spine from the left side. In some cases, we did a partial rib resection and the bone was used as an autograft. One patient (6.6%) required a left thoracic spine exposure. Special care was taken to preserve at least a 1 cm diaphragmatic margin along the chest wall to allow reattachment during closure. Adequate postoperative pain control with intercostal blocks and non-steroidal drugs, incentive spirometry and early mobilization if not contraindicated was instituted to minimize the risk of pulmonary complications.

## Results

The average duration of follow-up was 24 months. One patient died during the follow-up period. Concerning etiology, there were two types of vertebral body lesions, these were the traumatic and infectious. There were 12 patients with traumatic lesions. Vertebral lesions were classified by the Magerl et al. [7] scheme modelled on the AO classification of limb fractures. The mean age was 41.1 years (range 25-61). There were 10 males and 5 female patients. Six patients had a burst fracture (type A3), with compression failure of the anterior and middle columns of the spine (level T12 in 3, level T11 in 1, level L1 in 2). None of them had a complete lesion. Two patient presented unstable fracture dislocation (type C1) of the thoracolumbar spine and had a complete deficit. All patients with traumatic lesions underwent single-stage anterior fixation by heavy duty conventional plate and screw and the gap filled with autograft (rib and morselized vertebral bone). The cases of unstable fracture dislocation also had been treated by open reduction, short segment fixation, and fusion.

Three patients were operated because of the thoracic, lumbar tuberculous spondylitis and Hydatid cyst (one patient T9, one at T10, one T5). Fusion with autologous bone (rib) and metallic osteosynthesis was performed (Figure 1). Prolonged chemotherapy was administered postoperatively.

Patient no.	Type of complication	Management
No 10,11,13,15	Superficial wound	Appropriate antibiotic therapy
No3 N10	Hemothorax	Drainage by tube thoracotomy
No 5	Horner Syndrome	Spontaneous recovery
No 8	Screw loosening	Follow-up
No 10	Haematoma	Non specific
No 7	Urinary tract infection	Appropriate antibiotic therapy
No 1	DVT and Pulmonary Embolism	Anticoagulant therapy

**Table 2:** Complications.

On the 12<sup>th</sup> day after the surgery, the patient number 5, who developed severe paraparesis, experienced dyspnea and chest pain after the standing and walking exercise, and lethal pulmonary thromboembolism was diagnosed. Computed tomography (CT) and radiographic study after surgery showed satisfactory decompression and correction of deformities (Figure 2). The mean preoperative canal compromise was 50% (range, 20-90) and the percent collapse of the anterior cortex was 60% (range, 10-70). After surgery, canal compromise was 8%, and radiographic height had been restored to 80% of the adjacent levels. When present, preoperative kyphosis improved to a mean of 110 (range, 8-20). At the time of follow-up, no loss of reduction or fixation was noted in any patient and a satisfactory functional result was found in all patients. CT examinations with sagittal and coronal reconstructions were effective for evaluation of fusion. The average operative time was 360 minutes (range, 210- 360) and the average length of hospitalization after surgery was 14 days. The mean estimated blood loss was 1700 cc (range, 300-3500). Three major or permanent neurologic deficits were encountered. There were no cases of neurologic worsening vascular complications, CSF leakage, pneumothorax, diaphragmatic rupture and no plate or screw fractures. One case of screw loosening was related above. Two patients reported minimal pain or no pain at final follow-up observation. None reported severe pain or taking narcotic medications. After surgery (at T5), one patient developed a right-sided Horner's syndrome that was resolved five months later. There were two cases of hemothorax related to the surgical approach and they were treated with irrigation of the pleural cavity and new chest tube. One patient had complained passing inguinal hematoma attributed to psoas muscle traction. Other complications like urinary infection, superficial infection, and deep venous thrombosis and thromboembolism were related to the primary disease and patient clinical condition (Table 2).

Most of our patients (85%) described an important improvement in the quality of their life and performance status according to Karnofsky scoring system.

## Discussion

Initial reports of the anterior thoracotomy approach to the thoracic spine were related to Pott's disease, spine surgery innovations and aging with a more active population resulted in a progressive increase in spine instrumentation. The classic posterior surgical approach to the spine is associated with longer operative time, significant blood loss and high incidence of postoperative pain [8]. The anterior approach is associated with a reduction of the operative time and blood loss, less postoperative pain and early ambulation. Furthermore, the anterior exposure minimizes damage to the posterior ligamentous structures of the spinal cord and segmental roots. Kaneda et al. developed an anterior device that combined two vertebral staples and two cross-linked longitudinal rods [9,10].

Zdeblick reported the use of a Z-plate for stabilization following anterior column reconstruction [11]. We had used a similar anterior

plating system. Advantages of the Z-plate system include the plate design, which allows for distraction, and compression and conforms to the normal contour of the thoracolumbar spine. Anterior approaches to the spine is a good option for the correction of metastatic, congenital, degenerative, traumatic, and other conditions. The anterior column can be reconstructed with autograft, allograft, or methylmethacrylate, all of which can be augmented with prostheses such as Harms cages [12,13].

The main indication for anterior decompression is an incomplete neurological injury with radiographically demonstrated neural compression by bone or disk fragments. Since the compressive tissues following a thoracolumbar burst fracture are invariably located in the anterior spinal canal, better results can be obtained by the direct removal of the retropulsed bone and soft tissue fragments from the spinal canal to relieve the pressure from the spinal cord, the cauda equina, and anterior spinal reconstruction and fusion [14-16].

The anterior surgical treatment allows direct decompression of the neural elements and correction of the deformity. Newer anterior instrumentation devices, combined with a structural graft, allow a stable construct that may obviate a posterior procedure. An anterior procedure generally requires a fusion of only two levels compared to posterior fusion, which generally requires more [17-19]. Through posterior distraction, limited vertebral height restoration, kyphotic reduction and indirect reduction of spinal canal encroachment was possible [20-22]. Using posterior distraction, canal encroachment is improved indirectly by ligamentotaxis. Alternatively, a transpedicular or costotransversectomy decompression technique can be used [23]. Canal decompression is limited, though, and often incomplete. In addition, short segment fixation has been associated with a high rate of hardware failure with a recurrence of deformity [24,25]. Short segment instrumentation with pedicle screws has been associated with a higher rate of construct failure ranging from 9 to 54%. Also, the increase in kyphosis after posterior surgery ranged from three to 12 degrees [21,22,26,27]. That is particularly true in cases of the tumor.

Fourney et al. reported their experience with pedicle screw fixation in the management of 100 consecutive cases of spinal column tumors [28]. They concluded that posterior stabilization alone is usually inadequate for managing most spinal tumors because the anterior column is frequently involved with the disease. Posterior elements disruption, including laminar fracture, spinous process split, or nondisplaced facet fracture do not preclude anterolateral plate treatment [21]. One of our patients with burst fracture who also had posterior instrumentation performed showed posterior elements fractured, although the anterior surgery had seemed to reach a good result. Despite one of our patients having a fracture dislocation, in what would be a relative contraindication for Zplate, we had obtained a good result in terms of reduction and stability. We had also succeeded on to treat spine infectious disease with autologous bone and instrumentation. In two of the infection cases, the anterior surgery, also allowed the proper psoas abscess drainage. Benli et al. reported the surgical results of 63 patients with Pott's disease who underwent anterior radical debridement with anterior fusion and anterior instrumentation (23 patients with Z-plate). They concluded that this procedure is a safe and effective method in the treatment of tuberculosis spondylitis [29].

Option for autografting include the resected rib, vascularized rib, iliac crest, free fibula, and vascularized fibula. Some authors advocate the use of allograft [30]. Each technique varies in its level of sophistication, technical demands, morbidity from the donor site, and mechanical stability. The Iliac crest is preferred due to its relatively



broad surface area, strength in compressive loading, and a favorable ratio of cancellous to cortical bone [31]. Also, it worth mentioning that the Iliac graft was not necessary in any of our cases. Autologous grafting, following through debridement, has been shown to be safe even in the presence of active pyogenic [32].

The reconstruction with the titanium mesh cage is usually is supplemented with anterior instrumentation. Anterior bone grafts alone, are subject to a high rate of nonunion (10-20%) [33], this is because they are unable to withstand the compressive load of an erect spine, and are unable to provide adequate rotational stability. Therefore, most authors feel that anterior decompression requires some form of internal fixation. Internal spinal fixation helps fusion to occur, correct deformities, and provide early biomechanical stabilization following a discectomy, corpectomy, and decompression, a depth gauge is used to measure the coronal diameter of the vertebral body. The starting point for the insertion of the first bolt is approximately 1 cm anterior to the base of the pedicle and 1 cm cephalad to the inferior endplate of the inferior vertebral body.

We have noticed some aspects that demand variation on this technique. The cases of discitis have a particular difficulty. After proper radical debridement, only part of the superior and inferior vertebra is left. Due to the exiguous quantity of healthy bone, it demands the ability to place the screws or extend the corpectomy. It is not uncommon to have enough room for only one screw. Another observation is that when we consider a second and posterior approach we must have in mind the suitability of the classical technique [33]. The insert point of the anterior screw should allow the placement of the pedicle screw. Complications are often specific approach.

There were two cases of hemothorax in our series. In light of this rate of complication, we had introduced several measures in an attempt to avoid this problem. At the end of the surgical procedure, extensive irrigation is conducted prior to closing. We must keep in mind that neoplasm, infectious diseases are prone to hemorrhage, and we must pay more attention to hemostasis and to consider the use of double thoracic drain or continuous aspiration. Adequate exposure of the lumbar spine requires careful dissection to mobilize the psoas and retract it posteriorly, taking care not to injure the genitofemoral nerve. The traction over psoas can justify the occurrence of transient dysesthesia in one of our patients.

## Conclusion

The anterior approach provides excellent exposure of the relevant bony anatomy and can be used to secure anterior column support with bony fusion. It is possible to direct visualization for anterior decompression and stabilization through a single-stage approach and lessen the need for second-stage posterior stabilization. Anterior instrumentation alone can usually be used if decompression is isolated to one or two levels, if the posterior column is not very damaged, and if there is no severe translation instability.

Anterior spinal fusion surgery is a safe procedure and can be used with confidence when the nature of a patient's spinal disorder dictates its use.

## Acknowledgement

We would like to acknowledge all our personnel who assisted in serving our patients.

## Conflict of Interest

The authors declare that they have no conflicts actual or potential conflict (including financial, consultant, institutional and other relationships) of interest in relation to this article exists.

## Author's Contribution

Aram Baram: surgeon performed the surgeries, study design, follow-up, data collection, statistical analysis.

Ali A. Alwan Al-Tameemi: study design, follow-up, data collection, statistical analysis.

Warzer F. Shali: study design, follow-up, data collection, statistical analysis.

## Funding

This research received no specific grant from any funding agency in the public, commercial, or not-for-profit sectors.

## References

1. Gokaslan ZL, York JE, Walsh GL, McCutcheon IE, Lang FF, et al. (1998) Transthoracic vertebrectomy for metastatic spinal tumors. J Neurosurg 89: 599-609.
2. Pettiford BL, Schuchert MJ, Jeyabalan G, Landreneau JR, Kilic A, et al. (2008) Technical challenges and utility of anterior exposure for thoracic spine pathology. Ann Thorac Surg 86: 1762-1768.
3. DeWald RL, Bridwell KH, Prodromas C, Rodts MF (1985) Reconstructive spinal surgery as palliation for metastatic malignancies of the spine. Spine 10: 21-26.
4. Janik JS, Burrington JD, Janik JE, Wayne ER, Chang JH, et al. (1997) Anterior exposure of spinal deformities and tumors: a 20 year experience J Pediatr Surg 32: 852-895.
5. Xiao ZM, Zhan XL, Gong De F, De Li S (2007) Surgical management for upper thoracic spine tumors by a transmanubrium approach and a new space. Eur Spine J 16: 439-444.
6. Korst RJ, Burt ME (1998) Cervicothoracic tumors: results of resection by the 'hemi-clamshell' approach. J Thorac Cardiovasc Surg 115: 294-295.
7. Magerl F, Aebi M, Gertzbein SD, Harms J, Nazarian S (1994) A comprehensive classification of thoracic and lumbar injuries. Eur Spine J 3: 184-201.
8. De-Wald RL, Bridwell KH, Prodromas C, Rodts MF (1985) Constructive spinal surgery as palliation for metastatic malignancies of the spine. Spine 10: 21-26.
9. Kaneda K, Abumi K, Fujiya M (1984) Burst fractures with neurologic deficits of the thoracolumbar-lumbar spine. Results of an anterior decompression and stabilization with anterior instrumentation. Spine 9: 788-795.
10. Kaneda K, Taneichi H, Abumi K, Hashimoto T, Satoh S, et al. (1997) Anterior decompression and stabilization with the Kaneda device for thoracolumbar burst fractures associated with neurological deficits. J Bone Joint Surg Am 79: 69-83.
11. Zdeblick TA (1994) The Z-plate: a new system for anterolateral thoracolumbar instrumentation. In: 9th Annual Meeting of the North American Spine Society; 1994 Oct 19-22; Minneapolis, USA.
12. DeWald RL, Bridwell KH, Prodromas C, Rodts MF (1985) Reconstructive spinal surgery as palliation for metastatic malignancies of the spine. Spine 10: 21-26.
13. Whitehill R, Barry JC (1985) The evolution of stability in cervical spinal constructs using either autogenous bone graft or methyl-methacrylate cement. A follow-up report on a canine in vivo model. Spine 10: 32-41.
14. Dunn HK (1984) Anterior stabilization of thoracolumbar injuries. Clin Orthop Relat Res 189: 116-124.
15. Kaneda K, Abumi K, Fujiya M (1984) Burst fractures with neurologic deficits of the thoracolumbar spine. Results of anterior decompression and stabilization with anterior instrumentation. Spine 9: 788-795.
16. Bradford DS, McBride GG (1987) Surgical management of thoracolumbar spine fractures with incomplete neurologic deficits. Clin Orthop Relat Res 218: 201-216.
17. Carl AL, Tromanhauser SG, Roger DJ (1992) Pedicle screw instrumentation for thoracolumbar burst fractures and fracture-dislocations. Spine 17: S317-24.
18. Esses SI, Botsford DJ, Kostuik JP (1990) Evaluation of surgical treatment for burst fractures. Spine 15: 667-673.
19. Haas N, Blauth M, Tscherne H (1991) Anterior plating in thoracolumbar spine injuries. Indication, Technique, and Results. Spine 16: S100-11.
20. Crutcher JP, Anderson PA, King HA, Montesano PX (1991) Indirect spinal canal decompression in patients with thoracolumbar burst fractures treated by posterior distraction rods. J Spinal Disord 4: 39-48.

21. Fredrickson BE, Mann KA, Yuan HA, Lubicky JP (1988) Reduction of the intracanal fragment in experimental burst fractures. Spine 13: 267-271.
22. McAfee PC, Yuan HA, Lasda NA (1982) The unstable burst fracture. Spine 7: 365-373.
23. Zdeblick TA, Shirado O, McAfee PC, De Groot H, Warden KE (1991) Anterior spinal fixation after lumbar corpectomy. A study in dogs. J Bone Joint Surg Am 73: 527-534.
24. Ebelke DK, Asher MA, Neff JR, Kraker DP (1991) Survivorship analysis of VSP spine instrumentation in the treatment of thoracolumbar and lumbar burst fractures. Spine 16: S428-432.
25. Gertzbein SD (1992) Scoliosis Research Society. Multicenter spine fracture study. Spine 17: 528-540.
26. McLain RF, Sparling E, Benson DR (1993) Early failure of short-segment pedicle instrumentation for thoracolumbar fractures. A preliminary report. J Bone Joint Surg Am 75: 162-167.
27. Schnee CL, Ansell LV (1997) Selection criteria and outcome of operative approaches for thoracolumbar burst fractures with and without neurological deficit. J Neurosurg 86: 48-55.
28. Fournay DR, Abi-Said D, Lang FF, McCutcheon IE, Gokaslan ZL (2001) Use of pedicle screw fixation in the management of malignant spinal disease: experience in 100 consecutive procedures. J Neurosurg 94: 25-37.
29. Benli IT, Acaroglu E, Akalin S, Kis M, Duman E, et al. (2003) Anterior radical debridement and anterior instrumentation in tuberculosis spondylitis. Eur Spine J 12: 224-234.
30. Siegal T, Tiqva P, Siegal T (1985) Vertebral body resection for epidural compression by malignant tumors. Results of forty-seven consecutive operative procedures. J Bone Joint Surg Am 67: 375-382.
31. Hodgson AR, Stock FE (1960) Anterior spine fusion for the treatment of tuberculosis of the spine. The operative findings and results of treatment in the first one hundred cases. J Bone Joint Surg Am 42: 295-310.
32. Sasso RC, Best NM, Reily TM, McGuire RA (2005) Anterior only stabilization of three-column thoracolumbar injuries. J Spinal Disord Tech 18: S7-S14.
33. Masaki T, Sasao Y, Miura T (2009) An experimental study on initial fixation strength in transpedicular screwing augmented with calcium phosphate cement. Spine 34: E724-E728.