

Ankylosing Spondylitis in Association with Non-Hodgkin's Lymphoma: Successful Anti-TNF Alpha Treatment

Augusta Ortolan¹, Anna La Salvia², Mariagrazia Lorenzin¹, Paola Frallonardo¹, Dario Marino², Leonardo Punzi¹ and Roberta Ramonda^{1*}

¹Rheumatology Unit, Department of Medicine DIMED, University of Padova, Padova, Italy

²Department of Oncology, Istituto Oncologico Veneto (IOV), IRCCS, University of Padova, Padova, Italy

Abstract

Some rheumatic diseases, including ankylosing spondylitis, appear to be associated to an increased risk of cancer, in particular lymphoma. At the same time, a slightly higher risk of cancer has been associated to Tumour Necrosis Factor (TNF)-alpha antagonists, a widely used treatment for ankylosing spondylitis. A history of malignancy is generally considered a contraindication to TNF-alpha inhibitor and, if neoplasia is uncovered during treatment, therapy suspension is mandatory. Few data are available regarding the possibility of resuming treatment in the event of a flare up of this disease, even when exams monitoring the neoplastic disease are negative. Here we describe the case of a 56-year-old AS patient who developed a cutaneous B-cell non-Hodgkin lymphoma while undergoing treatment with a TNF-alpha inhibitor. The therapy was suspended while he was treated for the neoplasia, but it was resumed when there was a flare up of the disease, and the patient showed improvement.

Keywords: Ankylosing spondylitis; Spondyloarthritis; Non-Hodgkin lymphoma; Anti-TNF alpha; Infliximab; Cancer risk

Introduction

Autoimmune diseases are known to be associated with an increased risk of cancer and in particular of leukemia and lymphoma. Rheumatic autoimmune diseases are no exception and a higher risk of malignancy appears to be linked to the pathobiology of the rheumatic disease, including the inflammatory burden and immunological defects, personal and environmental factors (smoking, viral infections) and immunomodulatory therapies [1].

Spondyloarthritis (SpA) and in particular ankylosing spondylitis (AS) are rarely associated to lymphoma [2]. While the data of a nationwide Swedish case-control study did not find a higher risk of lymphoma in AS [3], other studies have [4].

Here we describe the case of 56-year-old AS patient who developed a B-cell non-Hodgkin lymphoma (NHL) while undergoing treatment with a TNF-alpha inhibitor, and then -after appropriate cancer treatment and regression of neoplasia- resumed treatment in occasion of a flare of AS, without recurrence of neoplasia. On the basis of our experience, the possibility of resuming treatment may be feasible when neoplasia is cured in a much selected group of patients.

Case Report

The patient had been suffering from inflammatory back pain since the age of 35; the diagnosis of AS was made according to the New York criteria [5]; the patient also showed typical marginal syndesmophytes forming an undulating contour of the spine ("bamboo spine", Figure 1). He has been attending the Rheumatology Unit Day Hospital of the University of Padova Medical Centre since 2002 when he began treatment with infliximab (5 mg/kg every 4 weeks) as the disease had proved to be resistant to non-steroidal antiinflammatory drugs (NSAIDs) and sulphasalazine (2 g/day). He benefited from the therapy for 9 years and all disease activity indexes fell dramatically (Table 1). Therefore, infliximab injection intervals were progressively prolonged to 8 weeks.

In February 2011, the patient was referred to the Oncology Unit when a rapidly growing red nodule in the left parasternal region became apparent. At biopsy the histological diagnosis was morphological and immunophenotypic features of follicular NHL (G1) positive for CD20 CD79 CD10, BCL2 and BCL6; Ki-67: 5-6%. When computed tomography (CT) of the head, thorax and abdomen was used to stage

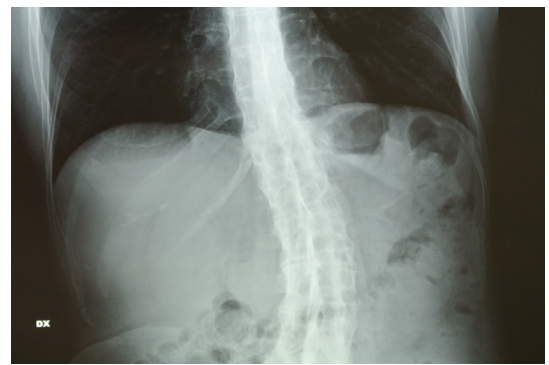


Figure 1: Typical marginal syndesmophytes forming an undulating contour of the spine ("bamboo spine").

the lymphoma, no other sites were uncovered. A bone marrow biopsy was negative. It has to be pointed out that the patient had no known risk factor for the development of lymphoma, such as positive family history or monoclonal gammopathy of undetermined significance (MGUS).

The patient underwent surgical excision of the lesion in April 2011. At that time infliximab was suspended in accordance with international guidelines [6]. Following surgery, the patient was treated for AS with NSAIDs and analgesics and showed a good clinical response for a long period (22 months).

Afterwards, the patient noted a nodular erythematous skin lesion near the scar of the original surgical excision, therefore in February 2013 a new biopsy was performed with a diagnosis of grade 2 (G2) T-cell-rich B-cell NHL follicular lymphoma. Immunophenotypic

***Corresponding author:** Roberta Ramonda MD PhD, Rheumatology Unit, Department of Medicine DIMED Via Giustiniani 2, 35128 Padova, Italy, Tel: +39049 8212199; Fax: +39049 8212191 E-mail: roberta.ramonda@unipd.it

Received December 03, 2015; **Accepted** December 19, 2015; **Published** December 21, 2015

Citation: Ortolan A, La Salvia A, Lorenzin M, Frallonardo P, Marino D, et al. (2015) DAnkylosing Spondylitis in Association with Non-Hodgkin's Lymphoma: Successful Anti-TNF Alpha Treatment. J Spine 4: 272.doi:10.4172/2165-7939.1000272

Copyright: © 2015 Ortolan A, et al. This is an open-access article distributed under the terms of the Creative Commons Attribution License, which permits unrestricted use, distribution, and reproduction in any medium, provided the original author and source are credited.

investigations showed positivity for CD20, CD10, BCL2 and BCL6. CT and bone marrow biopsy excluded cancer localization in other sites. A positron emission tomography (PET) performed in May 2013 revealed increased uptake of 18F-fluorodeoxyglucose in three rounded parasternal areas (Standardized uptake value equal to 6.45) (Figure 2). In view of the relapse, the patient was prescribed radiation treatment (40Gy/20F).

The patient, meanwhile, suffered a severe recrudescence of AS (Table 1), which had a major impact on his quality of life and did not respond to symptomatic therapy. A new PET-CT executed three months after radiotherapy treatment (September 2013) confirmed the nonappearance of the neoplastic disease. The use of TNF-alpha inhibitors was once again considered, according to patient's request. Following a consultation between rheumatologists, oncologists and forensic scientists, written approval by the local Ethical Committee was requested and granted. Informed about the risk of malignancy reactivation as opposed to the potential benefit that could be linked to therapy, the patient signed a written consent form and infliximab treatment was begun. The patient showed marked improvement (Table 1), although he continues to present some functional limitation due to the long-term course of disease activity. The patient continues to be evaluated by the oncologist and rheumatologist on a regular basis (every 6 months), without a relapse of B-cell lymphoma until now (2013-2015).

Discussion

Anti TNF-alpha drugs are widely used for rheumatoid arthritis (RA), SpA, psoriasis and inflammatory bowel diseases (IBD), but the

association between these drugs and the development of neoplastic diseases remains controversial. Studies which analyse this association are mainly focused on three of the anti TNF-alpha drugs: infliximab, adalimumab and etanercept, as they were the first to be produced, so their long-term effects have been properly explored. The standard dosage which anti TNF-alpha are used is the same, regardless the indication (RA, SpA, psoriasis or IBD) [7,8] : infliximab is administered at the dose of 3-5 mg/kg once every 4-8 weeks, adalimumab 40 mg fortnightly and etanercept 50 mg per week (in a single administration or splitted in two 25 mg doses); therefore it can be assumed that anti TNF-alpha exposure was comparable for patients considered in those studies about the relationship between anti TNF-alpha and cancer.

Various studies reached the conclusion that the overall risk of malignancy in patients treated with anti TNF-alpha is more or less equal than in general population. In particular, A meta-analysis examining TNF-alpha inhibitor treatments in RA, psoriatic arthritis (PsA) and AS patients [9] and a study based on 71 clinical trials examining the long-term (12 year) safety of TNF-alpha inhibitors (namely adalimumab) in RA, juvenile idiopathic arthritis, psoriatic arthritis "PsA" without parenthesis, AS, psoriasis and Crohn's disease did not find a higher risk of malignancy in the patients treated with TNF-alpha inhibitors [10]. Nevertheless, considering separately the various forms of malignancy, in this last work a higher incidence of non-melanoma skin cancer was noted in RA, PsA and Chron's disease patients [10].

A higher risk of malignancy in rheumatic and inflammatory diseases could also be linked to other factors, in particular the concomitant use of thiopurines or to the underlying inflammatory disease, rather than anti TNF alpha therapy. For example, IBD patients and in particular those treated with thiopurines have, in fact, shown an increased rate of non-melanoma skin cancer. Some authors have reported a higher risk in patients treated with TNF-alpha inhibitors in combination with thiopurines, but not in patients taking biological agents alone [11]. As for the underlying inflammatory condition facilitating the development of cancer, it is suggestive that some reports describe the onset of lymphoma after TNF-alpha inhibitor therapy not only in AS patients [12] but also in patients affected by other types of SpA [13] as well as in other inflammatory diseases [14].

Other wider studies, moreover, seem to support these findings: data from South Swedish Arthritis Treatment Group register (SSATG), reported that conventionally treated RA patients had an increased overall tumor risk compared to the TNF-treated population. The overall cancer incidence did not result increased in the TNF-treated RA patients compared with the control group. Of course this result should be interpreted with caution because of the limited number of patients studied and the relatively short follow-up period. Moreover, exclusion of patients with a known cancer history from TNF-alpha inhibitor treatment may have contributed to the lower incidence of

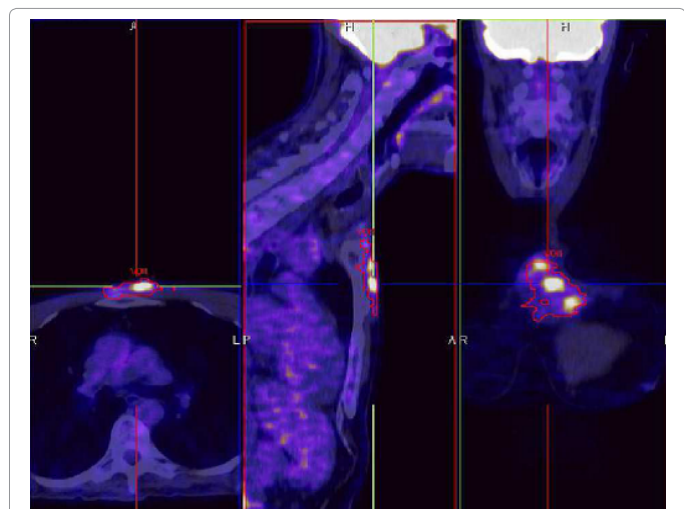


Figure 2: PET showing increased uptake of 18F-fluorodeoxyglucose in three rounded parasternal areas (Standardized uptake value equal to 6.45).

	Before anti TNF-alpha (2002)	After 9 years of anti TNF-alpha (2011)	Flare after 2 years without anti TNF-alpha (2013)	2 years after resuming anti TNF-alpha (2015)
BASDAI (0-10)	8.8	4.6	9.1	3.2
ASDAS	3.8	2.1	3.6	1.8
BASFI (0-10)	9.2	5.1	9.8	4.9
BASMI (0-10)	9	6	9	7
CRP (mg/L)	12.0	3.2	10.3	2.9

BASDAI: Bath Ankylosing Spondylitis Disease Activity Index; ASDAS: Ankylosing Spondylitis Disease Activity Score; BASFI: Bath Ankylosing Spondylitis Functional Index; BASMI: Ankylosing Spondylitis Metrology Index; CRP: C Reactive Protein

Table 1: Disease activity indexes (BASDAI, ASDAS), functional index (BASFI), metrology index (BASMI) and CRP at various time points.

cancer in that group [15]. In only one study from a French registry exposure to adalimumab or infliximab versus etanercept emerged as an independent risk factor for lymphoma in RA patients with an odds ratio=4.7 (1.3–17.7). As discussed by the same authors [16], it is clear that potentially anti-TNF alpha could both have positive and negative effects for the development of lymphoma because on one hand they decrease disease activity, consequently lymphoma risk associated to prolonged disease activity (which is the main risk factor according to literature), on the other hand, they may inhibit the activity of T-cells expressing TNF which can exert an immunomodulatory effect.

Generally data from observational studies, clinical trials, and meta-analyses have indicated that the risk to benefit profile of biologic treatment with respect to cancer risk appears quite favorable. Certainly meta-analysis of randomized controlled trials in this case appear poorly suited to fully address this risk, due to the short duration of exposure to these agents as well as the relatively limited statistical power to rule out associations which may be clinically important. A close follow-up is therefore necessarily recommended, especially in view of the fact that the onset of cancer is often insidious.

Besides all these consideration, a history of malignancy is generally considered a contraindication to TNF-alpha inhibitor treatment [6], but obviously patients may develop a neoplastic disease even during treatment [17]. In that case, suspension of TNF-alpha inhibitors is considered mandatory, but there are no clear guidelines concerning resuming treatment, even if TNF-alpha antagonists have become a crucial treatment option for patients affected with AS and their suspension could often entail a recrudescence of AS symptoms.

Our experience demonstrates that, in case of well defined, non-diffused neoplasia with negative follow up, resuming anti TNF-alpha therapy is safe and can be reconsidered in case of flare-up of the rheumatic disease with tight control of patients.

Since a slightly increased risk of malignancy cannot be excluded, the balance between possible benefits and risks must be exhaustively evaluated and a strict oncological follow-up is essential, especially in the event of long-term therapy.

Conflicts of Interest

None of the authors have any conflicts of interest to declare.

Acknowledgment

The authors wish to thank Linda Inverso (native language teacher) for her assistance in editing the English version.

References

1. Turesson C, Matteson EL (2013) Malignancy as a comorbidity in rheumatic diseases. *Rheumatology (Oxford)* 52: 5-14.
2. Kim YS, Kim HS (2012) Ankylosing spondylitis accompanying with Hodgkin's lymphoma. *Int J Rheum Dis* 15: e68-70.
3. Askling J, Klareskog L, Blomqvist P, Fored M, Feltelius N (2006) Risk for malignant lymphoma in ankylosing spondylitis: a nationwide Swedish case-control study. *Ann Rheum Dis* 65: 1184-1187.
4. Shibata A, Zhao S, Makuch R, Wentworth J, Veith J, et al. (2004) Lymphoma risk in ankylosing spondylitis patients is greater than that observed in the general population. *Ann Rheum Dis* 63: 98.
5. van der Linden S, Valkenburg HA, Cats A (1984) Evaluation of diagnostic criteria for ankylosing spondylitis. A proposal for modification of the New York criteria. *Arthritis Rheum* 27: 361-368.
6. Braun J, van den Berg R, Baraliakos X, Boehm H, Burgos-Vargas R, et al. (2011) 2010 update of the ASAS/EULAR recommendations for the management of ankylosing spondylitis. *Ann Rheum Dis* 70: 896-904.
7. Baraliakos X, Braun J (2010) Anti-TNF-alpha therapy with infliximab in spondyloarthritis. *Expert Rev Clin Immunol* 6: 9-19.
8. Rutgeerts P, Van Assche G, Vermeire S (2004) Optimizing anti-TNF treatment in inflammatory bowel disease. *Gastroenterology* 126: 1593-1610.
9. Mariette X, Matucci-Cerinic M, Pavelka K, Taylor P, van Vollenhoven R, et al. (2011) Malignancies associated with tumor necrosis factor inhibitors in registries and prospective observational studies: a systemic review and meta-analysis. *Ann Rheum Dis* 70: 1895-1904.
10. Burmester GR, Panaccione R, Gordon KB, McIlraith MJ, Lacerda AP (2013) Adalimumab long-term safety in 23 458 patients from global clinical trials in rheumatoid arthritis, juvenile idiopathic arthritis, ankylosing spondylitis, psoriatic arthritis, psoriasis and Crohn's disease. *Ann Rheum Dis* 72: 517-524.
11. Deepak P, Sifuentes H, Sherid M, Stobaugh D, Sadozai Y, et al. (2013) T-cell non-Hodgkin's lymphomas reported to the FDA AERS with tumor necrosis factor-alpha (TNF±) inhibitors: results of the REFURBISH study. *Am J Gastroenterol* 108: 99-105.
12. Xu L (2011) Ankylosing spondylitis combined with angioimmunoblastic T cell lymphoma. *BMJ Case Rep* 2011.
13. Bardazzi F, Antonucci VA, Alessandrini AM, Baraldi C, Tengattini V, et al. (2013) B-cell lymphoma in a psoriatic patient treated with infliximab. *Eur J Dermatol* 23: 264-265.
14. Targownik LE, Bernstein CN (2013) Infectious and malignant complications of TNF inhibitor therapy in IBD. *Am J Gastroenterol* 108: 1835-1842 quiz 1843.
15. Geborek P, Bladström A, Turesson C, Gulfe A, Petersson IF, et al (2005) Tumor necrosis factor blockers do not increase overall tumour risk in patients with rheumatoid arthritis, but may be associated with an increased risk of lymphomas. *Ann Rheum Dis* 64: 699-703.
16. Mariette X (2010) Lymphoma, rheumatoid arthritis, and TNFalpha antagonists. *Joint Bone Spine* 77: 195-197.
17. El Mansouri L, Couchouaron T, Le Roux G, Dugast C, Burtin F, et al. (2009) Breast cancer in a male with ankylosing spondylitis treated with TNFalpha antagonists. *Joint Bone Spine* 76: 421-423.