

# Anal Melanoma: A General Surgical Experience

Anthony McBrearty\*, Darren Porter and Kevin McCallion

Department of General Surgery, Ulster Hospital Dundonald, Belfast, Northern Ireland

**Keywords:** Anal melanoma; Cutaneous melanoma; Granular layer; Histological

## Introduction

Anal mucosal melanoma constitutes only 0.5 to 2% of all anorectal malignancies and less than 2% of all melanomas [1]. Anal melanoma is the third most common melanoma after the skin and ocular varieties and the most common site for primary gastrointestinal melanoma [2].

Lesions within 2-5 cm of the anus are anal melanomas whereas lesions beyond 5 cm from the anal verge are considered cutaneous melanomas. Cutaneous melanoma metastasizes to the gastrointestinal tract in only 2% of cases and, of these metastases, only 2% are to the rectum. Metastatic disease to the anus is extremely rare [3]. Median age at presentation of anal melanoma is fifty-five years. There may be a slight female predominance but individual series are too small to make definitive conclusions and most of the literature does not suggest significant gender differences [4]. There are no known risk factors. Clinical diagnosis is difficult and often inadvertent following treatment for presumed benign disease [5]. Most lesions appear to arise at or below the level of the dentate line. At least twenty-five per cent are amelanotic and anal melanomas are typically 3-4 cm in size [6,7].

Clark's level is a staging system which describes the level of anatomical invasion of the melanoma in the skin [8]. It is usually used in conjunction with Breslow's depth. Clark's level was the primary factor in earlier AJCC staging scheme for melanoma but has since been shown to have a lower predictive value, is less reproducible, and more operator-dependent than Breslow's depth [8]. Breslow's depth is measured from the granular layer of the epidermis to the deepest point of invasion and is most accurately measured by evaluating the entire tumour via an excisional biopsy. Thus, in the current (2010) AJCC staging system, Clark's level has prognostic significance only in patients with very thin (Breslow depth <1 mm) melanomas (Table 1) [9].

One study validated the importance of tumor depth (but not Breslow's original description) as one of the three most important prognostic factors in melanoma-the others being T stage and ulceration [2-4]. Depth has also been shown to predict the risk of lymph node metastasis, with deeper tumors being more likely to involve nodes [5]. In mucosal melanoma tumour thickness, presence of nodal disease, histological subtype and gender are all unreliable predictors of outcome. The most recent AJCC guidelines use cut-offs of 1 mm, 2 mm, and 4 mm to predict prognosis (Table 2) [9]. of note, most anal melanomas are greater than 4mm thickness at presentation [7].

Symptoms are best evaluated with direct visualisation and biopsy. Most patients are radiologically staged with CT, MRI and PET. Endoanal ultrasound may be undertaken by some centres to evaluate tumour depth. PET is effective in the assessment of cutaneous melanoma with sensitivities quoted as seventy-four to one hundred per cent and

Level 1	Melanoma confined to the epidermis (melanoma in situ)
Level 2	Invasion into the papillary dermis
Level 3	Invasion to the junction of the papillary and reticular dermis
Level 4	Invasion into the reticular dermis
Level 5	Invasion into the subcutaneous fat

**Table 1:** Clark's anatomical levels.

Tumour Depth	Approximate 5 year survival
<1 mm	95-100%
1-2 mm	80-96%
2.1-4 mm	60-75%
>4 mm	50%

**Table 2:** Table showing 5-year survival against depth of tumour according to AJCC guidelines (2009) [9].

specificity sixty-seven to one hundred per cent [10].

Surgery remains the cornerstone of management with options being WLE or APR. Chemotherapy, radiotherapy and immune therapy have a limited role. Prognosis is poor with median survival less than two years [11].

## Methods

We reviewed the clinical notes of patients with anorectal melanoma referred to the colorectal unit at the Ulster Hospital between 2010 and 2013. In total, there were five patients; two male and three female; age range 51-85 years. Clinical presentation, diagnostic workup, surgical management and follow-up were reviewed to include multidisciplinary team discussion. A literature review was performed via the 'PubMed' database using the search term 'anal melanoma'. Only articles in the English language were included. A total of four hundred and sixty-six articles were identified. Abstracts were reviewed to include articles discussing epidemiology, diagnosis, staging and management of anorectal melanoma. A further 'advanced search' using 'PubMed' was performed for articles with 'anal melanoma' in the title and abstract. A total of thirty-seven articles were obtained. Only relevant articles (total 30) were included. Six case reports and a report of canine melanoma were excluded. A further eight articles were identified by searching individual journal archives and these were also included (Figure 1).

## Case 1

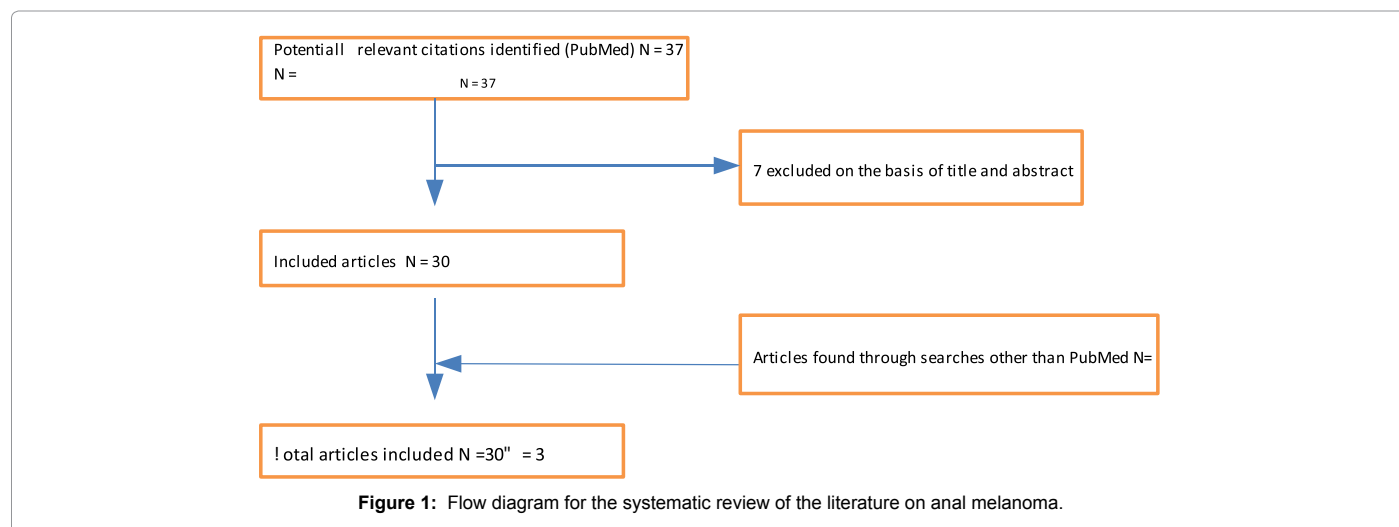
A seventy-four year old lady was referred with Per Rectal (PR) bleeding. Proctoscopy revealed a suspicious lesion at the anal verge. An Examination Under Anaesthesia (EUA) of ano-rectum was performed and the lesion biopsied. Histology confirmed malignant melanoma at the anal verge. Staging computerised tomography scan of the chest, abdomen and pelvis (CT CAP) showed no metastatic disease. A WLE was performed and histology revealed a PT4b anal melanoma with a Clark level of five and Breslow thickness of 1.2 mm. Following discussion at the Colorectal MDT, dermatology MDT and with the Plastic Surgery Group, it was agreed that the patient be followed-up surgically. Repeat

\*Corresponding author: Anthony McBrearty, Department of Surgery, Craigavon Area Hospital, Northern Ireland, Tel: 07883211590; E-mail: [anthonymcbrarty@doctors.org.uk](mailto:anthonymcbrarty@doctors.org.uk)

Received January 18, 2015; Accepted February 20, 2015; Published February 22, 2015

**Citation:** McBrearty A, Porter D, McCallion K (2015) Anal Melanoma: A General Surgical Experience. J Clin Case Rep 5: 493. doi:10.4172/2165-7920.1000493

**Copyright:** © 2015 McBrearty A, et al. This is an open-access article distributed under the terms of the Creative Commons Attribution License, which permits unrestricted use, distribution, and reproduction in any medium, provided the original author and source are credited.



Computerised Tomography Positron Emission Tomography (CT PET) was performed at six months and revealed no metabolically active disease. Nine months post-WLE, the patient re-presented and underwent excision of two further anal nodules. Histology confirmed recurrent malignant melanoma. A follow-up CT CAP at this time demonstrated lung and liver lesions suspicious for metastatic disease. The patient declined chemotherapy. Thirteen months post-WLE, the patient re-presented with PR bleeding and underwent excision of four further nodules confirmed histologically as recurrent disease. Repeat CT CAP demonstrated progression of the liver and lung disease with a new lesion in the left groin suspicious for metastasis. Following discussion, the patient declined further intervention and was referred for palliative care. The patient died of metastatic malignant melanoma sixteen months after diagnosis.

## Case 2

A fifty-one year old lady was referred with altered bowel habit and PR bleeding. A colonoscopy was performed and a tumour discovered at the anorectal junction. Biopsies confirmed malignant anal melanoma. A CT CAP demonstrated no metastatic disease. Following Colorectal MDT discussion, the patient proceeded to a laparoscopic APR on 20/06/11. Histopathology confirmed a malignant anal melanoma with a Breslow thickness of 2.5 mm, metastatic satellite lesions and regional nodal disease. CT PET revealed no active disease. MRI pelvis was also unremarkable. The patient re-presented with jaundice and acute liver derangement four months later. CT CAP revealed no obvious metastatic disease. A liver biopsy was performed which revealed tumour infiltration. Following MDT discussion, the patient received chemotherapy with decarbazine and ipilimumab. Follow-up CT CAP and MRI fourteen months post-APR on 8/8/12 demonstrated multiple hypodense liver lesions. Due to the deterioration in liver function, the patient was deemed unsuitable for Interferon therapy. She was referred for palliation and died twenty months after diagnosis.

## Case 3

A fifty-six year old gentleman was referred with a painful anal swelling. EUA and biopsy confirmed anal melanoma in-situ. A staging CT CAP showed no metastatic disease. The patient proceeded to WLE following Colorectal MDT discussion. Histology confirmed malignant melanoma with satellite lesions and lymphovascular invasion, Clark level 5 and Breslow thickness of 3.5 mm. The patient re-presented with

inguinal lymphadenopathy two months later and CT PET demonstrated a metabolically active right inguinal node. After further Colorectal MDT discussion, the patient underwent a laparoscopic APR on 13/9/11 with right groin dissection and gluteal flap reconstruction. Nine months later the patient presented with two further subcutaneous nodules in the right groin which were confirmed as recurrent disease. A repeat CT PET demonstrated increased uptake in the right groin, left calf and in the left trapezius. The patient proceeded to palliative chemotherapy after MDT discussion. A follow-up CT CAP revealed metastatic disease in the left adrenal gland and an indeterminate cerebral lesion. Further follow-up imaging demonstrated progression of the adrenal disease, multiple small bowel lesions suspicious for serosal metastases, enlarged mesenteric nodes and cerebral metastases. The patient was referred for palliative care and died sixteen months after diagnosis.

## Case 4

An eighty-five year old gentleman was referred for investigation of PR bleeding and iron deficiency anaemia. Oesophago-Gastro-Duodenoscopy (OGD) was normal and colonoscopy demonstrated a single pedunculated polyp at the anal verge. Examination Under Anaesthetic (EUA) of ano-rectum with transanal excision of the polyp was performed and histology confirmed malignant melanoma. A follow-up CT PET demonstrated increased uptake at the left lung hilum suspicious for primary lung carcinoma. A further nodule in the right pre-sacral fat was thought to represent metastatic disease from the anal melanoma. There was also increased uptake in the sigmoid colon. A CT CAP demonstrated progressive infiltrating disease in the left lung parenchyma, metastasis in the right pre-sacral space and ileal changes suspicious for small bowel involvement. The patient was referred to the respiratory team. Follow-up CT showed static appearances of the lung lesion. Bronchial washings confirmed squamous cell carcinoma of the lung. The patient continued on the lung cancer pathway. A repeat CT PET demonstrated increased anal activity, increased uptake adjacent to the prostate, focal uptake left hilum and left hilar nodal disease. Repeat EUA of ano-rectum revealed no evidence of local recurrence but confirmed palpable extra-rectal disease in the right mesorectum consistent with the CT findings. A sigmoidoscopy was performed for further rectal bleeding thirteen months after the initial polypectomy. Two further polyps were completely excised from the anorectum and confirmed histologically as recurrent malignant melanoma. The patient remained under review eighteen months after diagnosis.

## Case 5

A 62 year old female was referred with PR bleeding. Clinical examination revealed a 3 cm polypoid lesion protruding from the anal verge. CT colonography was unremarkable. EUA of ano-rectum and excision of the lesion was performed and histology confirmed malignant melanoma with involved margins. CT PET revealed increased uptake in the left groin and right anterior thigh suspicious for metastatic disease. An ultrasound-Guided Fine Needle Aspiration (FNA) confirmed a metastatic melanoma in the left inguinal node. WLE of the anal scar and left groin dissection was performed. Follow-up CT PET confirmed right inguinal lymphadenopathy and lung nodules suspicious for metastatic disease. Repeat FNA of the right groin confirmed metastatic disease and the patient proceeded to a right groin dissection. A further follow-up CT PET revealed bilateral pulmonary disease, bilateral pelvic and inguinal node disease and anal activity representing recurrence. Repeat WLE of the anal lesion was performed and histology confirmed recurrent anal melanoma. CT PET confirmed progression in lung metastases and extensive pelvic lymphadenopathy. The patient was deemed not fit for chemotherapy following MDT discussion and remained under surgical review fourteen months after diagnosis.

## Discussion

Patients with anorectal melanoma can present with a variety of symptoms such as PR bleeding, anal pain, pruritus, tenesmus, altered bowel habit or an anorectal mass. If metastatic disease is present, they may present with systemic symptoms such as weight loss, anaemia and fatigue or with palpable inguinal lymphadenopathy, pelvic masses or even bowel obstruction [11].

Patients with anal melanoma often present late and effectively suffer a delayed diagnosis with symptoms often reported four to six months prior to presentation. One third of patients have locally advanced or disseminated disease at the time of presentation. Twenty per cent will have regional nodal disease. The most common site for metastases is lung (>50%), followed by liver, brain and gastrointestinal tract [7,12]. Anal melanomas are commonly misdiagnosed as those of other benign anorectal conditions such as haemorrhoids, skin tags or polyps [13]. A timely diagnosis of anal melanoma is made even more difficult by the fact that up to 80% of lesions lack obvious pigmentation and up to 20% of tumours are histologically amelanotic [7,14].

Anal melanoma can be present at the anorectal junction, within the anal canal or at the anal verge (ano-cutaneous junction). Traditionally, abdomino-perineal resection (APR) has been recommended for the management of anorectal melanoma. More recent studies have indicated that wide local excision of the primary melanoma with sphincter preservation is an option for many patients [15-24].

Most studies show a higher rate of local control for patients undergoing APR, but typically without any survival benefit when compared to WLE. A more recent study demonstrated very similar rates of local control and overall survival for APR and WLE from 1984-2003. For melanomas at the anorectal junction, WLE is unlikely to be possible and such lesions are likely to require an APR if surgery is indicated. This may also apply to lesions within the anal canal itself whereas lesions at the anal verge are more amenable to WLE.

About one third of patients with localised disease will require an abdominoperineal excision for complete resection of the melanoma. Guidance regarding width of margins for either APR or WLE has not been reported although some authors suggest 2cm for WLE. Width of excision is rarely reported in the literature [25]. The advantages of APR

are its ability to control lymphatic spread and to create wider excision margins resulting in a lower local recurrence rate. APR is associated with considerable post-operative morbidity (4% haemorrhage, 11-16% wound infection and 14-24% wound dehiscence), mortality and the need for a permanent stoma [26]. In some patients, APR may not be appropriate. WLE offers patients seemingly equivalent symptom control and the opportunity for cure with significantly less morbidity and avoidance of a permanent colostomy. There is a higher rate of local recurrence associated with WLE which, in turn, can be treated with further excision.

It is recommended that patients with nodal disease at presentation undergo lymphadenectomy at the time of the definitive procedure for achievement of local control [7]. Inguinal nodes are the commonest site of regional node failure. Survival does not appear strongly associated with regional node metastases, given the likelihood of existing distant metastases. Sentinel node biopsy is not routinely performed due to the lack of association between node status and survival but has been documented in a limited number of patients. There is no documented benefit of elective lymphadenectomy. Lymphadenectomy is indicated at the time of the definitive procedure for primary anorectal melanoma with proven regional lymph node involvement [7]. A recent series of 23 patients treated by wide excision and postoperative radiotherapy (30 Gy in five fractions over 2.5 weeks to the primary tumour and draining lymphatic sites) achieved local control rate of 74%, and a five-year survival of 31% after a median follow-up of 37 months [29]. Local control in this report was similar to patients undergoing APR [30].

The role of chemotherapy for melanoma remains unclear. Dacarbazine is the most commonly studied agent, but response rates are only about 20% [29]. Combination chemotherapy has shown poor results [20,29]. Radiotherapy has been used as part of the management of anorectal melanoma but its utility is unknown [30]. It may be considered for loco-regional control after WLE or as palliation in setting of local, regional or distant recurrence. This has been suggested in melanoma of the head and neck [30].

Interferon alpha has anti-tumour effects related to a combination of direct activities and indirect immune-mediated effects. Side effects occur in up to 10% of patients and include neutropenia, anaemia and thrombocytopenia. There may be some benefit in the treatment of cutaneous melanoma but there is currently insufficient evidence to draw any conclusions [32].

Progress in understanding melanoma biology and immune regulation have enabled use of targeted agents such as selective mitogen-activated protein (MAP) kinase inhibitors (BRAF and MEK inhibitors) and immune checkpoint blockade with CTLA4 antibodies [33]. Although appearing superior to chemotherapy, efficacy has been limited by resistance and toxicity. The use of combination therapies with BRAF and MEK inhibitors with other immune blocking agents such as PD-1 and PD-L1 have demonstrated less toxic effects and further delayed tumour resistance. Further trials involving combined targeted therapies are aimed at improving the rate of progression-free survival, particularly in metastatic disease [34,35].

Five-year survival for all patients with anal melanoma is only 3-22% [36]. Patients with disease confined to the anal canal have a five-year survival of approximately 35% and a median survival of approximately 30 months. Patients with regional disease at presentation have a median survival of 20 months, and patients with metastatic disease at presentation rarely survive 12 months [7]. There are no reported cases of long-term survivors if metastatic disease, including inguinal lymph

node metastases, is present at diagnosis. A case review series of 36 patients treated since 1950 demonstrated that patients without nodal disease survived longer [36]. The review also showed that patients with tumour thickness less than 2mm survived more than five years, those with tumour thickness 2-3mm had a median survival of thirty-three months, and patients with tumours larger than 3mm survived only eight months [36].

## Conclusion

Anorectal melanoma represents both a diagnostic and therapeutic challenge given its non-specific presentation and rarity. A significant number of patients will have disseminated disease at presentation. Although consistent, there is limited data to support recommendations on specific surgical therapy. Much of the literature to date is based on small retrospective cohort studies with multiple confounding factors. For tumours with poor prognostic factors or in less fit patients, WLE is potentially the most appropriate option to achieve local control as well as sparing the risk associated with APR and a permanent colostomy. The efficacy of adjuvant treatments is also limited to small studies. It is unlikely that there will ever be a large cohort from which significant conclusions about management of anorectal melanoma can be drawn. More recent research regarding targeted immunotherapy, however, is promising. Nonetheless, despite mode of treatment, prognosis remains poor. Education of patients and clinicians alike may assist in earlier presentation and diagnosis. However, it is essential that any suspicious or non-healing lesion is biopsied early and once a diagnosis of anorectal melanoma is made, urgent referral to an appropriate team with a specialist interest should follow.

## References

1. Roumen RM (1996) Anorectal melanoma in The Netherlands: a report of 63 patients. *Eur J Surg Oncol* 22: 598-601.
2. Chang AE, Karnell LH, Menck HR (1998) The National Cancer Data Base report on cutaneous and noncutaneous melanoma: a summary of 84,836 cases from the past decade. The American College of Surgeons Commission on Cancer and the American Cancer Society. *Cancer* 83: 1664-1678.
3. Ollila DW, Essner R, Wanek LA, Morton DL (1996) Surgical resection for melanoma metastatic to the gastrointestinal tract. *Arch Surg* 131: 975-979.
4. Weinstock MA (1993) Epidemiology and prognosis of anorectal melanoma. *Gastroenterology* 104: 174-178.
5. Pessaux P, Pocard M, Elias D, Duvillard P, Avril MF, et al. (2004) Surgical management of primary anorectal melanoma. *Br J Surg* 91: 1183-1187.
6. Bullard KM, Tuttle TM, Rothenberger DA, Madoff RD, Baxter NN, et al. (2003) Surgical therapy for anorectal melanoma. *J Am Coll Surg* 196: 206-211.
7. (2008) Clinical practice guidelines for the management of melanoma in Australia and New Zealand Australian Cancer Network.
8. Balch CM, Soong SJ, Gershenwald JE, Thompson JF, Reintgen DS, et al. (2001) Prognostic factors analysis of 17,600 melanoma patients: validation of the American Joint Committee on Cancer melanoma staging system. *J Clin Oncol* 19: 3622-3634.
9. Balch CM, Gershenwald JE, Soong SJ, Thompson JF, Atkins MB, et al. (2009) Final version of 2009 AJCC melanoma staging and classification. *J Clin Oncol* 27: 6199-6206.
10. Singer M, Mutch MG (2006) Anal melanoma. *Clin Colon Rectal Surg* 19: 78-87.
11. Brady MS, Kavolius JP, Quan SH (1995) Anorectal melanoma. A 64-year experience at Memorial Sloan-Kettering Cancer Center. *Dis Colon Rectum* 38: 146-151.
12. Cooper PH, Mills SE, Allen MS Jr (1982) Malignant melanoma of the anus: report of 12 patients and analysis of 255 additional cases. *Dis Colon Rectum* 25: 693-703.
13. Felz MW, Winburn GB, Kallab AM, Lee JR (2001) Anal melanoma: an aggressive malignancy masquerading as hemorrhoids. *South Med J* 94: 880-885.
14. Morson BC, Volkstädt H (1963) Malignant melanoma of the anal canal. *J Clin Pathol* 16: 126-132.
15. Goldman S, Glimelius B, Pählman L (1990) Anorectal malignant melanoma in Sweden. Report of 49 patients. *Dis Colon Rectum* 33: 874-877.
16. Slingluff CL Jr, Vollmer RT, Seigler HF (1990) Anorectal melanoma: clinical characteristics and results of surgical management in twenty-four patients. *Surgery* 107: 1-9.
17. Ross M, Pezzi C, Pezzi T, Meurer D, Hickey R, et al. (1990) Patterns of failure in anorectal melanoma. A guide to surgical therapy. *Arch Surg* 125: 313-316.
18. Antoniuk PM, Tjandra JJ, Webb BW, Petras RE, Milsom JW, et al. (1993) Anorectal malignant melanoma has a poor prognosis. *Int J Colorectal Dis* 8: 81-86.
19. Konstadoulakis MM, Ricaniadis N, Walsh D, Karakousis CP (1995) Malignant melanoma of the anorectal region. *J Surg Oncol* 58: 118-120.
20. Thibault C, Sagar P, Nivatvongs S, Ilstrup DM, Wolff BG (1997) Anorectal melanoma—an incurable disease? *Dis Colon Rectum* 40: 661-668.
21. Moozar KL, Wong CS, Couture J (2003) Anorectal malignant melanoma: treatment with surgery or radiation therapy, or both. *Can J Surg* 46: 345-349.
22. Weyandt GH, Eggert AO, Houf M, Raulf F, Bröcker EB, et al. (2003) Anorectal melanoma: surgical management guidelines according to tumour thickness. *Br J Cancer* 89: 2019-2022.
23. Malik A, Hull TL, Floruta C (2004) What is the best surgical treatment for anorectal melanoma? *Int J Colorectal Dis* 19: 121-123.
24. Yeh JJ, Shia J, Hwu WJ, Busam KJ, Paty PB, et al. (2006) The role of abdominoperineal resection as surgical therapy for anorectal melanoma. *Ann Surg* 244: 1012-1017.
25. Ward MW, Romano G, Nicholls RJ (1986) The surgical treatment of anorectal malignant melanoma. *Br J Surg* 73: 68-69.
26. Petrelli NJ, Nagel S, Rodriguez-Bigas M, Piedmonte M, Herrera L (1993) Morbidity and mortality following abdominoperineal resection for rectal adenocarcinoma. *Am Surg* 59: 400-404.
27. Ballo MT, Gershenwald JE, Zagars GK, Lee JE, Mansfield PF, et al. (2002) Sphincter-sparing local excision and adjuvant radiation for anal-rectal melanoma. *J Clin Oncol* 20: 4555-4558.
28. Drosch JT, Flum DR, Mann GN (2005) Wide local excision or abdominoperineal resection as the initial treatment for anorectal melanoma? *Am J Surg* 189: 446-449.
29. Hill GJ, Kremenz ET, Hill HZ (1984) Dimethyl triazeno, imidazole, carboxamide and combination therapy for melanoma. IV. Late results after complete response to chemotherapy (Central Oncology Group Protocols 7120, 7131 and 7131A). *Cancer* 53: 1299-1305.
30. Bujko K, Nowacki MP, Liszka-Dalecki P (1998) Radiation therapy for anorectal melanoma—a report of three cases. *Acta Oncol* 37: 497-499.
31. Temam S, Mamelie G, Marandas P, Wibault P, Avril MF, et al. (2005) Postoperative radiotherapy for primary mucosal melanoma of the head and neck. *Cancer* 103: 313-319.
32. Lens MB, Dawes M (2002) Interferon alfa therapy for malignant melanoma: a systematic review of randomized controlled trials. *J Clin Oncol* 20: 1818-1825.
33. Menzies AM, Long GV (2013) Recent advances in melanoma systemic therapy. BRAF inhibitors, CTLA4 antibodies and beyond. *Eur J Cancer* 49: 3229-3241.
34. Long GV, Stroyakovskiy D, Gogas H, Levchenko E, de Braud F, et al. (2014) Combined BRAF and MEK inhibition versus BRAF inhibition alone in melanoma. *N Engl J Med* 371: 1877-1888.
35. Snyder A, Makarov V, Merghoub T, Yuan J, Zaretsky JM, et al. (2014) Genetic basis for clinical response to CTLA-4 blockade in melanoma. *N Engl J Med* 371: 2189-2199.
36. Wanebo HJ, Woodruff JM, Farr GH, Quan SH (1981) Anorectal melanoma. *Cancer* 47: 1891-1900.