

An Unusual Pleural Location of Thymoma Mimicking Malignant Mesothelioma: A Case Report and Literature Review

El Haouari A¹, Tahiri L², Moumna K², Remmilink M¹ and Salmon I¹

¹Department of Pathology, Hopital Erasme, Bruxelles, Belgium

²Department of Pathology, Hassan li Teaching Hospital, Fez, Morocco

Abstract

Primary pleural thymomas are rare tumors often mistaken for malignant mesothelioma clinically and radiologically.

The present study reports the case of a 39-year-old woman presented with a pleural tumor in the right thorax. The tumor was surgically resected and histopathologically diagnosed as ectopic primary pleural thymoma lacking any evidence of a mediastinal tumor. The clinicopathological futures of this unusual thymoma are also discussed.

Keywords: Thymoma; Pleura; Pleural thymoma

Introduction

The usual location of thymoma is anterosuperior mediastinum, but its occurrence can be seen in extramediastinal regions such as the neck [1], within the thyroid [2], pulmonary parenchyma [3,4], and in the pleura [4-8].

Primary pleural thymomas are rare tumors with less than 30 cases reported to date [9-14]. It is often mistaken as malignant mesothelioma clinically and radiologically.

The present case of ectopic pleural thymoma lacks any evidence of a mediastinal tumor.

Case Report

A 39-year-old woman was hospitalized with the complaint of continuous chest pain for 2 months. She had a history of right pulmonary tuberculosis. There was no known history of smoking or occupational exposure to asbestos or other chemicals. There were no signs associated with myasthenia gravis.

Chest X-ray showed homogenous opacity on the right side, obscuring the upper and middle zones of the right lung. Chest CT (Figure 1) showed a pulmonary mass of medium density was centered on the small scissure of the upper lobe and right middle lobe, with regular contours, 46 mm in diameter. There was no pleural effusion, pulmonary hilar or mediastinal lymph node swelling, or mediastinal tumor, particularly in the anterosuperior regions. Pet scan (Figure 1): Presence of hypermetabolic sides making suspect malignancy. Diagnosis of NSCLC to exclude.

The patient underwent thoracotomy.

Macroscopically

The tumor, which was housed in the parietal pleura mainly at the fourth and fifth costal levels, although encapsulated, measured 5 × 3.5 cm. A cut, there is a whitish homogeneous appearance, with mild hemorrhagic and necrotic changes were observed on the surface of the tumor.

Microscopically

Well encapsulated tumor proliferation arranged in layers diffuse, made of spindle cells with oval, mildly pleomorphic nuclei intimately admixed with a mild infiltrate of lymphoid cells scattered throughout the tumor. Perivascular spaces characteristic of thymoma were found, although they were scarce. A few scattered mitoses of the epithelial cells were observed (Figures 2-6).

Immunohistochemical analyses showed that almost all of the epithelial cells stained positive for CK AE1/AE3 (Figure 5), and vimentine (Figure 3), and were negative for Calretinin, WT1 (Figure 6) (eliminating mesothelioma), CD34 (eliminating solitary fibrous tumor) and TTF1 (eliminating NSCLC). The lymphoid cells were positive for CD20 (Figure 4) and were negative for CD3, TDT, CD1a, and CD99.

These histopathological observations were almost completely compatible with those of thymoma rather than mesothelioma, and thus the tumor was diagnosed as being a medullary thymoma type A CK+, CD20+) (Figures 7 and 8).

The postoperative course was uneventful. The patient is free from the disease for the 10 months after surgery. Since no lesions in the mediastinum or other sites in the pleura were seen clinically in the CT scan, the tumor was conclusively judged to be ectopic primary pleural thymoma.

Discussion

Primary pleural thymomas are rare tumors thought to originate from ectopic thymic rests. There has been a case report on primary pleural thymoma in which ectopic rests of involuted thymic tissue were noted within the parietal pleural tissue [10]. Giving credence to this theory, several cases of pleural thymoma have also been reported so far [5-8] but some have shown more advanced tumors with mediastinal involvement, [5-6,7,15]. It remains questionable as to whether or not the origin of such tumors was actually the pleura itself.

Thymoma, particularly invasive thymoma spreads frequently to the intrathoracic pleura, as the disseminated lesions are generally regarded as metastases [5-7,15]. In contrast, our case showed that the lesion is developed in the the small scissure, far from the mediastinum, and no other tumor was evident either at the mediastinal or at the surrounding regions.

*Corresponding author: Aziza El Haouari, Department of Pathology, Hassan li Teaching Hospital, Fez, Morocco, Tel: +212 72400059; E-mail: nawalaziza@hotmail.fr

Received February 25, 2015; Accepted December 29, 2015; Published December 31, 2015

Citation: El Haouari A, Tahiri L, Moumna K, Remmilink M, Salmon I (2015) An Unusual Pleural Location of Thymoma Mimicking Malignant Mesothelioma: A Case Report and Literature Review. J Pulm Respir Med 5: 311. doi:10.4172/2161-105X.1000311

Copyright: © 2015 El Haouari A, et al. This is an open-access article distributed under the terms of the Creative Commons Attribution License, which permits unrestricted use, distribution, and reproduction in any medium, provided the original author and source are credited.

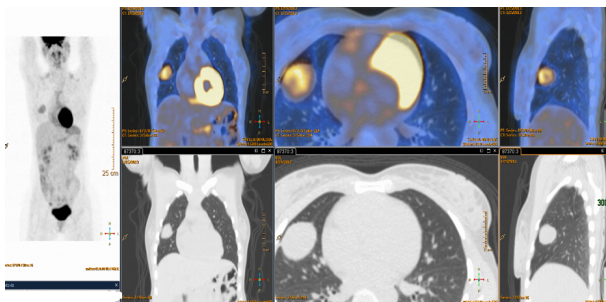


Figure 1: Chest CT showed a pulmonary mass centered on the small scissure of the upper lobe and right middle lobe, of medium density, with regular contours, 46 mm in diameter. Pet scan: Presence of hypermetabolic sides making suspect malignancy.

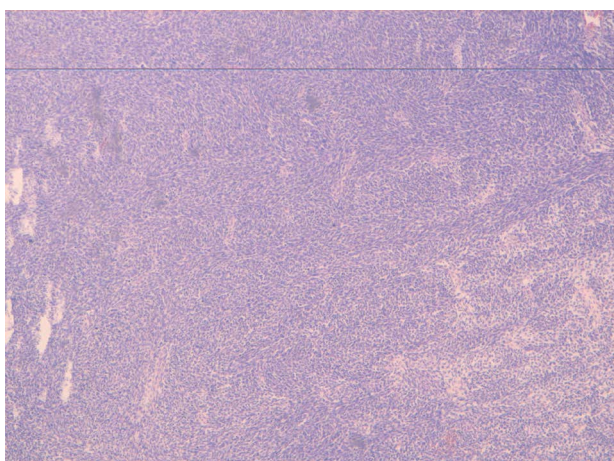


Figure 2: HES x 5. Tumor proliferation arranged in layers diffuse made of spindle cells with oval, mildly pleomorphic nuclei intimately admixed with a mild infiltrate of lymphoid cells scattered throughout the tumor. Perivascular spaces characteristic of thymoma were found, although they were scarce. A few scattered mitoses of the epithelial cells were observed

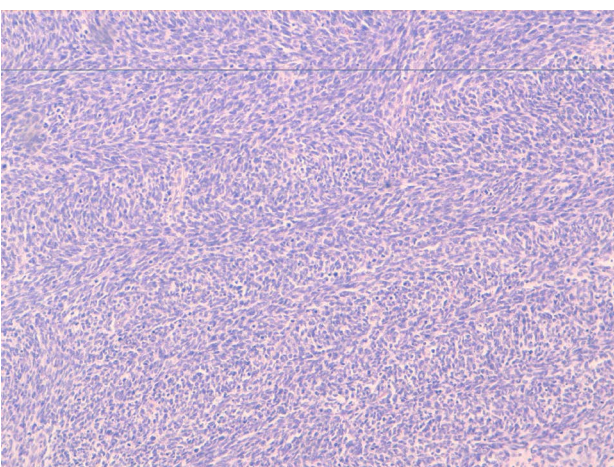


Figure 3: HES x 10. Tumor proliferation arranged in layers diffuse made of spindle cells with oval, mildly pleomorphic nuclei intimately admixed with a mild infiltrate of lymphoid cells scattered throughout the tumor. Perivascular spaces characteristic of thymoma were found, although they were scarce. A few scattered mitoses of the epithelial cells were observed.

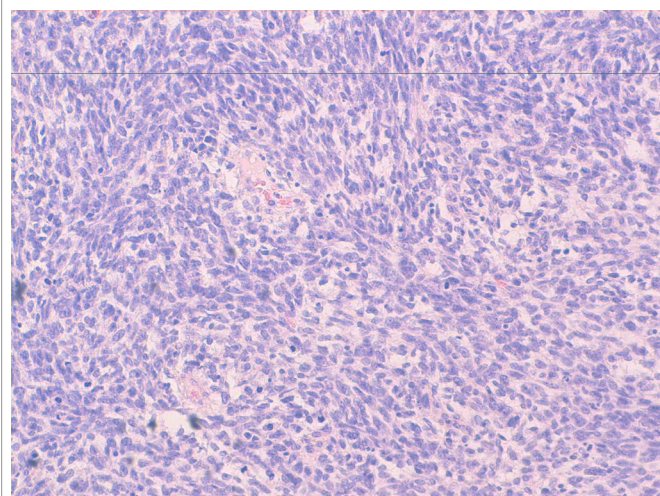


Figure 4: HES x 20. Tumor proliferation arranged in layers diffuse made of spindle cells with oval, mildly pleomorphic nuclei intimately admixed with a mild infiltrate of lymphoid cells scattered throughout the tumor. Perivascular spaces characteristic of thymoma were found, although they were scarce. A few scattered mitoses of the epithelial cells were observed.

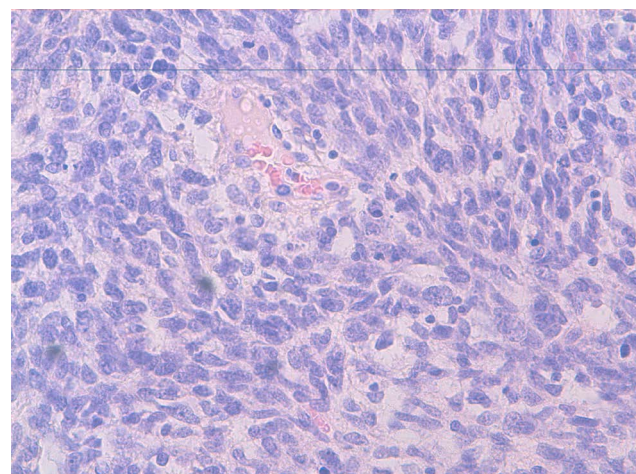


Figure 5: HES x 40. Tumor proliferation arranged in layers diffuse made of spindle cells with oval, mildly pleomorphic nuclei intimately admixed with a mild infiltrate of lymphoid cells scattered throughout the tumor. Perivascular spaces characteristic of thymoma were found, although they were scarce. A few scattered mitoses of the epithelial cells were observed.

Pleural thymomas can be presented as multiple pleural nodules or as a diffusion of thickening of the pleura encasing the lung, mimicking a mesothelioma. All the cases reported so far presented either a multiple pleural nodules or localized pleural masses with diffusion of pleural thickening encasing the lung as in our case.

Most of the patients had dyspnea, chest pain, weight loss, and pleural effusion. Primary pleural thymoma has been reported both in men and in women, aged 19 to 75 [9], with a slight male predominance.

WHO reports A, B1, and B2 Type with the characteristic histological features such as lobulations, minimal nuclear pleomorphism, staghorn vasculature, and perivascular spaces with lymphocytes for the biopsy samples. The closest differential diagnosis is malignant mesothelioma [9,12].

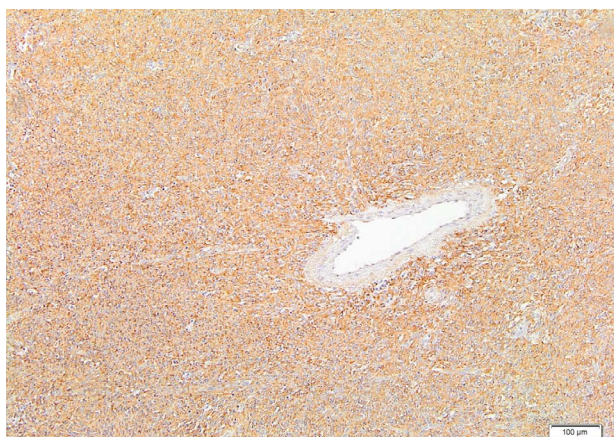


Figure 6: Almost all of the epithelial cells stained positive for vimentine.

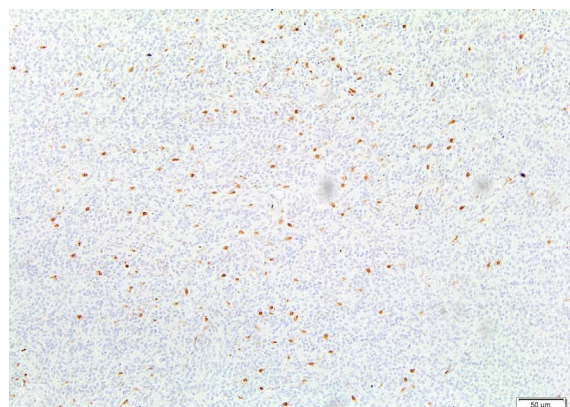


Figure 9: Epithelial cells were negative for calretinin.

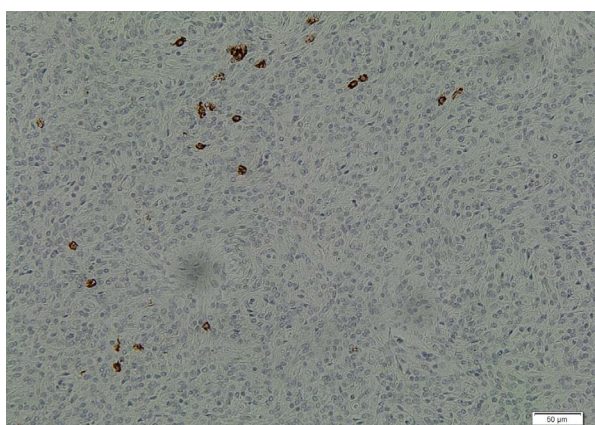


Figure 7: The lymphoid cells were positive for CD20.

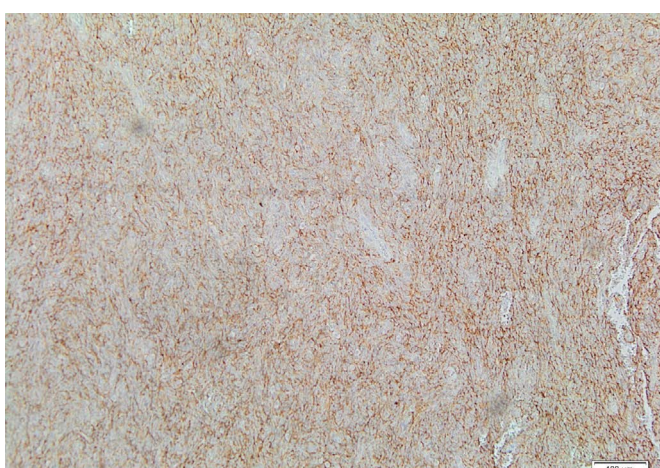

Figure 8: Almost all of the epithelial cells stained positive of Pan CK.

Thymoma type B2 mimics epithelial mesothelioma and B1 mimics the lymphohistiocytoid, which is a variant of malignant mesothelioma. Type A thymoma may mimic solitary fibrous tumor or monophasic synovial tumor when located in the pleura [9].

Immunohistochemical markers are useful aid in differentiating malignant mesothelioma. However, it should be interpreted with caution.

CK, clearly mark thymomas but do not allow us to reliably differentiate cortical and medullary epithelial cells. The cortical cells are immature, they are CD1 A+ TDT+, CD99+ CD3+, CD4+, CD8+. Medullary cells are mature CD1A, TDT negative, CD3+, CD4+, CD8+. The CD 20 has been described positive in the medullary forms (A).

In the present case, the epithelial cells were negative for calretinin (Figure 9) but were found stains of stromale, nerve and mast cells. Other mesothelial markers were negative (WT1). The diagnosis of solitary fibrous tumor was also suspected of CD34 and immunostaining was negative, eliminating this hypothesis. The lymphoid cells were positive for CD20, consistent with thymic origin. The tumor was assigned to the WHO medullary thymoma type A based on the morphology.

Moran et al. [4] describes Intrapulmonary thymoma as slow-growing neoplasm with a good prognosis when surgically resected. However, in cases with cytologic atypia or an invasive growth pattern, adjuvant therapy should be considered to prevent the possibility of recurrence or metastases.

Moran et al. [8] described only two cases of ectopic pleural thymoma treated surgically and there was no recurrence in these cases during the follow-up periods. However, several authors [5-8] described the poor outcome of the cases with local advancement. Therefore, a complete surgical resection for the lesion appears to be the treatment of choice. The study additionally proposes postsurgical radiation for local control is desirable. In the present case, even though adjuvant irradiation was not performed due to localized lesion, though a careful follow-up.

Conclusion

Primary pleural thymomas are rare tumors often mistaken as malignant mesothelioma. Thoracoscopy with biopsy is the best diagnosing means. Their classification and treatment is similar to conventional thymoma.

References

1. Martin JM, Randhawa G, Temple WJ (1986) Cervical thymoma. *Arch Pathol Lab Med* 110: 354-357.
2. Asa SL, Dardick I, Van Nostrand AW, Bailey DJ, Gullane PJ (1988) Primary

- thyroid thymoma: a distinct clinicopathologic entity. *Hum Pathol* 19: 1463-1467.
3. Kung IT, Loke SL, So SY, Lam WK, Mok CK, et al. (1985) Intrapulmonary thymoma: report of two cases. *Thorax* 40: 471-474.
 4. Moran CA, Suster S, Fishback NF, Koss MN (1995) Primary intrapulmonary thymoma. A clinicopathologic and immunohistochemical study of eight cases. *Am J Surg Pathol* 19: 304-312.
 5. Hofmann W, Möller P, Manke HG, Otto HF (1985) Thymoma. A clinicopathologic study of 98 cases with special reference to three unusual cases. *Pathol Res Pract* 179: 337-353.
 6. Fukayama M, Maeda Y, Funata N, Koike M, Saito K, et al. (1988) Pulmonary and pleural thymoma. Diagnostic application of lymphocyte markers to the thymoma of unusual site. *Am J Clin Pathol* 89: 617-621.
 7. Payne CB Jr, Morningstar WA, Chester EH (1966) Thymoma of the pleura masquerading as diffuse mesothelioma. *Am Rev Respir Dis* 94: 441-446.
 8. Moran CA, Travis WD, Rosado-de-Christenson M, Koss MN, Rosai J (1992) Thymomas presenting as pleural tumors. Report of eight cases. *Am J Surg Pathol* 16: 138-144.
 9. Attanoos RL, Galateau-Salle F, Gibbs AR, Muller S, Ghandour F, et al. (2002) Primary thymic epithelial tumors of the pleura mimicking malignant mesothelioma. *Histopathology* 41: 42-49.
 10. Fushimi H, Tanio Y, Kotoh K (1998) Ectopic thymoma mimicking diffuse pleural mesothelioma: a case report. *Hum Pathol* 29: 409-410.
 11. Honma K, Shimada K (1986) Metastasizing ectopic thymoma arising in the right thoracic cavity and mimicking diffuse pleural mesothelioma-an autopsy study of a case with review of literature. *Wien. Klin. Wochenschr* 98: 14A.
 12. Moran CA, Travis WD, Rosado-de-Christenson M, Koss MN, Rosai J (1992) Thymomas presenting as pleural tumors. Report of eight cases. *Am J Surg Pathol* 16: 138-144.
 13. Shih DF, Wang JS, Tseng HH, Tiao WM (1997) Primary pleural thymoma. *Arch Pathol Lab Med* 121: 79-82.
 14. Vural M, Abali H, Oksuzoglu B, Akbulut M (2006) An atypical presentation of thymoma with diffuse pleural dissemination mimicking mesothelioma. *Cancer Invest* 24: 615-620.
 15. Honma K, Shimada K (1986) Metastasizing ectopic thymoma arising in the right thoracic cavity and mimicking diffuse pleural mesothelioma -- an autopsy study of a case with review of literature. *Wien Klin Wochenschr* 98: 14-20.