

An Epidurogram During Fluoroscopy-Guided Caudal Epidural Reveals an Asymptomatic Tarlov Cyst in a Patient with Lumbar Radicular Pain: A Case Report

Revuelta M*, Bausili M, Melo M and Catala E

Pain Unit, Anesthesia Department, Hospital de la Santa Creu i Sant Pau, Universidad Autónoma de Barcelona, Spain

*Corresponding author: Revuelta M, Pain Unit, Anesthesia Department, Hospital de la Santa Creu i Sant Pau. Universidad Autónoma de Barcelona, Pain Unit (Anesthesia Department), Mas Casanovas 90, 08025 Barcelona, Spain, Tel: +34 606725166; Fax: +34 935537141; E-mail: mrevuelta@santpau.cat

Rec date: Jun 03, 2016; Acc date: Jun 07, 2016; Pub date: Jun 09, 2016

Copyright: © 2016 Revuelta M, et al. This is an open-access article distributed under the terms of the Creative Commons Attribution License, which permits unrestricted use, distribution, and reproduction in any medium, provided the original author and source are credited.

Abstract

Objective: Tarlov cysts are cerebrospinal fluid dilatations of the nerve root sheath at the dorsal root ganglion level. We report the incidental finding of a Tarlov cyst during a fluoroscopy-guided caudal epidural injection in a patient with acute lumbar radicular pain due to disc herniation.

Case report: A 76-year-old male was scheduled for an epidural steroid injection (ESI) for acute L5 radicular pain caused by a paracentral disc nucleus pulposus herniation. The ESI was administered via a caudal route because the patient had back surgery at the L3-L4 for Mal de Pott tuberculoses when he was 23-years old. The epidurogram revealed a fusiform image at the sacral level and the procedure was stopped. Afterwards, an MRI showed a sacral cyst of 50 × 18 mm and a left paracentral disc herniation at L4-L5 with L5 root compression.

Conclusion: The use of fluoroscopy with epidurogram during a caudal ESI allowed us to confirm epidural needle placement and to observe the cephalic flow of contrast medium into the level and side to treat. Without fluoroscopy, we would not have found this asymptomatic Tarlov cyst.

Keywords: Tarlov cysts; Cerebrospinal fluid; Fluoroscopy; Lumbar radicular pain

Introduction

Tarlov cysts are cerebrospinal fluid (CSF) dilatations of the nerve root sheath at the dorsal root ganglion. They are classified as Type II meningeal cysts [1]. Their prevalence has been estimated by MRI image of 1-5%. Only 1% of them are symptomatic [2,3]. The symptoms depend on their location, size and relationship to the nerve roots [4]. We report a case in which a fluoroscopy-guided caudal ESI in a patient with acute lumbar radicular pain due to left paracentral disc herniation at L4-L5 level disclosed an undiagnosed and asymptomatic Tarlov cyst.

Case Report

A 76-year-old male was referred to our Pain Unit for acute lumbar radicular pain that persisted for over six months. His past medical history was not contributory except for a posterior lumbar inter-body fusion at L2 and L3 and a bone graft for bone tuberculosis. The current pain started at the gluteus and radiated lateral and posterior to the calf of the left leg by L5-S1 distribution, there were neither motor or sensitivity deficits, nor foot irradiation. He rated the magnitude of pain as 8 on a numerical pain rating scale (NPRS) and reported worsening with movement and standing.

On examination, Lasègue, Crossed Lasègue and Bragard tests were positive, and the left leg was painful when walking on tiptoe. Lumbar and piriformis myofascial pain was negative. A CT scan showed lumbar degenerative disc disease (L4-L5), left paracentral herniation at

L4-L5 level that descended to the lateral recess and compromised L5 nerve root and posterior fusion at L2-L3.

A left paracentral disc herniation at L4-L5 with radicular compromise at L5 nerve root was diagnosed. Hence, an epidural with local anesthetic and steroids by caudal route was scheduled. The technique was performed under fluoroscopy guidance. Before injecting the contrast medium, aspiration through the needle was negative. When the epidurogram was performed, a fusiform image was unexpectedly seen at sacral level (Figures 1 and 2).

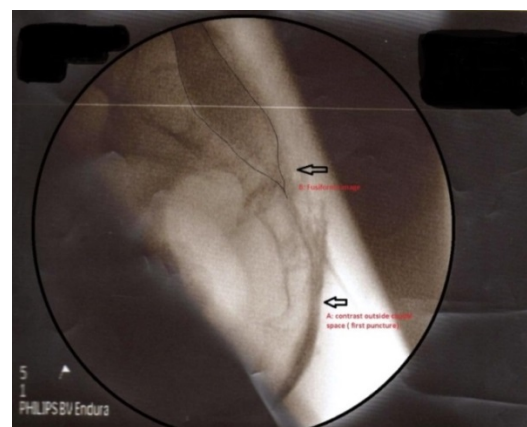


Figure 1: Fluoroscopy Lateral view. A. Contrast outside of caudal space B. Epidurogram showing the fusiform image at sacral level.

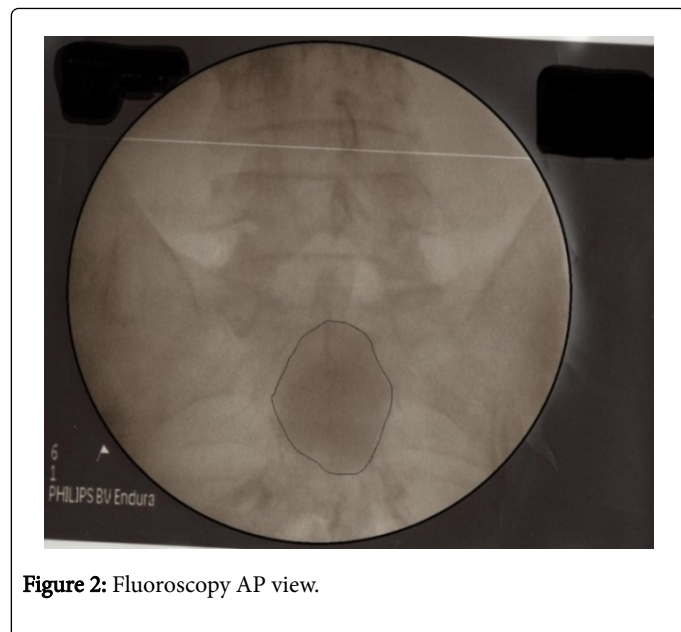


Figure 2: Fluoroscopy AP view.

Aspiration revealed a clear fluid. Suspecting CSF, we performed a glucose test, which proved positive [5] and confirmed intrathecal placement. The procedure was stopped to investigate the image seen in the epidurogram.

An MRI showed a sacral cyst of 50 × 18 mm (Figure 3) that was not visible in the CT scan, and a left lateral disc herniation at L4-L5 level with root compression of L5. Two days later, an interlaminar paramedial epidural at L5-S1 level was performed under fluoroscopy guidance to treat the radicular pain. Radicular leg pain improved after the epidural steroids injection (NPRS 3) and the patient was followed for 6 months without pain worsening.

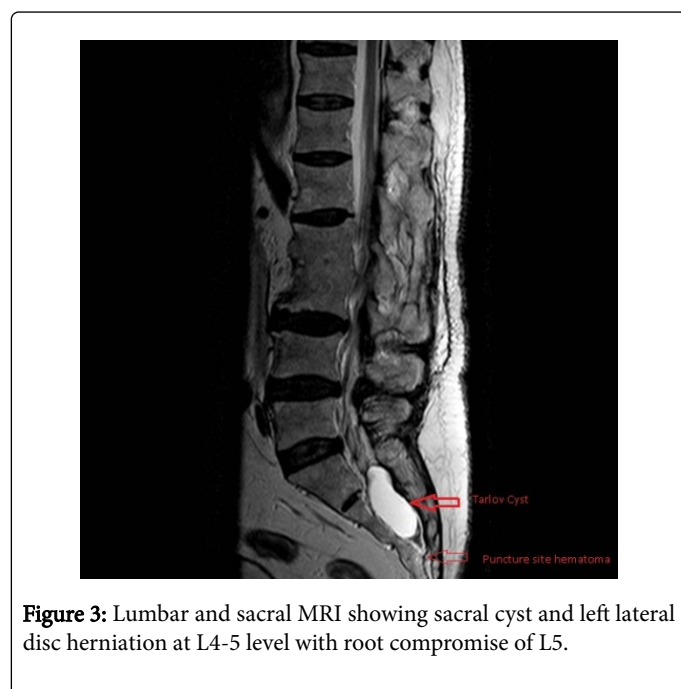

Figure 3: Lumbar and sacral MRI showing sacral cyst and left lateral disc herniation at L4-5 level with root compromise of L5.

Discussion

The present case report highlights the importance of evaluating the spread of the contrast medium in an epidurogram before administering the steroid to avoid severe complications. In our patient, cerebrospinal fluid was aspirated in the syringe after the contrast injection, and the fluoroscopy image was the first warning sign of an atypical caudal anatomy. In the MRI performed after the procedure was stopped, a sacral perineural Tarlov cyst was reported. First reported by Tarlov in 1938 [6], these lesions are extradural meningeal cysts that generally communicate through a pedicle with the subarachnoid space. Thus, they may contain cerebrospinal fluid and nerve fibers. Tarlov cysts are most commonly located in the S1 to S4 region, at the junction of the dorsal root ganglion and the posterior nerve root, and they usually develop between the endoneurium and epineurium of the nerve root [7]. Sometimes, they can produce symptomatology such as lumbar low-back pain, sacroccocigeal pain, perineal pain, sacral nerve root pain, leg weakness, neurogenic claudication and bowel, bladder and sexual dysfunction [8,9]. MRI is the diagnostic method of choice.

In the case we described, Tarlov cyst was not visible in a previous CT scan and the symptoms were not related to it.

In conclusion, the use of fluoroscopy with epidurogram during caudal ESI allowed us to confirm epidural needle placement and to observe the cephalic spread of contrast into the level and side to treat. Without fluoroscopy, we would not have found this asymptomatic Tarlov cyst.

Conflicts of Interest and Source of Funding

Revuelta M and Bausili M, for the remaining authors none were declared.

Melo M has received honoraria from Grunenthal, Pfizer, Grebo Companys' and was on the speaker's bureau for Ferre, Grunentha, Pfizer and Grebo Companys.

The Institution has received a grant from Carlos III Organization and Medtronic Company.

References

1. Nabors MW, Pait TG, Byrd EB, Karim NO, Davis DO, et al. (1988) Updated assessment and current classification of spinal meningeal cysts. *J Neurosurg* 68: 366-377.
2. Lucantoni C, Than KD, Wang AC, Valdivia-Valdivia JM, Maher CO, et al. (2011) Tarlov cysts: a controversial lesion of the sacral spine. *Neurosurg Focus* 31: E14.
3. Jung KT, Lee HY, Lim KJ (2012) Clinical experience of symptomatic sacral perineural cyst. *Korean J Pain* 25: 191-194.
4. Paulsen RD, Call GA, Murtagh FR (1994) Prevalence and percutaneous drainage of cysts of the sacral nerve root sheath (Tarlov cysts). *AJNR Am J Neuroradiol* 15: 293-297.
5. Seehusen DA, Reeves MM, Fomin DA (2003) Cerebrospinal fluid analysis. *Am Fam Physician* 68: 1103-1109.
6. Tarlov IM (1970) Perineural cysts of the spinal nerve roots. *Arch Neurol Psychiatry* 40: 1067-1074.
7. Joo J, Kim J, Lee J (2010) The prevalence of anatomical variations that can cause inadvertent dural puncture when performing caudal block in Koreans: a study using magnetic resonance imaging. *Anesthesia* 65: 23-26.

8. Acosta FL Jr, Quinones-Hinojosa A, Schmindt MH, Weinstein PR (2003) Diagnosis and management of sacral Tarlov cysts. Case report and review of the literature. Neurosurge Focus 15: E15.
9. Guo D, Shu K, Chen R, Ke C, Zhu Y, et al. (2007) Microsurgical treatment of symptomatic sacral perineurial cysts. Neurosurgery 60: 1059-1065.