

Amiodarone Pulmonary Toxicity: A Case Report and Review of the Literature

Zaineb Shamim¹, Pooja R Sarkar² and Murali G Krishna^{3,4*}

¹Foundation University Medical College, Islamabad, Pakistan

²Touro College of Osteopathic Medicine, Middletown, NY, USA

³Orange Regional Medical Center (ORMC), Middletown, NY, USA

⁴Division of Pulmonary, Critical Care and Sleep Medicine, Orange Regional Medical Group, Middletown, NY, USA

Abstract

Amiodarone, a common and efficacious antiarrhythmic agent, carries with it an array of serious side effects, most notably, amiodarone induced pulmonary toxicity, or APT. Patients typically present with dyspnea, and chest X-rays will show interstitial infiltrates. In severe cases, toxicity can lead to fibrosis and even respiratory failure. In this report, such effects are demonstrated based on the case of an 85 year old female who presented with multiple hospital admissions for multilobar pulmonary infiltrates and acute hypoxic respiratory failure, which did not respond to antibiotic therapy. She had, at the time of admission, been on amiodarone for over 2 years. The patient's amiodarone was discontinued, and she was started on prednisone. The patient displayed a significant clinical and radiographic improvement within 4 weeks. In patients with pulmonary infiltrates of unclear etiology who are on amiodarone, APT should be considered in the differential diagnosis. At this time, no specific diagnostic test for APT exists, and therefore clinical management must rely on a combination of clues gleaned from the medical history, diagnostic imaging, and a systematic exclusion of other differential diagnoses. A high index of suspicion is required to make the diagnosis of amiodarone pulmonary toxicity.

Keywords: Amiodarone; Pneumonia; Pulmonary toxicity

Introduction

Amiodarone toxicity can affect the pulmonary system in several different ways. It can present as acute respiratory distress syndrome (ARDS), diffuse alveolar hemorrhage (DAH), pulmonary nodules, multiple infiltrates, and rarely, pleural effusion. Amiodarone induced interstitial pneumonia can present similar to infectious pneumonia, heart failure and lung toxicity from other treatments. To diagnose interstitial pneumonitis due to amiodarone, a lung biopsy displaying distinctive histopathological changes is usually needed. However, clinical diagnoses can be made when signs, symptoms, and evaluations are consistent, especially when other possibilities have been excluded and the patient improves upon cessation of drug and glucocorticoid therapy.

Case Report

The patient was an 85 year old female who presented from a skilled nursing facility for increased lethargy, persistent fevers, and "worsening pneumonia." After being hospitalized for bilateral pneumonia a baseline chest radiograph (Figure 1B) was obtained that showed quite extensive bilateral infiltrates. She was deconditioned and sent back to the nursing facility where she was treated with various antibiotics for over a month. Her condition deteriorated and upon readmission a chest CT scan confirmed multifocal pneumonia (Figure 2). The patient was also noted to require supplemental oxygen to maintain adequate oxygen saturation. She did not have a prior history of needing oxygen routinely. Her past medical history was significant for hypertension, dyslipidemia and atrial fibrillation.

This patient was noted to be a non-smoker. Her current medications included amiodarone, atorvastatin, docusate sodium, ferrous sulfate, lactobacillus, losartan, multivitamin, lorazepam and ondansetron. The patient had been on amiodarone for over two years for rhythm control of chronic atrial fibrillation. Her physical exam was unremarkable, with a pulse oximetry of 84% on room air. An echocardiogram was performed that confirmed normal left ventricular function. Brain natriuretic peptide was 71.19 (≤ 100 pg/ml); within normal range. Blood work

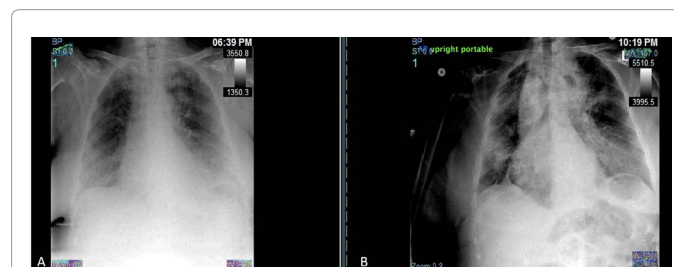


Figure 1: A: Follow up chest X-ray at four weeks post discontinuation of amiodarone showing significant reduction of alveolar and pleural abnormalities. Patient had full resolution of clinical symptoms. B: Baseline chest radiograph obtained upon first hospital admission for bilateral pneumonia that showed quite extensive bilateral infiltrates.

showed mild leukocytosis of 12.2. Blood chemistry was within normal range. A pulmonary consult was then requested for further evaluation of multilobar pulmonary infiltrates. Differential diagnosis included, but was not limited to, bacterial pneumonia, atypical bacterial pneumonia, nonresolving pneumonia, interstitial lung disease, cryptogenic organizing pneumonia and amiodarone induced pulmonary toxicity.

Amiodarone was discontinued and patient was started on glucocorticoid therapy- prednisone 60 mg daily for 4 weeks, followed by slow taper. At four weeks post discontinuation of amiodarone follow up X-ray showed significant reduction of alveolar and pleural abnormalities and full resolution of clinical symptoms (Figure 1A).

***Corresponding author:** Murali G Krishna, Orange Regional Medical Center (ORMC), 75 Crystal Run Road, Suite 135, Middletown, NY-10941, USA; Tel: 1-917-951-9661; Fax: 1-917-210-4307; E-mail: murali.krishna.md@gmail.com

Received March 03, 2016; **Accepted** May 06, 2016; **Published** May 09, 2016

Citation: Shamim Z, Sarkar PR, Krishna MG (2016) Amiodarone Pulmonary Toxicity: A Case Report and Review of the Literature. J Pulm Respir Med 6: 343. doi:10.4172/2161-105X.1000343

Copyright: © 2016 Shamim Z, et al. This is an open-access article distributed under the terms of the Creative Commons Attribution License, which permits unrestricted use, distribution, and reproduction in any medium, provided the original author and source are credited.

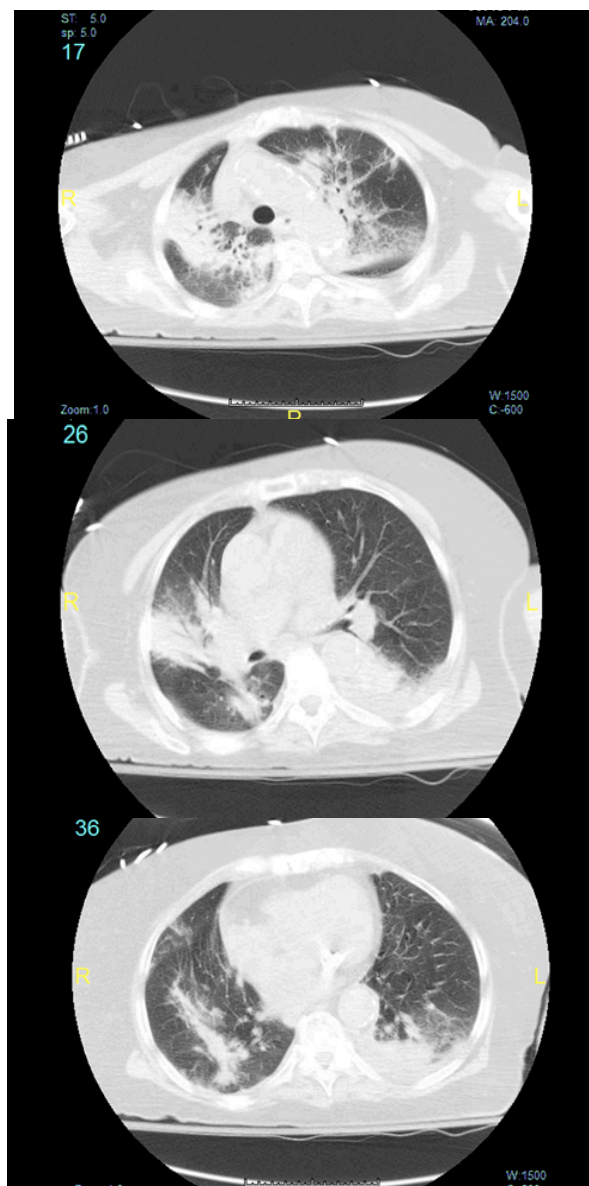


Figure 2: Chest CT scan confirming multifocal pneumonia during hospital admission with deterioration of patient symptoms.

Her oxygen saturation had returned to normal and the patient no longer needed oxygen therapy. She was subsequently followed by her cardiologist for alternate rhythm controlling agents for atrial fibrillation, as amiodarone was discontinued.

Discussion

Amiodarone is associated with many pulmonary diseases including most frequently interstitial pneumonitis, as well as ARDS, DAH, pulmonary nodules, and occasionally pleural effusion. Pulmonary toxicity due to amiodarone is rare and its prevalence cannot be accurately predicted. However, APT is estimated to occur in 1-5 percent of patients, and is dose-dependent. A growing body of clinical evidence points to patient age as a factor, with older patients, particularly those over the age of 60, showing the greatest susceptibility [1-3]. One of the factors predisposing patients to APT is the preexistence of pulmonary diseases [4]. In addition to older age and higher dosages as risk factors,

other patterns of susceptibility have been detected in the case of pulmonary toxicity. APT is more common in men, and is also common in patients of East Asian descent, particularly among the Japanese [5]. Factors other than demographics may also play a role, for in addition to higher doses, patients who are given pure oxygen, especially with mechanical ventilation, risk aggravation of pulmonary symptoms [6]. Pulmonary toxicity is regarded as one of the most serious side effects of the drug, however, patients tend to respond well to current treatment, which includes discontinuing amiodarone, and prescribing corticosteroids for up to one year to stabilize the patient. Nonetheless, early detection and confirmation is critical for a favorable prognosis [6].

Many adverse side effects of amiodarone, notably pulmonary toxicity, stem from the drug's molecular structure. Due to a hydrophilic side chain that enables amiodarone to be easily sequestered by lysosomes, amiodarone is retained within cells for a considerable amount of time leading to a long half-life (approximately 30-108 days) that allows for inhibition of key cellular processes [7]. For example, phospholipid turnover in cells is especially disturbed, causing an accumulation of phospholipids in the liver, nerves, and in particular, the lungs. Moreover, iodine in amiodarone molecules has intrinsic properties against the pulmonary system. Even though amiodarone is a drug targeted for heart arrhythmias, the effects of the drug on the lungs is very pronounced. Desethylamiodarone, an amiodarone metabolite, can infiltrate lung tissue five times more than amiodarone [8]. Thus these factors contribute to prolonged effects of amiodarone even after the drug has been discontinued and in conjunction are the major causes of pulmonary toxicity induced by amiodarone [9].

Our reported patient was female, and on 200 mg of Amiodarone daily, which is considered a low dose treatment; however, she still presented with toxicity. The patient also did not have any prior lung issues, and when given oxygen for APT-related symptoms, her condition was indeed noted to deteriorate. She did possess one factor, her age, which put her at risk for APT [6]. In the early stages, the onset of non-productive cough and difficulty in breathing may be present, often in more than half of affected patients. Fever is less common, presenting in 33-50% of patients, and symptoms such as weight loss and pleuritic pain have also been described. Physical examination will usually lead to findings of bilateral inspiratory crackles. Typically, symptoms are seen within 6-12 months of starting the drug, but there is still a possibility of toxicity occurring even after many years of treatment. As stated earlier, because amiodarone is known to accumulate in fatty tissues and has a relatively long half-life, pulmonary toxicity may persist or even increase following discontinuation of the drug [7]. Peripheral blood work will usually show an elevated white blood cell count, as well as high levels of serum lactate dehydrogenase (LDH), C-reactive protein, and red blood cell sedimentation rate. However, amiodarone levels are usually within normal range.

This patient presented with similar symptoms. Her history suggested non resolving pneumonia, low grade fevers, cough and hypoxia. Imaging revealed bilateral alveolar infiltrates. She did not respond to antibiotics suggesting an alternative underlying inflammatory condition affecting the lung parenchyma. She had no preexisting pulmonary condition, and heart failure was ruled out per normal left ventricular echocardiogram. After repeated hospitalizations, multiple antibiotics, Infectious Disease and pulmonary consultations, it was the clinical impression that she likely had amiodarone induced pulmonary toxicity. Amiodarone was discontinued and patient started on glucocorticoid therapy. The patient showed immediate improvement clinically and radiographically, with a complete resolution in 4 weeks. A lung biopsy should be reserved for patients who do not respond after discontinuation of amiodarone and

corticosteroid therapy.

Conclusion

Amiodarone pulmonary toxicity should be considered in the differential diagnosis for patients who are on amiodarone and also demonstrate pulmonary infiltrates. A high index of clinical suspicion is needed to make the diagnosis of amiodarone pulmonary toxicity. Additionally, patients on low doses of amiodarone should not be excluded from any suspicions regarding toxicity, even if they do not fit a specific demographic. It is important to note that this particular patient did not have any pre-existing pulmonary illness, and yet she was affected by amiodarone pulmonary toxicity. Given the declining status of this patient, in spite of aggressive oxygen therapy, a timely diagnosis was critical. This case illustrates the importance in vigilant clinical observation and prompt amiodarone withdrawal, even in patients who may be considered lower risk due to lower dose amiodarone regimens.

References

1. Connolly S (1999) Evidence-Based Analysis of Amiodarone Efficacy and Safety. *Circulation* 100: 2025-2034.
2. Tuzcu EM, Maloney JD, Sangani BH, Masterson ML, Hocevar KD, et al. (1987) Cardiopulmonary effects of chronic amiodarone therapy in the early postoperative course of cardiac surgery patients. *Cleve Clin J Med* 54: 491-497.
3. Ernawati DK, Stafford L, Hughes JD (2008) Amiodarone-induced pulmonary toxicity. *Br J Clin Pharmacol* 66: 82-87.
4. JessurunG, Boersma W, Crijns H (1998) Amiodarone-Induced Pulmonary Toxicity. *Drug Safety* 18: 339-344.
5. Camus P, Martin WJ 2nd, Rosenow EC 3rd (2004) Amiodarone pulmonary toxicity. *Clin Chest Med* 25: 65-75.
6. Wolkove N, Baltzan M (2009) Amiodarone pulmonary toxicity. *Can respir J* 16: 43-48.
7. Nacca N, Bhamidipati CM, Yuhico LS, Pinnamaneni S, Szombathy T (2012) Severe amiodarone induced pulmonary toxicity. *J Thorac Dis* 4: 667-670.
8. Abuzaid A, Saad M, Ayan M, Kabach A, Haddad TM, et al. (2015) Acute Amiodarone Pulmonary Toxicity after Drug Holiday: A Case Report and Review of the Literature. *Case Reports in Cardiology* pp: 1-3.
9. Camus P, Rosenow E (2010) Drug-induced and Iatrogenic Respiratory Disease. Boca Raton: CRC Press pp: 240-249.