

Addition of Insulin-like Growth Factors (IGF-1) for the Regeneration of Critical Defects in Peripheral Nerve Injuries. Biological Findings

Belén García Medrano^{1*}, Clarisa Simón Pérez¹, Patricia Barrio Sanz², Manuel Garrosa García³, Manuel José Gayoso Rodríguez³ and Miguel Ángel Martín Ferrero¹

¹Hospital Clínico, Valladolid, Spain

²Hospital Infanta Sofía, San Sebastián de los Reyes, Madrid, Spain

³Cellular biology department, Medicine Faculty, University of Valladolid, Spain

Abstract

Introduction: The purpose is analyze the biological and cellular regeneration of non-repairable lesions of peripheral nerve by muscle graft enhanced with growth factors.

Methods: Controlled clinical experimental trial, level I evidence. Critical peripheral nerve injuries repair through acellular muscle graft alone versus its enrichment with IGF-1 (10 mg/ml mecasepmin). Clinical and functional control for 3 months. Animals were sacrificed at 90-100 days, obtaining samples for macro and microscopy with blue toluidine staining, hematoxylin-eosin and Masson trichrome.

Results: Regenerating axons can pass through a defect length of 15 mm with the addition of an acellular skeletal muscle graft and repopulate the distal nerve. Basal lamina tubes, acting as matrices for the axonal growth, appears that sensory recovery exceeds the rate of motor nerve fibers growth. Finding a number of regenerating axons greater than healthy sciatic, ensures the functional connection of distal axons to their target innervation. In contrast, grafts myelinated fibers are smaller than those of healthy sciatic nerve.

Discussion: Acellular muscle fibers basal lamina define tubes that could support axonal regeneration, acting as matrices for the growth of axons, when grafted into a nerve defect. Stereologic studies biological sections to quantify the increase in the total number of axons, the density thereof and the thickness of the myelin from microscopic examination of histological slices of animals treated with the growth factor IGF-1.

Keywords: Cellular repair; Biological regeneration; Critical tissue defect in peripheral nerve; Muscle grafts; Growth factors

Introduction

Peripheral nerve injuries represent a major cause of morbidity and disability, and generate high economic costs, especially those associated with significant loss of nerve tissue, causing irreparable defects by end-to-end suture. The purpose of a nerve graft procedure is to substitute a defect in a severed nerve trunk to allow regeneration of a maximal number of regenerated nerve fibers to their target organs. Millesi et al., [1] obtained successful results by using autografts of the sural nerve, a technique that became the gold standard, but the limited availability of nerve tissue, the incomplete obtained functional recovery and problems with the donor, have motivated the search of other alternatives.

A large number of studies have been undertaken to develop alternatives and to improve results. Keynes et al. [2], discovered that the basement membrane of the muscle cells was useful as a way for the growth of regenerating axons, through the basal lamina. Glasby et al. [3] obtained a useful step of axons through endomysium channels, as they are similar to those of endoneurium. Pereira et al. [4] began their studies on denatured muscle graft substitute for mycobacterial granulomatous lesions in peripheral nerves of leprosy. Brunelli et al. [5] developed an experimental model in rats with a vein graft filled with fresh skeletal muscle, leading to similar results as the traditional nerve grafts. DeFranzo et al. [6] examined the use of freeze-thawed muscle and nerve graft in rats, analyzing histologically the density of axons and myelination. Whitworth et al. [7] incorporated a deposit of Schwann cells and other essential components in a nerve conduit, with a marked positive effect on axonal regeneration. Martín Ferrero et al. [8] used freeze dried denatured skeletal muscle, with passage of axons to the distal segment in more than 60% of oligofascicular and more

than 45% in the polyfascicular nerve. Battiston et al., [9,10] described how the muscle fibers represents a good support for advancing axons through adhesion molecules present in the basal lamina of muscle fibers increasing neurite extension.

Scherman et al. [11] demonstrated that axons and Schwann cells grew more rapidly in the chemically acellular muscle grafts than in freezing-thawing used for denaturation.

Other substances could promote regeneration of nerve tissue, such as nerve growth factor (NGF), epidermal growth factor (EGF) and platelet-derived growth factors (PDGF). Yu et al. [12] looked at the histological effect of NGF treated acellular grafts, revealing an axonal diameter, total number and thickness of myelin better after NGF treatment than in nerves repaired with acellular grafts alone and acellular grafts with fibrin sealant.

The historical scientific development has granted a previously undiscovered role to insulin-like growth factors in peripheral nerve regeneration, to detect the presence of receptors for IGF, located in

***Corresponding author:** Belén García Medrano, Hospital Clínico, Valladolid, Spain, Tel: 34 630955388; E-mail: belengarciamedrano@gmail.com

Received February 17, 2014; **Accepted** March 19, 2014; **Published** March 21, 2014

Citation: Medrano BG, Pérez CS, Sanz PB, García MG, Rodríguez MJG, et al. (2014) Addition of Insulin-like Growth Factors (IGF-1) for the Regeneration of Critical Defects in Peripheral Nerve Injuries. Biological Findings. J Cytol Histol 5: 221. doi:10.4172/2157-7099.1000221

Copyright: © 2014 Medrano BG, et al. This is an open-access article distributed under the terms of the Creative Commons Attribution License, which permits unrestricted use, distribution, and reproduction in any medium, provided the original author and source are credited.

the growing points and along the axis of the axons [13]. Local infusion of IGF-I has been shown to increase the distance of regeneration of sensory axons injured rat sciatic nerves [14,15].

The aim of our study is analyze the best method of muscle grafts denaturation, trying to understand whether the local infusion of insulin-like growth factors (IGF-1) improve axonal regeneration.

Material and Methods

This study is a controlled experimental study, level I evidence. In twenty male Wistar rats (average weight 278 g), a critical defect of 15 mm was created in the sciatic nerve, which was bridged by an acellular muscle graft. In 10 of the animals the entire protocol was used but also, adding growth factors to their grafts. All muscle grafts were obtained from the gluteus medius muscle of two donor rats. Special detail was given to the section of the grafts along the longitudinal axis of the muscle, not to interrupt the histological structure of the endomysium tubes.

The chemically cellular extraction protocol consisted of 7 h in distilled water changed three times every 2-3 h, one night in Triton detergent, and 24 h in deoxycholate [16].

After intraperitoneal preoperative anesthesia, and by posterolateral approach, the sciatic nerve was exposed from its output below the piriformis muscle up to the most distal possible level to always see its terminal division in the tibial and peroneal branches (Figure 1). After location of the trunk, the nerve was transected generating a 15 mm defect. An acellular muscle block was added, where the epimysium-epinervium were sutured with polypropylene 7/0 at each end (Figure 2). Within half of the grafts, we injected 2 ml of Increlex[®] (10 mg/ml mecasermin), thereby providing the IGF-1 factors. Sutures were sealed with fibrin (Tissucol[®], Baxter, Valencia, Spain).

When they woke up, two of them were together in a cage because of their gregarious way of life. They carried an Elizabethan collar to avoid autophagy. Antibiotics were given: Calimicina[®] LA (oxytetracycline) at doses of 60 mg per kg of weight to repeat at 72 h, by interscapular subcutaneous injection, according to veterinary guidelines. And analgesia: Ibuprofen in the drinking water.

Rats were sacrificed at 90-100 days post-surgery (body-weight of 450-500 g). Same surgical approach was repeated dissecting segment sciatic nerve including muscle graft, performing in a second time, a post-fixation of samples for 4 h at 40°C, to prevent cell shrinkage in

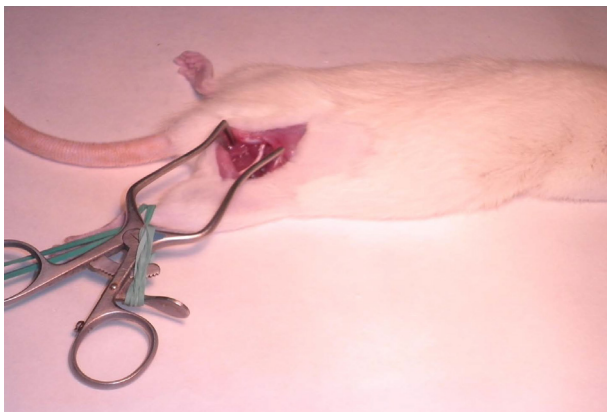


Figure 1: Sciatic nerve dissection by postero-lateral approach.

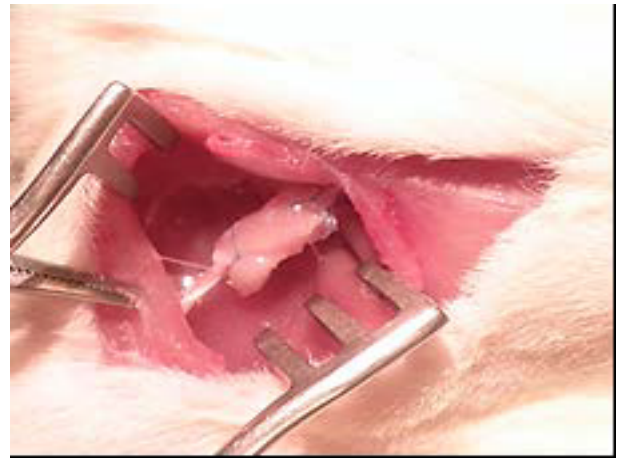

Figure 2: Denatured autologous muscle graft as a bridge of critical defect in the rat sciatic nerve (intraoperative image).

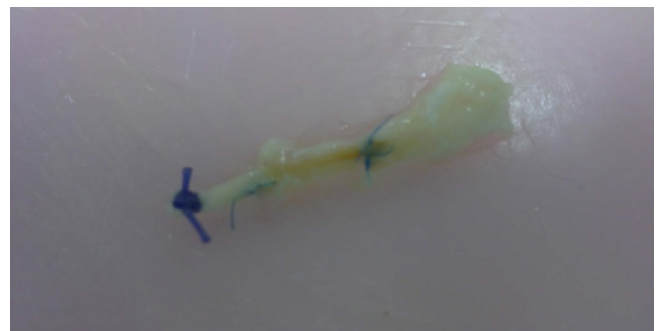

Figure 3: Anatomical piece extraction, including sciatic nerve stumps and graft.

paraformaldehyde solution (4% w/v, 4 g of solute are dissolved in 100 ml of solution) in 0.1 Molarity phosphate buffer (pH=7.4). Samples were obtained for macro and microscopic preparations. The explanted pieces of sciatic nerve with grafts were carved and cut into seven pieces, all different from each other in cross sections and size, but equally in all animals; pieces were processed in resin (toluidine blue staining) and also for paraffin embedding: hematoxylin-eosin and Masson trichrome.

For the histomorphometric study, myelinated axons were counted in cross sections, manually. Results were analyzed statistically using SPSS version 20.0 for Windows; comparisons were made with two-way ANOVA. The lower differences at $p < 0.05$ were considered statistically significant.

Results

Macroscopically, a bead yellowish, tubular structure, filled the gap between the two sutures of the graft (Figure 3).

Microscopically, proximal ends appeared as a normal nerve, with proper, regular and orderly fascicular distribution, perfectly defined by its three wraps, with little connective tissue; symmetry of the axon density, coverage regularly by myelin sheath dependent on Schwann cells. In the case group, animals that were treated with IGF-1 inside the graft, these pieces showed perhaps a more even regular distribution in some of them.

At the graft, regenerated axons used the muscle as a bridge, with many small nerve fascicles separated by host tissue and plenty of blood vessels. Axons followed their basal lamina, defining small fascicles with large vessels and abundant connective tissue. Nerve fibers are abundant in nerve treated with growth factor, occupying almost all the cut surface, more densely packed (Figure 4). In two cases, nerve fiber bundles penetrate, not very deep, between acellular muscle fibers.

At the distal end, untreated controls don't show a clear fascicular division. There was little connective tissue between the fibers and the epineurium was quite developed. The untidiness may be justified because the fibers are still looking for its way. The IGF-1 cases showed the presence of a number of small fascicles with myelinated axons, which colonize the distal stump. In this region, they showed a normal mature nerve structure with well-developed epineurium and perineurium moderate and endoneurium.

There were a short number of myelinated fibers with a smaller diameter and more irregular arrangements in the untreated group. The comparison of the total number of axons and density of axons per

field speaks for enhancing the results by adding the concentrated IGF-1 (14.8% greater recovery of the axon number by comparing proximal and distal sections; 10.49% comparing density of axons). We found a statistically significant difference in myelin thickness at the graft and the distal stump between both groups (Figure 5).

Ultrastructurally by electron microscope, no significant differences were detected between sections at the graft and distal end, in either group of study. But the histological analysis, let us discover the presence of unmyelinated fibers with their common features: wrappers of Schwann cell cytoplasm surrounding the beams of nerve fibers, but without creating any myelin sheath.

Discussion

Peripheral nerve injuries represent one major cause of morbidity and disability in affected patients and generate high economic costs. Their repair is a challenge for current research, and by the need to discover economic and biologically feasible techniques. The results have to match the classical autologous nerve.

With this study, we have tried to advance in search of different ways to present the muscle graft as a bridge in the critically injured nerve, and the options available for us to enrich it biologically, supporting our project in the current experiments with growth factors.

Quantitative estimation of the morphology of the nerve fiber (especially myelinated) is, together with the functional evaluation, a key research tool in nerve regeneration [17,18].

Although the number and density of nerve fibers are indicators used in nerve regeneration, both parameters should be interpreted with caution. In fact, a significant number of regenerated nerve fibers may not only indicate a good feedback, but also the finding of an aberrant bud (in this case the evaluation of the size of the fiber can provide additional information). This is the interpretation offered by some authors to the absence of correlation between the total number of myelinated axons and functional parameters (studies of muscle contraction, nerve conduction and mobility of extremities) detected in their researches (Varejão et al.; Ahmed; Pfister et al.) [19-21].

In our investigation, comparing the number of axons and their density on the three main histological slices, we detected values described in the literature as significant of regeneration and quite similar between the two groups. The total number of axons in the group of rats treated with IGF-1 is higher: 11.59% in the distal stump and 5.84% within the graft, but not in the proximal one, 3.2% less, even though the result is not statistically significant. At this level, axons per field were similar, their difference of 5 axons/field in favor of the control group was not significant. Perhaps would become more important if we look at the size of the slice in the control group, which was slightly lower. The data published in the literature not reach statistically significant differences in total number of axons calculation [22-24].

Our findings about the higher density of axons in the IGF-1 group, are comparable to others published, although the difference was not statistically significant in those researches [25,26]. But they are different to those papers which reach lower density than in the control group.

Quantitative evaluation of tissues and organs on histological sections has been the subject of heated scientific debate in recent years. Particularly, the emergence of a new approach to address the bias of the morphometric analysis, represented a significant advance in Neuromorphology [27-30].

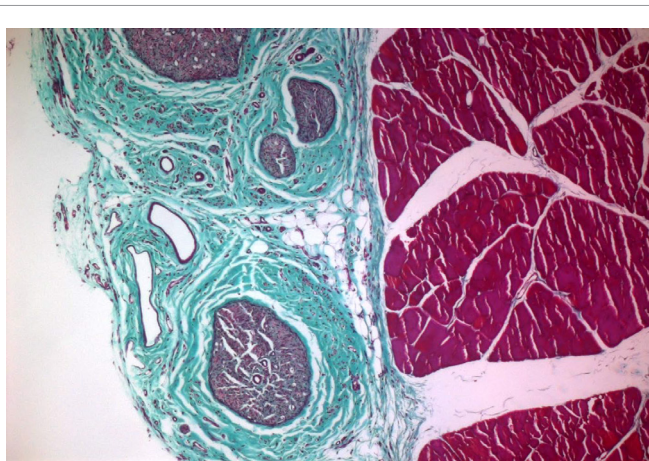

Figure 4: Development of nervous structure with regeneration signs and abundant perineural connective tissue to the left, resting on a block of muscle. Masson trichrome stain, magnified 5 times.

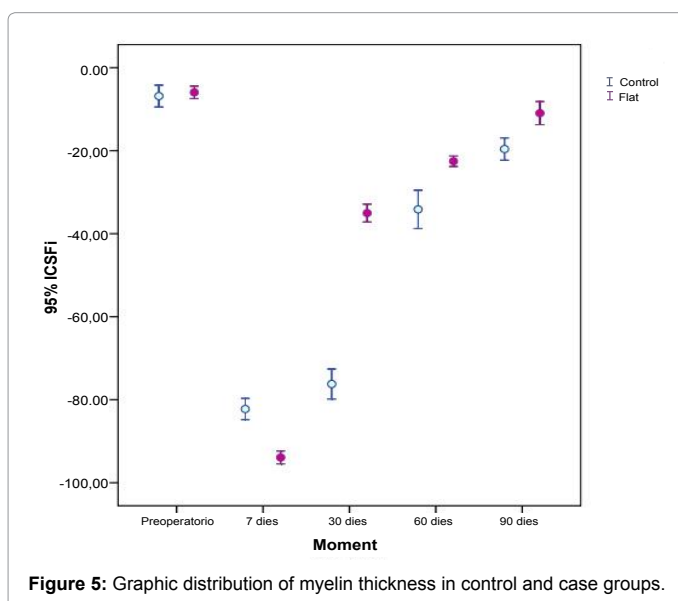


Figure 5: Graphic distribution of myelin thickness in control and case groups.

The analysis of the myelin thickness and its comparison between the two groups is difficult, because dimensions of these structures are very small to be measured exactly and it would be easy to skew the data, obtaining a misleading result. As the axon counting and the density of axons were calculated manually, histomorphometric measures didn't regard computer method. This could also increase the bias of the measurement. The observed results confirm us the empowerment of histological data in the IGF -1 -treated group, an increase is found in the three analyzed sections, which is also progressive, proximal to distal (2.99% thicker in the group of cases in the proximal stump; 16.07% at the graft, and an increase of 28.31% in the distal end). An improvement in the myelin thickness at the graft and in the distal stump, are statistically significant. It is difficult to compare with those published in the literature, because usual articles that describe the influence of growth factors on the myelin thickness, support our conclusion, but not quantified this improvement [31,32].

Extrapolation of the histomorphometric parameters can lead to a misinterpretation on functional recovery [33]. Stereological studies, that measure the total number of axons and myelin thickness, don't allow discover if the axon reaches its appropriate target or organ [34]. In multiple studies, the number of myelinated axons doesn't correlate with functional parameters (such as muscle contraction or the mobility of limbs, quantifiable by plantar footprint analysis or walking videos) nor nerve conduction studies (Ahmed MR, 2005). The finding of poorer functional data than satisfactory histomorphometric data may be due to the mismatch of axons to reinnervate the target organ [19].

Clinical reports, which try to correlate the results of quantifiable measures, both histological and functional, become interesting for the study design, because they underscore the need to consider the different aspects of nerve regeneration, to reach all the miscellaneous parameters we possess to be able to compare them, and reject those that may prove erroneous outcomes.

Conclusions

In a critical peripheral nerve injury, allogenic acellular muscle graft provides a bridge tool for the advancement of the regenerating axons, perhaps due to the structural proximity of laminin to nerve sheaths. With the use of growth factors we achieved more satisfactory results.

Stereologic studies quantify the increase in the total number of axons, the density thereof and in the thickness of the myelin sheath, when we analyze microscopically the histological specimens from animals treated with the growth factor IGF-1. This histomorphometric improvement is correlated with clinical and functional findings.

Applying a concentrate of insulin-like growth factors enhances the results obtained in the control group. Peripheral nerve regeneration requires a complex interaction between cells, extracellular matrix and growth factors. The local presence of growth factors plays a role in controlling survival, migration, proliferation, and differentiation of various cell types involved in nerve regeneration.

References

1. Millesi H, Meissl G, Berger A (1972) The interfascicular nerve-grafting of the median and ulnar nerves. *J Bone Joint Surg Am* 54: 727-750.
2. Keynes RJ, Hopkins WG, Huang LH (1984) Regeneration of mouse peripheral nerves in degenerating skeletal muscle: guidance by residual muscle fibre basement membrane. *Brain Res* 295: 275-281.
3. Glasby MA, Gschmeissner S, Hitchcock RJ, Huang CL (1986) Regeneration of the sciatic nerve in rats. The effect of muscle basement membrane. *J Bone Joint Surg Br* 68: 829-833.
4. Pereira JH, Cowley SA, Gschmeissner SE, Bowden RE, Turk JL (1990) Denatured muscle grafts for nerve repair. An experimental model of nerve damage in leprosy. *J Bone Joint Surg Br* 72: 874-880.
5. Brunelli GA, Battiston B, Vigasio A, Brunelli G, Marocolo D (1993) Bridging nerve defects with combined skeletal muscle and vein conduits. *Microsurgery* 14: 247-251.
6. DeFranzo AJ, Morykwas MJ, LaRosse JR, Jennings DA, Challa V, et al. (1994) Autologous denatured muscle as a nerve graft. *J Reconstr Microsurg* 10: 145-149.
7. Whitworth IH, Doré C, Hall S, Green CJ, Terenghi G (1995) Different muscle graft denaturing methods and their use for nerve repair. *Br J Plast Surg* 48: 492-499.
8. Martín Ferrero MA, Agudo Bernal J, Vaquero Puerta C, García Cantera M, Sánchez Martín MM (1996) Autoinjerto de músculo estriado desnaturalizado en las pérdidas de sustancia del nervio periférico. Estudio experimental. *Revista Española de Cirugía Ortopedia y Traumatología* 40: 77-83.
9. Battiston B, Tos P, Geuna S, Giacobini-Robecchi MG, Guglielmo R (2000) Nerve repair by means of vein filled with muscle grafts. II. Morphological analysis of regeneration. *Microsurgery* 20: 37-41.
10. Battiston B, Geuna S, Ferrero M, Tos P (2005) Nerve repair by means of tubulization: literature review and personal clinical experience comparing biological and synthetic conduits for sensory nerve repair. *Microsurgery* 25: 258-267.
11. Scherman P, Lundborg G, Kanje M, Dahlin LB (2001) Neural regeneration along longitudinal polyglactin sutures across short and extended defects in the rat sciatic nerve. *J Neurosurg* 95: 316-323.
12. Yu H, Peng J, Guo Q, Zhang L, Li Z, et al. (2009) Improvement of peripheral nerve regeneration in acellular nerve grafts with local release of nerve growth factor. *Microsurgery* 29: 330-336.
13. Caroni P, Grandes P (1990) Nerve sprouting in innervated adult skeletal muscle induced by exposure to elevated levels of insulin-like growth factors. *J Cell Biol* 110: 1307-1317.
14. Kanje M, Skottner A, Sjöberg J, Lundborg G (1989) Insulin-like growth factor I (IGF-I) stimulates regeneration of the rat sciatic nerve. *Brain Res* 486: 396-398.
15. Sjöberg J, Kanje M (1989) Insulin-like growth factor (IGF-1) as a stimulator of regeneration in the freeze-injured rat sciatic nerve. *Brain Res* 485: 102.
16. Baptista PM, Orlando G, Mirmalek-Sani SH, Siddiqui M, Atala A, et al. (2009) Whole organ decellularization - a tool for bioscaffold fabrication and organ bioengineering. *Conf Proc IEEE Eng Med Biol Soc* 2009: 6526-6529.
17. Geuna S, Tos P, Battiston B, Giacobini-Robecchi MG (2004) Bridging peripheral nerve defects with muscle-vein combined guides. *Neurol Res* 26: 139-144.
18. Vleggeert-Lankamp CL (2007) The role of evaluation methods in the assessment of peripheral nerve regeneration through synthetic conduits: a systematic review. *Laboratory investigation. J Neurosurg* 107: 1168-1189.
19. Varejão AS, Melo-Pinto P, Meek MF, Filipe VM, Bulas-Cruz J (2004) Methods for the experimental functional assessment of rat sciatic nerve regeneration. *Neurol Res* 26: 186-194.
20. Ahmed MR, Jayakumar R (2005) Peripheral nerve regeneration in cell adhesive peptide incorporated collagen tubes in rat sciatic nerve -- early and better functional regain. *J Peripher Nerv Syst* 10: 390-391.
21. Pfister LA, Papalóizos M, Merkle HP, Gander B (2007) Nerve conduits and growth factor delivery in peripheral nerve repair. *J Peripher Nerv Syst* 12: 65-82.
22. Oliveira EF, Mazzer N, Barbieri CH, DelBel EA (2004) The use of a muscle graft to repair a segmentary nerve defect. An experimental study using the sciatic nerve of rats as model. *J Neurosci Methods* 133: 19-26.
23. Haisheng H, Songjie Z, Xin L (2008) Assessment of nerve regeneration across nerve allografts treated with tacrolimus. *Artif Cells Blood Substit Immobil Biotechnol* 36: 465-474.
24. Moore AM, MacEwan M, Santosa KB, Chenard KE, Ray WZ, et al. (2011) Acellular nerve allografts in peripheral nerve regeneration: a comparative study. *Muscle Nerve* 44: 221-234.
25. Di Benedetto G, Grasseti L, Mazzucchelli R, Scarpelli M, Bertani A (2009) Peripheral nerve regeneration: autologous conduit of vein plus perineurium. *Eur J Plast Surg* 32: 33-36.

26. Rustemeyer J, van de Wal R, Keipert C, Dicke U (2010) Administration of low-dose FK 506 accelerates histomorphometric regeneration and functional outcomes after allograft nerve repair in a rat model. *J Craniomaxillofac Surg* 38: 134-140.
27. Geuna S (2005) The revolution of counting "tops": two decades of the disector principle in morphological research. *Microsc Res Tech* 66: 270-274.
28. Schmitz C, Hof PR (2005) Design-based stereology in neuroscience. *Neuroscience* 130: 813-831.
29. Baryshnikova LM, Von Bohlen Und Halbach O, Kaplan S, Von Bartheld CS (2006) Two distinct events, section compression and loss of particles ("lost caps"), contribute to z-axis distortion and bias in optical disector counting. *Microsc Res Tech* 69: 738-756.
30. Canan S, Bozkurt HH, Acar M, Vlamings R, Aktas A, et al. (2008) An efficient stereological sampling approach for quantitative assessment of nerve regeneration. *Neuropathol Appl Neurobiol* 34: 638-649.
31. Zeger M1, Popken G, Zhang J, Xuan S, Lu QR, et al. (2007) Insulin-like growth factor type 1 receptor signaling in the cells of oligodendrocyte lineage is required for normal in vivo oligodendrocyte development and myelination. *Glia* 55: 400-411.
32. Furusho M, Dupree JL, Nave KA, Bansal R (2012) Fibroblast growth factor receptor signaling in oligodendrocytes regulates myelin sheath thickness. *J Neurosci* 32: 6631-6641.
33. Mohammadi R, Esmail-Sani Z, Amini K (2013) Effect of local administration of insulin-like growth factor I combined with inside-out artery graft on peripheral nerve regeneration. *Injury* 44: 1295-1301.
34. Van Neerven SG, Bozkurt A, O'Dey DM, Scheffel J, Boecker AH, et al. (2012) Retrograde tracing and toe spreading after experimental autologous nerve transplantation and crush injury of the sciatic nerve: a descriptive methodological study. *J Brachial Plex Peripher Nerve Inj* 7: 5.