

Acute Pyelonephritis: The clot unfolds

Talwar A¹, Kavidasan A¹, Randhawa R¹, Bhattacharya M¹, Somani V¹, Raza M¹ and Shenbaguraman P²

¹Milton Keynes Hospital, NHS Foundation Trust, UK

²Renal Unit, Oxford University Hospitals NHS Foundation Trust, UK

Abstract

We report a case of Renal Vein Thrombosis (RVT) thought to be a complication of acute pyelonephritis in a 44 year old female presenting to the acute medical take. The most common cause of RVT is nephrotic syndrome, due to a hyper-coagulable state. RVT is also seen in renal cell carcinoma due to tumour invasion. A possible theory relating RVT to acute pyelonephritis may relate to concomitant thrombophlebitis of the renal vein in pyelonephritis, which then predisposes to thrombosis.

The patient was subsequently investigated for possible causes of this thrombotic event and anticoagulated. The management of RVT is also discussed. We hope this case highlights the importance of keeping an open mind and adding to the original management when a new, but unexpected finding is made.

Keywords: Renal vein thrombosis; Nephrotic syndrome; Acute pyelonephritis

Case Report

A 44 year old female presented to the acute medical take with a 2 month history of intermittent fevers and rigors associated with left loin and back pain and vomiting. She had been recently treated for *Escherichia coli* UTI in the preceding week.

Mrs X was a newly diagnosed type 2 diabetes taking metformin she was currently working as a tax advisor and was a lifelong non-smoker. Clinical examination revealed a temperature of 39.6°C and tachycardia. The left loin was tender to palpation. There was no evidence of lymphadenopathy or any other system abnormality. Urine dip revealed microscopic haematuria. MSU on this occasion was negative. Blood tests revealed a CRP of 214 mg/L (normal range <10), W.C.C of 8.4 x/L (normal range 3.5-12), Creatinine 43 micromols/L (normal range 40-110), Urea 2.3 milimols/L (normal range 4-8.2) and ESR 11 milimetres/h. Blood Cultures did not grow any organisms. A chest radiograph revealed no consolidation. She was commenced on intravenous tazocin and gentamycin for likely acute pyelonephritis. The patient continued to spike temperatures despite antibiotic therapy and so a CT KUB was conducted and revealed left renal vein thrombosis.

No other organ abnormality was reported.

A further detailed history from the patient revealed no red flag symptoms for malignancy or vasculitis. Family history revealed the patient's paternal aunt had a spontaneous pulmonary embolism in her 50's. The possible causes of RVT were investigated with urine ACR, which excluded nephrotic syndrome. Breast examination and a staging CT of the neck, thorax, abdomen and pelvis revealed no occult malignancy. Autoantibodies including ANA, ANCA and complement levels were all normal.

The patient was commenced on treatment dose dalteparin and then commenced on warfarin. She continued treatment with intravenous antibiotics for 19 days until her inflammatory markers fell (CRP fell from 214 mg/L to 18.6 mg/L) and she remained afebrile. Her renal function remained stable throughout the admission. She continued to be followed up as an outpatient. After 1 year of anticoagulation the warfarin was stopped. She underwent a full thrombophilia screen that did not reveal any underlying pathology accounting for the RVT. Overall it was felt that the RVT was precipitated by pyelonephritis. She now remains well.

Discussion

It can be difficult to distinguish between acute pyelonephritis and RVT on clinical grounds. RVT can also be asymptomatic. The most common cause of RVT is nephrotic syndrome. Spontaneous RVT is rare. RVT as a result of an infectious process of the kidney is rarely reported. A possible theory may relate to concomitant thrombophlebitis of the renal vein in pyelonephritis, which then predisposes to thrombosis [1]. It is also thought that when gram negative bacteria release their endotoxin into the bloodstream, the lipopolysaccharide can change the endothelial lining of the blood vessels from an anticoagulant profibrinolytic surface into a thrombogenic one [2].

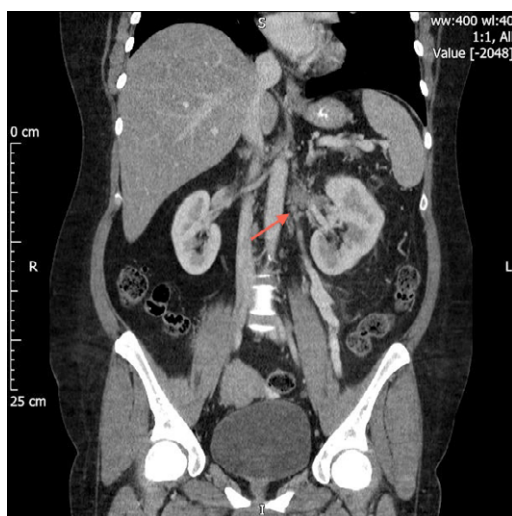


Figure 1: Coronal Section of CT abdomen and pelvis revealing thrombus within the left renal vein (indicated by the red arrow).

***Corresponding author:** A Talwar, Milton Keynes Hospital, NHS Foundation Trust, UK, E-mail: ambitalwar@googlemail.com

Received May 23, 2014; **Accepted** September 05, 2014; **Published** September 15, 2014

Citation: Talwar A, Kavidasan A, Randhawa R, Bhattacharya M, Somani V, et al. (2014) Acute Pyelonephritis: The clot unfolds. J Clin Case Rep 4: 381. doi:10.4172/2165-7920.1000381

Copyright: © 2014 Talwar A, et al. This is an open-access article distributed under the terms of the Creative Commons Attribution License, which permits unrestricted use, distribution, and reproduction in any medium, provided the original author and source are credited.

The gold standard diagnostic test is renal venography. However less invasive imaging is increasingly being used such as spiral Computed Tomography (CT) with contrast, magnetic resonance imaging (MRI) and Doppler ultrasonography [3]. The choice of test is dependent upon the institutional expertise.

The mainstay treatment of RVT focuses on managing the cause initially alongside anticoagulation.

The indicators for thrombolysis in the setting of acute RVT are unclear. No data are available comparing thrombolytic therapy with anticoagulation [4]. Surgical treatment is now rarely used. It may be required in the case of acute bilateral RVT and acute renal failure. In cases of invasion by tumour, radical nephrectomy may be warranted. In the case of RVT complicating pyelonephritis, the duration of antibiotic therapy does not need to be extended unless there is suspicion of an infected thrombus [5,6].

Conclusion

Renal vein thrombosis and acute pyelonephritis can have similar presentations.

1. When a patient is diagnosed with thrombosis, think about the possible cause.

2. Duration of antibiotic therapy is based on the individual patients' response.
3. Treatment involves anticoagulation therapy, though the duration of treatment is dependent on the precipitating cause and patient adherence to treatment.

Thrombolysis and surgical treatment is rarely indicated.

References

1. Kearon C, Julian JA, Kovacs MJ, Anderson DR, Wells P, et al. (2008) Influence of thrombophilia on risk of recurrent venous thromboembolism while on warfarin: results from a randomized trial. *Blood* 112: 4432-4436.
2. Llach F, Papper S, Massry SG (1980) The clinical spectrum of renal vein thrombosis: acute and chronic. *Am J Med* 69: 819-827.
3. Lam KK, Lui CC (1998) Successful treatment of acute inferior vena cava and unilateral renal vein thrombosis by local infusion of recombinant tissue plasminogen activator. *Am J Kidney Dis* 32: 1075-1079.
4. Bassilios N, Tassart M, Restoux A, Bigot JM, Rondeau E, et al. (2004) Inferior vena cava thrombosis due to acute pyelonephritis. *Nephrol Dial Transplant* 19: 981-983.
5. Avasthi PS, Greene ER, Scholler C, Fowler CR (1983) Noninvasive diagnosis of renal vein thrombosis by ultrasonic echo-Doppler flowmetry. *Kidney Int* 23: 882-887.
6. McCarthy E, Mahony NO, Guiney M, Ryan JM (2011) Successful catheter directed thrombolysis of IVC and renal vein occlusive thrombus. *Ir Med J* 104: 311-312.