

Acute Myocardial Infarction in a Young Female with Elevated Lipoprotein (a) and a Secundum Atrial Septal Defect

Matthew Schmidt, Timothy E Paterick*

Aurora Health Care, Green Bay, Wisconsin, USA

Abstract

Paradoxical coronary artery embolism and spontaneous coronary artery dissection are rare causes of acute myocardial infarction in young females. These unusual etiologies for myocardial infarction should be considered in young female patients presenting with chest pain and at a low risk profile, by Bayesian analysis, for coronary atherosclerosis.

We present a case of a 21-year-old female of a paradoxical embolism causing ST elevation myocardial infarction in a patient with markedly elevated Lipoprotein (a) levels and an atrial septal defect. Chest pain, abnormal ECG, and elevated troponins led to coronary angiography demonstrating a clot in the obtuse marginal branch of the circumflex coronary artery. Echocardiography revealed an unknown atrial septal defect with bidirectional shunting. The question we address is whether closure of the atrial septal defect is appropriate to prevent a recurrence of a paradoxical embolism.

Keywords: Atrial septal defect; Lipoprotein (a); Paradoxical embolism; Myocardial infarction; Coronary Artery thrombus; Atrial septal defect closure; Anticoagulation

Introduction

Coronary artery embolism is an established cause of acute coronary syndrome, but paradoxical coronary artery embolism is rare [1], but should be given careful consideration when young people present with an acute coronary syndrome. The diagnosis of paradoxical embolism requires collaboration between the interventionalist and echocardiographer.

Paradoxical embolisms are blood clots that originate in the systemic venous circulation and enter the arterial circulation through a connection via an intracardiac shunt. Recognition is extremely important because of the risk of future embolic phenomena. The risk is increased when patients have a family history, personal history, or risk factors such as Factor V Leiden genotype, MTHFR genotype, Protein C, Protein S, antithrombin 3 A, antithrombin 3 AG deficiency and elevated Lipoprotein (a). These risk factors promote venous thromboembolism and the potential for paradoxical shunting in predisposed patients.

Case Report

21-year-old female presented with acute chest pain syndrome described as chest heaviness and bilateral arm numbness with associated shortness of breath. She also felt hot and nauseous. Pain level was 8/10. Pertinent history included she was taking oral contraceptives. Her mother had a cryptogenic stroke during pregnancy and died two months previously of a pulmonary embolism post knee surgery.

Upon initial evaluation the blood pressure was 110/60 and the heart rate was 60 beats per minute. Cardiac examination was normal. The ECG revealed ST elevation in 2,3, AVF and V 4, 5,6 (Figure 1) Drug screen was negative. Troponin was elevated at 3.35 ng/ml (< 0.05 ng/ml). Emergent CT scan revealed no pulmonary embolism or aortic dissection.

The patient went to urgent cardiac catheterization. The catheterization revealed a small thrombus in a small obtuse marginal

branch of the circumflex coronary artery (Figure 2). The remaining arteries were normal.

The patient was treated with intravenous heparin and started on Plavix 75 mg per day. Symptoms of chest pain persisted over the next six hours and were rated at 3/10. The next day the troponin was 62.5 ng/ml and the ECG revealed an infero-lateral infarct (Figure 3).

Day three the troponin was 25.25 ng/ml. The patient's symptoms had resolved. An echocardiogram on day three post STEMI revealed an infero-lateral infarct and a bi-directional atrial septal communication (Figures 4 and 5).

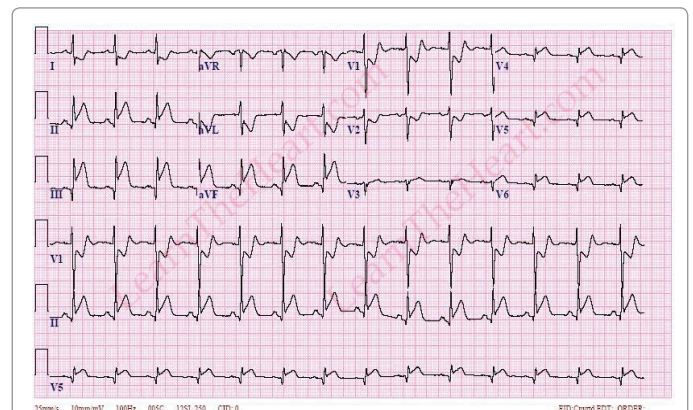


Figure 1: Inferior and lateral ST EMI with elevated ST segments in 2, 3, aVF, V 4, 5,6.

*Corresponding author: Timothy E Paterick, Aurora Health Care, Green Bay, Wisconsin, USA, Tel: 904-476-4233; E-mail: tpaterick@gmail.com

Received June 12, 2018; Accepted June 18, 2018; Published June 25, 2018

Citation: Schmidt M, Paterick TE (2018) Acute Myocardial Infarction in a Young Female. J Coron Heart Dis 2: 106

Copyright: © 2018 Schmidt M, et al. This is an open-access article distributed under the terms of the Creative Commons Attribution License, which permits unrestricted use, distribution, and reproduction in any medium, provided the original author and source are credited.

Blood work revealed that fibrinogen was elevated two times normal. Protein C, Protein S, plasminogen, antithrombin 3A, antithrombin 3 AG was normal. Subsequent genetic testing revealed Factor 5 Leiden genotype was negative as was the MTHFR gene. Lipid profile revealed that Lipoprotein (a) was 127 mg/dL (0-40 mg/dL)

The patient was discharged home free of symptoms on Plavix 75 mg per day, aspirin 81 mg per day, Niacin and Fenofibrate. The patient was brought back in four weeks for a transesophageal echocardiogram

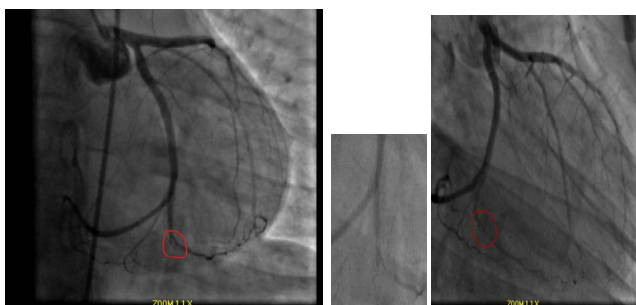


Figure 2: A. Thrombus in a branch vessel of the obtuse marginal. B. Magnified view. C. Thrombus in marginal branch.

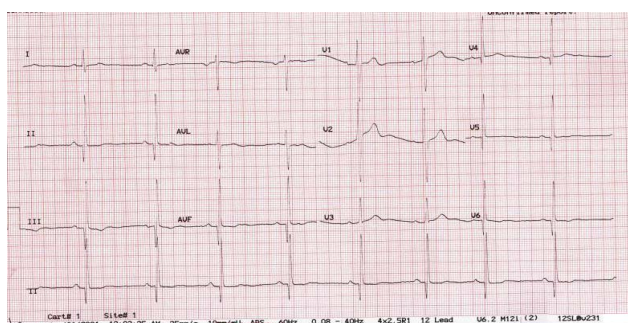


Figure 3: ECG with Q waves in 2,3 aVF, V5, 6 consistent with infero-lateral infarct.

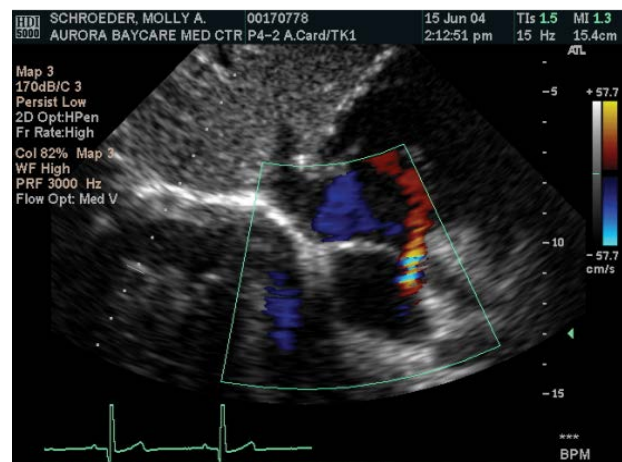


Figure 4: Color flow Doppler revealing a left to right shunt.

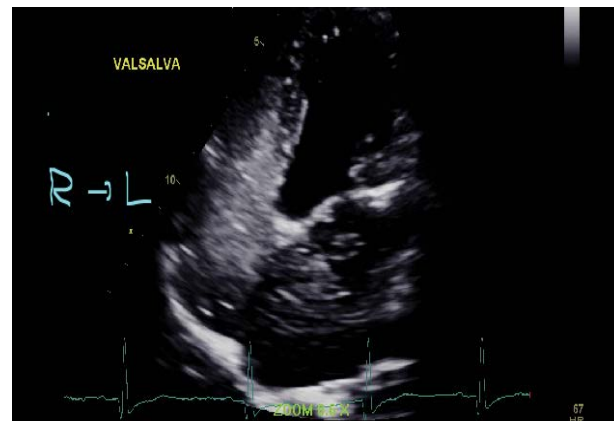

Figure 5: Bubble study revealing right to left shunt.

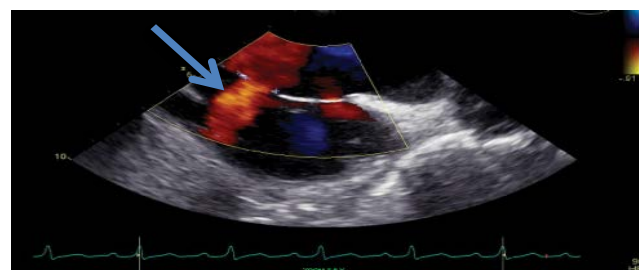

Figure 6: Left to right shunt.

to further evaluate the interatrial septal defects and the feasibility using a closure device to prevent future paradoxical embolism. The TEE revealed an inter-atrial shunt (Figure 6).

Discussion

The question posed is whether to close a communication in the setting of a proven paradoxical embolism. The randomized trials that have assessed therapeutic interventions for paradoxical embolism have not produced any clear guidelines as to how to best treat these complex conditions. The patients are at risk for pulmonary emboli, stroke and myocardial infarction. There has been a long history of uncertainty regarding the best approach to patients with an interatrial communication and a paradoxical embolism causing end-organ damage dating from the 1951 to the present day [2-7].

This patient was unique in that she had experienced an inferolateral myocardial infarction in the setting of an atrial septal defect and her mother had experienced a cryptogenic stroke during her first pregnancy and died of a pulmonary embolism post knee surgery. The patient's Lipoprotein (a) level was elevated three times normal and elevated Lipoprotein (a) levels are associated with an increased risk of thrombosis in young patients [8-10].

An in-depth discussion with the patient detailed the risks of future thrombosis with potential for pulmonary embolism, stroke, and recurrent myocardial infarction. The risks of catheter closure of a secundum atrial septal defect were discussed. The options of long-term anticoagulation with and without device closure of the interatrial septal defect were discussed. We explained that percutaneous device closure had not been systematically studied in paradoxical coronary embolism.

The patient's inter-atrial communication had not created any morphologic or physiologic affect as right ventricular size and function remained normal. The closure of the inter-atrial defect would not impact the development of venous clots and the potential associated adverse effects. The ultimate management decision made between the patient, cardiologist and interventional team was treatment with a novel oral anticoagulant and continued clinical surveillance. This approach would limit the potential for venous thrombosis and therefore venous or arterial embolization.

References

1. Kieber FX, Hauschild T, Schulz M, Winkelman A, Bruch L (2017) Myocardial Infarction Caused by Presumes Paradoxical Embolism via Patent Foramen Ovale. *Circ J* 81: 1484-1489.
2. Epidemiology of Johnson Bi. Paradoxical embolism. *J Clin Pathol* 4: 316 -32.
3. Carroll JD, Saver JL Thaler (2013) Closure of Patent Foramen Ovale After Cryptogenic Stroke. *NEJM*. 368: 1092-10100.
4. Seiler C (2015) Patent Foramen Ovale: Is There Life Before Death in the Presence of PFO? *Eur J Clin Invest* 45: 875-82.
5. Maron BA, Shekar PS, Goldhaber SZ (2010) Paradoxical embolism. *Circulation*. 122: 1968 -1972.
6. Zanchetta M, Rigatelli G, Pedon L, Zennaro M, Carrozza A , et al. (2005) Catheter closure of perforated secundum atrial septal defect under intaocardiac echocardiographic guidance using a single amplatz device: feasibility of a new method. *J Invasive Cardiology*. 17: 262-65.
7. Bartel T, Muller S (2013) Contemporary echocardiographic guiding tools for device closure of interatrial communications. *Cardiovascular DiagnTher*. 3: 38-46.
8. Sandkamp M, Funke H, Schulte H, Assman G (1990) Lipoprotein (a) is an independent risk factor for myocardial infarction in young age. *Clin Chem* 36: 20-123.
9. Nagayama M, Shinohara Y, Nagayama T (1994) Lipoprotein (a) and ischemic cerebrovascular disease in young adults. *Stroke* 25: 74-78.
10. von Depka M, Nowak-Göttl U, Eisert R, Dieterich C, Barthels M, et al. (2000) Increased lipoprotein (a) levels as an independent factor for venous thromboembolism. *Blood*. 96: 3364-3368.