

Acute Left-sided Foot Drop Attributed to Recurrent Synovial Chondromatosis of the Lumbar Spine

Azedine Medhkour*, Pouya Entezami and Cara Gatto-Weis

University of Toledo Medical Center, Toledo, OH, USA

Abstract

Objective: To discuss an uncommon case of nerve root compression caused by synovial chondromatosis of the lumbar spine.

Summary of background: Synovial chondromatosis is an uncommon, benign monoarthritic condition of the synovial lining of large joints of the body. It is considered a metaplastic process rather than a neoplastic one, in which nodules are formed from aggregates of chondrocytes in the synovium. The nodules cause non-specific symptoms such as pain and decreased range of motion in the affected joint. In rare instances, synovial chondromatosis has been known to involve the spine, with associated radiculopathy. We report a case of synovial chondromatosis of the lumbar spine, which to our knowledge is the first case with foot drop.

Case presentation: A 58-year-old woman presented with symptoms of lower back pain with unilateral radiation, numbness, and tingling. After primary resection of an extradural cartilaginous mass in the region of L4-L5, her symptoms remitted. One year post-operatively, she experienced a progressive recurrence of her symptoms and the acute onset of foot drop. Re-excision provided partial symptomatic relief. Histopathology showed nodular aggregates of benign cartilage, consistent with synovial chondromatosis.

Conclusion: Synovial chondromatosis of the spine is a rare but potentially challenging problem for both patients and clinicians. Due to the broad clinical presentation and vague imaging profile, preoperative diagnosis is difficult. The histopathologic findings must be correlated clinically to arrive at the correct diagnosis. Surgical removal may resolve the symptoms, though recurrence requiring re-excision is not uncommon. This is the fourth reported case of synovial chondromatosis involving the lumbar spine, and the first with recurrence resulting in an exacerbation of prior symptoms including foot drop.

Keywords: Synovial chondromatosis; Foot drop; Lumbar radiculopathy

Key Points

Synovial chondromatosis of the lumbar spine is an uncommon cause of low back pain, and may be accompanied by radiculopathy.

Synovial chondromatosis is considered a benign metaplastic process rather than a neoplastic one, in which nodules are formed from aggregates of chondrocytes in the synovium. These nodules are the etiology of the patient's symptoms.

Though excision is considered curative, reoccurrence is not uncommon.

Due to the broad clinical presentation and vague imaging profile, preoperative diagnosis of synovial chondromatosis is difficult.

Introduction

Synovial chondromatosis is an uncommon, monoarthritic disease of the synovial lining of large joints [1-4]. It is characterized by benign metaplasia resulting in multiple cartilaginous nodules in the synovium. These can progress to become calcified nodules, which can extend into soft tissues or adjacent bone, or break off and float freely in the joint space [1,4-8]. Histologically, synovial chondromatosis is illustrated by discrete clusters of chondrocytes [5,6,8-10]. Clinical symptoms range from pain and swelling at the affected joint to limited range of motion and radiculopathy. Surgical management involves excision of all lesions and removal of any loose bodies [4,5,7,8]. Though recurrence is not uncommon [9]. Including this current description, there are fourteen cases of spinal synovial chondromatosis reported in the literature, only four of which involve the lumbar spine [1,3-13].

Case Report

A 58-year-old woman with morbid obesity (BMI 38.4), pre-

hypertension, and osteoarthritis presented with six months of lower back pain with unilateral radiation down her left leg, with associated numbness and tingling. She underwent a L4-L5 laminectomy and microforaminotomy performed at another institution intended to treat a herniated disc; when the surgeon discovered a mass lesion she was referred to us. Neurologic examination revealed severe sharp pain on palpation in the lumbar region, exacerbated by movement. MRI of the lumbar spine showed a loss of disc height at L2-L3, L3-L4, and L4-L5 due to disc degeneration. Additionally, a soft tissue mass measuring 2 cm by 3 cm was appreciated posterior to the L4-L5 disc in the left lateral recess with inhomogeneous contrast enhancement periphery (Figure 1).

A posterior approach with a midline incision from L3-S1 was used. Revision laminectomy was carried out bilaterally at L4-L5. Bilateral microforaminotomy at the same level exposed a large extradural mass on the left, thought at the time to be a disc extrusion. All visible components of the mass were resected with microsurgical technique. Multiple additional fragments were found along the L4 and L5 vertebral bodies, which were removed as well.

The patient reported slight improvement in pain with some remittance of associated symptoms. Subsequent follow-ups showed

***Corresponding author:** Azedine Medhkour, MD, FAANS, FACS, University of Toledo Medical Center, Toledo, OH, USA, Tel: (419) 383-3547; Fax: (419) 383-6570; E-mail: azedine.medhkour@utoledo.edu

Received January 23, 2015; Accepted May 11, 2015; Published May 15, 2015

Citation: Medhkour A, Entezami P, Gatto-Weis C (2015) Acute Left-sided Foot Drop Attributed to Recurrent Synovial Chondromatosis of the Lumbar Spine. J Spine 4: 230. doi:10.4172/21657939.1000230

Copyright: © 2015 Medhkour A, et al. This is an open-access article distributed under the terms of the Creative Commons Attribution License, which permits unrestricted use, distribution, and reproduction in any medium, provided the original author and source are credited.

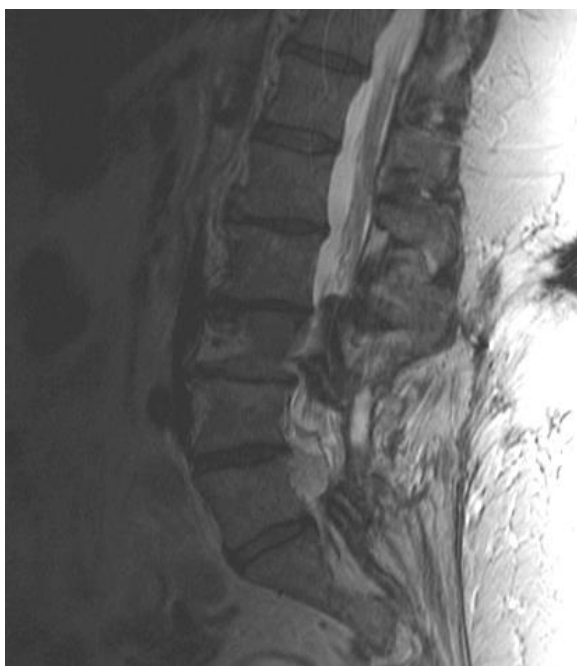

Figure 1: L4-L5 disc in the left lateral recess with inhomogeneous contrast enhancement periphery.

strong functional recovery. However, she presented 10 months post-operatively with a recurrence of her symptoms and acute onset of foot-drop. She was taken back to the operating room, where a mass was found compressing on the L5 nerve root on the left. The nerve root – which was under severe pressure (Figure 2a) – was decompressed and the remaining visible mass was again excised (Figure 2b). Once more, the mass was composed of a cartilaginous material dissimilar to an intervertebral disc. The patient again had some pain relief and her function progressively improved with post-surgical therapy, except for the foot drop which persisted.

Histopathology

Gross examination following the initial operation revealed a soft-tissue mass measuring $2.0 \times 1.8 \times 0.5$ cm, composed of fragments of cartilage morphologically distinct from the nucleus pulposus of the adjacent intervertebral discs. Histologic examination revealed nodular aggregates of benign-appearing cartilage, with no evidence of neoplasia (Figure 3a and 3b). Revision surgery procured a sample with similar findings. These findings are consistent with the diagnosis of synovial chondromatosis.

Discussion

Preoperative diagnosis of synovial chondromatosis is exceedingly difficult due to the nondescript clinical presentation and vague imaging profile [5-7,9]. Thus, accurate diagnosis is often made postoperatively. Regardless, current treatment parameters involve complete resection of the mass and removal of all fragments, [4,5,7,8]. so an accurate preoperative diagnosis is not entirely necessary.

Despite the excision of all visible tumor material during the index operation, we believe that retained fragments hidden from view may have contributed to the recurrence of the mass. During her second surgery, the surgeon removed the mass but did not fuse initially with

hope that this could be the final treatment since the resection was total. Retrospectively, it would have been more appropriate to fuse after the first decompression and the mass resection, as well as perform a facetectomy.

We strongly suggest an aggressive surgical approach, with the intention of removing all visible evidence of disease as well as thorough investigation for occult extensions of metaplastic material. As with all compressive lesions of the spine it is important to comprehensively rule out neoplasia as the cause, as a missed diagnosis can be devastating. Malignant disease such as chondrosarcoma must be considered as part of the differential, as well as soft-tissue chondromas of the spine, tumoral calcinosis, and degenerative joint diseases [8,9].

Fourteen cases of vertebral synovial chondromatosis have been reported, including seven instances involving the cervical vertebrae (50%), two of the thoracic (14%), one at the first costovertebral joint (7%), and four of the lumbar spine including this report (29%) [1,3-13]. A comparison of the cases involving the lumbar spine can be found in Table 1.

Conclusion

Synovial chondromatosis of the lumbar spine is a rare and challenging issue for the spinal surgeon. The combination of potentially debilitating presentations and its inherent diagnostic difficulty makes this condition a necessary addition the differential diagnosis of back pain with nerve root involvement. Fortunately, surgical removal often

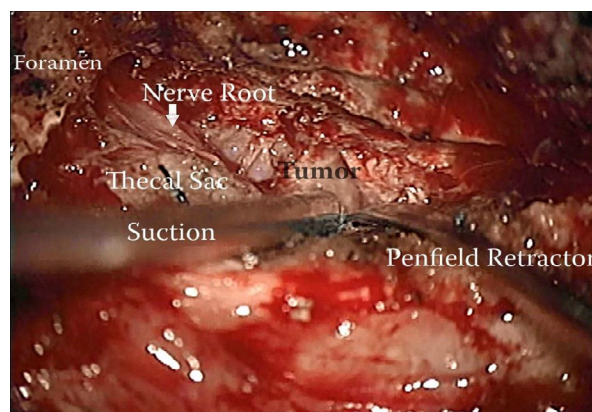


Figure 2a: Nerve root under severe pressure.

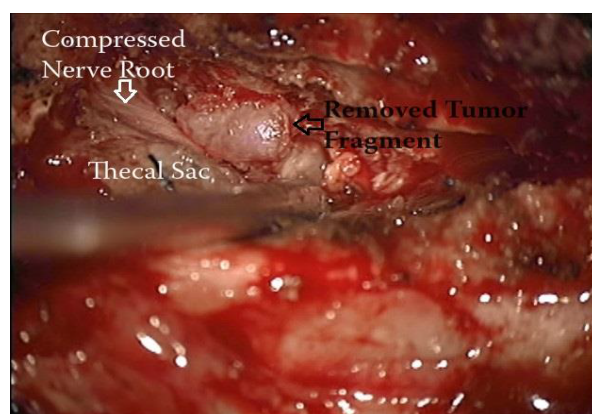


Figure 2b: Nerve root decompressed and the remaining visible mass was again excised.

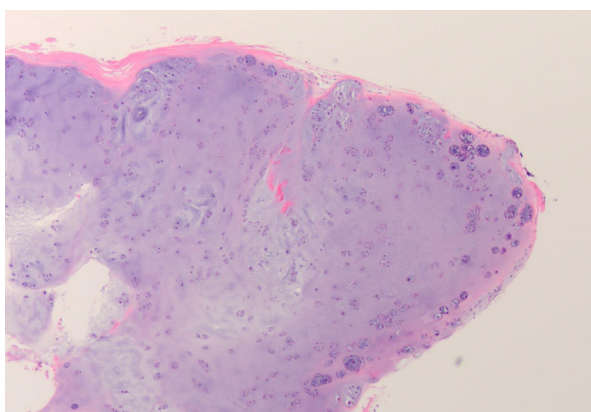


Figure 3a: Histologic examination of nodular aggregates of benign-appearing cartilage.

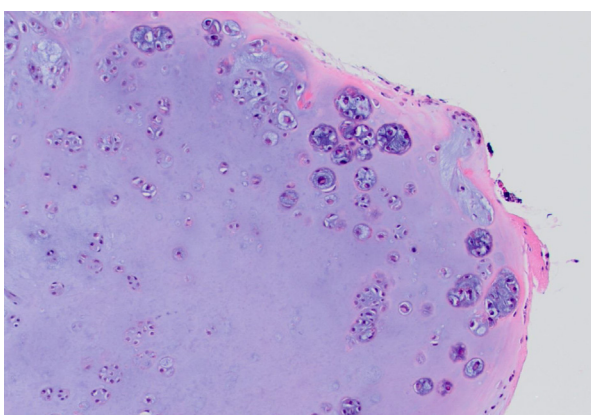


Figure 3b: Histologic examination of nodular aggregates of benign-appearing cartilage.

leads to symptomatic improvement, though recurrence requiring re-excision is not uncommon. Due to the limited number of reported case in the literature, many conclusions about vertebral synovial chondromatosis are inferred based on extraspinal variants.

References

- Kim SW, Choi JH (2009) Synovial chondromatosis presenting with lumbar radiculopathy. *Spine (Phila Pa 1976)* 34: E414-417.
- Murphey MD, Vidal JA, Fanburg-Smith JC, Gajewski DA (2007) Imaging of synovial chondromatosis with radiologic-pathologic correlation. *Radiographics* 27: 1465-1488.
- Burrafato V, Campanacci DA, Franchi A, Capanna R (1998) Synovial chondromatosis in a lumbar apophyseal joint. *Skeletal Radiol* 27: 385-387.
- Coscia MF, Edmonson AS, Pitcock JA (1986) Paravertebral synovial osteochondromatosis. A case report. *Spine (Phila Pa 1976)* 11: 82-87.
- Gallia GL, Weiss N, Campbell JN, McCarthy EF, Tufaro AP, et al. (2004) Vertebral synovial chondromatosis. Report of two cases and review of the literature. *J Neurosurg Spine* 1: 211-218.
- Abdelwahab IF, Contractor D, Bianchi S, Hermann G, Hoch B (2008) Synovial chondromatosis of the lumbar spine with compressive myelopathy: a case report with review of the literature. *Skeletal Radiol* 37: 863-867.
- Chiba S, Koge N, Oda M, Yamauchi R, Imai T, et al. (2003) Synovial chondromatosis presenting with cervical radiculopathy: a case report. *Spine (Phila Pa 1976)* 28: E396-400.
- Kyriakos M, Totty WG, Riew KD (2000) Synovial chondromatosis in a facet joint of a cervical vertebra. *Spine (Phila Pa 1976)* 25: 635-640.
- Moody P, Bui MM, Vrionis F, Setzer M, Rojani AM (2010) Synovial chondromatosis of spine: case report and review of the literature. *Ann Clin Lab Sci* 40: 71-74.
- Milchgrub S, Mulhollan T, Vuitch MF, Wheatherall PT (1992) Case report 692: Synovial chondrometaplasia of the 1st costovertebral joint. *Skeletal Radiol* 21: 45-48.
- Birchall D, Khangure MS, Spagnolo DV (1999) Vertebral synovial osteochondromatosis with compressive myelopathy. *Spine (Phila Pa 1976)* 24: 921-923.
- Greenlee JD, Ghodsi A, Baumbach GL, VanGilder JC (2002) Synovial chondromatosis of the cervical spine. Case illustration. *J Neurosurg* 97: 150.
- Shaw A, Zibly Z, Prasad V, Ikeda D, Boue D, et al. (2014) Synovial chondromatosis of the cervical spine: a case report and review of the literature. *Pediatr Dev Pathol* 17: 221-225.

Authors and Year	Age and Sex	Disease Location	Symptoms
Burrafato et al. 1998 [3]	31 F	Right L4-L5 facet	<ul style="list-style-type: none"> Painful, progressively growing mass under paravertebral area of the lumbar spine, with radiation down ipsilateral leg Multiple loose bodies
Abdelwahab et al. 2008 [6]	41 M	Left spinal canal, below L4-L5	<ul style="list-style-type: none"> Left buttock, low back, and leg pain, with radiation down to ipsilateral large toe Weak dorsiflexion in foot and large toe Atrophy of left calf No loose bodies
Kim et al. 2009 [1]	24 F	Right L5-S1	<ul style="list-style-type: none"> Low back pain and right-sided sciatica History of multiple falls No loose bodies
Current case 2014	58 F	Left L4-L5	<ul style="list-style-type: none"> Low back pain with ipsilateral radiation, with numbness and tingling Recurrence of symptoms with acute onset foot-drop Multiple loose bodies

Table 1: Cases of synovial chondromatosis involving the lumbar spine.