

## About a Gastric Neuroendocrine Tumor Presenting as Polymyalgia Rheumatica and Macrocytic Anemia

Ciro Manzo\*

Asl Napoli 3 Sud, Mariano Lauro hospital, Sant'Agnello, Naples, Italy

### Abstract

Polymyalgia rheumatica (PMR) is considered the commonest rheumatic inflammatory disease in the elderly. The relationship between PMR and cancer is still complex. The possibility that PMR can represent a paraneoplastic syndrome has been more and more described. A lack of response to corticosteroid therapy is considered the principal element for looking for a paraneoplastic syndrome. Gastric gastrin-secreting tumor represents an uncommon gastric tumor, especially in the elderly. We describe the clinical case of a patient in which PMR associated with a mild macrocytic anemia was the key for diagnosis of a gastric gastrin-secreting tumor. Endoscopic removal of neoplastic polyps and an octreotide long-lasting therapy caused the prompt and permanent disappearance of PMR manifestations. According to our knowledge, it's the first time that this association is described.

**Keywords:** Polymyalgia rheumatica; Paraneoplastic syndrome; Gastric neuroendocrine tumor; Gastric gastrin-secreting tumor; Elderly patient

### Introduction

Polymyalgia rheumatica (PMR) is considered the commonest inflammatory rheumatological disease in adults aged  $\geq 50$  years [1,2]. Classic symptoms are bilateral pain, aching and stiffness in the shoulders and pelvic girdle, usually accompanied by raised inflammatory markers. As opposed to the symptoms of osteoarthritis, the stiffness and pain tend to be bilateral or symmetric and improve with activity. Constitutional symptoms such as fatigue, malaise, anorexia, weight loss and fever are also common. There are many reports of PMR in association with tumors, in some cases as a paraneoplastic syndrome [3,4]. Neuroendocrine tumors (NETs) represent uncommon tumors arising from the excessive proliferation of enterochromaffin-like (ECL) cells (so-called Kulchitsky cells). Gastric NETs (GNET) represent less than 2% of all NETs and less than 1% of all stomach neoplasms. In particular, gastric NETs type 1 (associated to chronic atrophic gastritis and hypergastrinaemia) is the more frequent one, accounting for 70-80% of all GNET [5]. The association between PMR and GNET has never been described.

### Case Report

FG is a 67-years-old man who in January of 2015 suddenly complained bilateral pain, aching and stiffness in the shoulders and pelvic girdle determining serious functional impairment and need to be helped by relatives (for example in undressing or in getting out of bed). No other joint was involved. Until then, he was in excellent health and was under no medication. Laboratory analyses showed an increase of erythrocyte sedimentation rate (ESR)=60 mm/h and of C-reactive protein (CRP)=72 *vs* <6 mg/dl associated with a mild macrocytic anemia (haemoglobin [Hb]=11.1 gr/dl *vs* >14; mean corpuscular volume (MCV)=105 *vs* <95 fl). Normal were rheumatoid factor, anti-cyclic citrullinated peptide antibodies, glucose; liver, renal and thyroid function tests; dipstick urinalysis, protein electrophoresis, antinuclear antibodies, prostatic specific antigen. An US examination showed presence of subdeltoid bursitis and biceps tenosynovitis in shoulders and of trochanteric bursitis at left hip. PMR was diagnosed and he started therapy with prednisone 10 mg/die plus folic acid (5 mg/day, orally). He had a very modest improvement in symptoms. So, after ten days a new laboratory control was made: CRP=12 mg/dl; ESR=48 mm/hour, MCV=105 fl. Prednisone dosage was increased in first time to 12.5 mg and then to 15 mg/day without efficacy. In

consideration of persistent macrocytic anemia, serum dosages of folic acid, B12 Vitamin, gastrin and anti- parietal gastric antibodies (APGA) were recommended : APGA=absent, gastrin >1000 pg/ml. A subsequent upper endoscopy revealed an erosive gastropathy and some sessile polyps located in body and fundus of the stomach (Figure 1a-1d). Histological examination showed the presence of a mild atrophic gastritis with a mild activity and absence of helicobacter pylori. Polyps biopsy revealed the presence of atypical cells having round-oval nucleus and granular eosinophilic cytoplasm, localized to mucosa and submucosa, positive for pancitocheratin, chromogranin and synaptophysin by immunohistochemistry (Figure 2). Ki proliferation index was equal to 10%. The data authorized the diagnosis of GNET type 1, G2 stage according to OMS classification [6,7]. An abdominal US evaluation was normal as well as a CT-total body. The polyps were endoscopically removed and the patient began therapy with octeotride (octeotride long acting repeatable, 10 mg intramuscular every four weeks) for six months in order to inhibit gastrin production and stop its proliferative stimulus on ECL cells. Pain in the shoulders and pelvic girdle and his functional abilities quickly improved as well as ESR, CRP and haemoglobin serum levels. Our patient recovered his total independence. He discontinued prednisone in a month without relapses of PMR manifestations. When octreotide was discontinued, no PMR relapse was observed. At present, he enjoys good health.

### Discussion

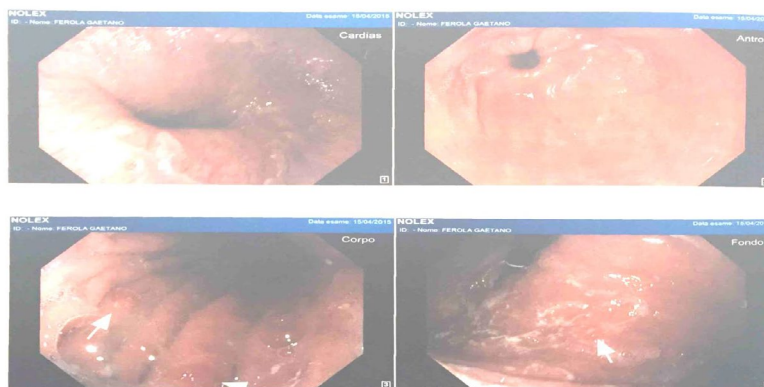
The relationship between PMR and neoplasia is still intricate. Several studies have evaluated this question. Two database studies have suggested increased risk of cancer particularly in the first year of diagnosis. A data-base study from Sweden included 35,928 patients with GCA and PMR but this utilized the Swedish Hospital Discharge Register. There was a marginal increase in the incidence of cancer compared with the general population (standardized incidence ratio

\*Corresponding author: [Ciro Manzo](mailto:Ciro.Manzo@libero.it), Asl Napoli 3 Sud, Mariano Lauro hospital, Sant'Agnello, Naples, Italy, Tel: 40632061439902; E-mail: [cirmanzo@libero.it](mailto:cirmanzo@libero.it)

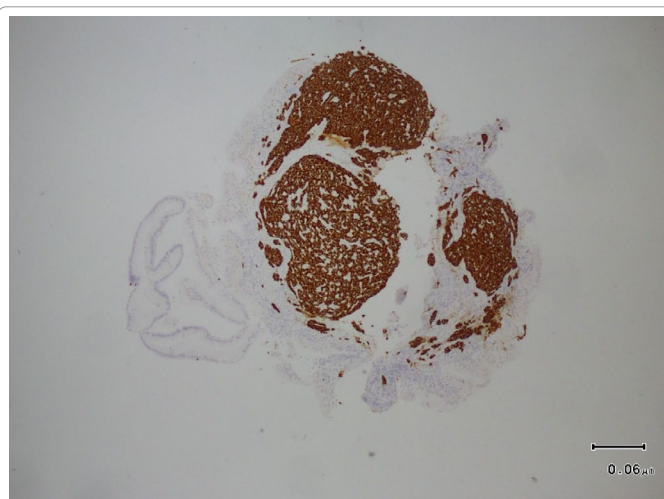
Received March 31, 2016; Accepted May 12, 2016; Published May 17, 2016

Citation: Manzo C (2016) About a Gastric Neuroendocrine Tumor Presenting as Polymyalgia Rheumatica and Macrocytic Anemia. J Clin Case Rep 6: 784. doi:10.4172/2165-7920.1000784

Copyright: © 2016 Manzo C. This is an open-access article distributed under the terms of the Creative Commons Attribution License, which permits unrestricted use, distribution, and reproduction in any medium, provided the original author and source are credited.



**Figure 1.** A subsequent upper endoscopy revealed an erosive gastropathy and some sessile polyps located in body and fundus of the stomach.



**Figure 2:** Polyps biopsy revealed the presence of atypical cells having round-oval nucleus and granular eosinophilic cytoplasm, localized to mucosa and submucosa, positive for pancytokeratin, chromogranin and synaptophysin by immunohistochemistry.

Scoring	Without US	With US
Morning stiffness lasting > 45 min	2	2
Hip pain or limited range of motion	1	1
Absence of rheumatoid factor or anticyclic citrullinated peptide	2	2
Absence of other joint involvement	1	1
US presence of subdeltoid bursitis or biceps tenosynovitis or glenohumeral synovitis in at least one shoulder, and at least one hip with synovitis or trochanteric bursitis	N/A	1
Subdeltoid bursitis, biceps tenosynovitis or glenohumeral synovitis on both shoulders on US	N/A	1

**Table 1.** In addition to clinical features, the use of ultrasonography of the shoulders and hips improved the criteria specificity for PMR

1.19; 95% confidence interval 1.06-1.23). However, when evaluating malignancy risk in the first year after diagnosis of PMR (or GCA), the standardized incidence ratio was 2.26 (95% confidence interval 2.10-2.42) [7]. Another study utilized the UK General Practice Research Database and evaluated cancer risk in 2877 patients with PMR compared with age- and sex-matched controls. Over a median follow

up of 7.8 years, 23.2% of patients with PMR developed cancer compared with 19.5% of controls. The risk of malignancy was increased in patients with PMR during the first 6 months after diagnosis (hazard ratio 1.69; 95% confidence interval 1.18-2.42) [8]. Cutaneous, lymphatic, hematopoietic, colic tumors were the more frequent.

Other studies have presented discordant conclusions [9,10]. The association of giant-cell arteritis (GCA) and its specific potential paraneoplastic potentiality, for example, represent one of the critical elements.

In 2012, collaborative efforts by the European league against rheumatism (EULAR) and the American college of rheumatology (ACR) have resulted in the publication of provisional classification criteria for PMR [11,12]. In addition to clinical features, the use of ultrasonography of the shoulders and hips improved the criteria specificity for PMR (Table 1). It should be noted that these are classification criteria (criteria to separate patients with PMR from a group of patients with conditions that mimic PMR) and are not diagnostic criteria.

Endoscopic treatments, such as endoscopic resection, are recommended as initial treatments for gastric NETs when the lesions are small (less than 1 cm in size) and there is no lymphovascular invasion [13,14]. However, there is another guideline that recommends annual surveillance for gastric NETs that are less than 1 cm in consideration of low risk of invasion or metastasis. This guideline also insists that surgery should be limited to cases involving invasion beyond the submucosa and metastases [15]. In our patient, endoscopic resection of the gastric polyps and therapy with octreotide induced quick, total and long-lasting improvement of PMR picture. The best described paraneoplastic syndromes are attributed to tumor secretion of functional peptides or hormones or immune cross-reactivity between tumor and normal host tissues. The relationship between PMR and GNET is still speculative.

Our case report highlights the importance of careful evaluation of patients presenting with polymyalgic symptoms to exclude other conditions, even if clinical, US and laboratory data are strongly in support of diagnosis of PMR [16]. In particular, the diagnostic widening of the mild macrocytic anemia as well as the poor response to corticosteroid therapy have been the keys for a right diagnosis and a correct therapy.

#### References

1. Dasgupta B, Borg FA, Hassan N (2010) BSR and BHPR guidelines for the management of polymyalgia rheumatica. *Rheumatology* 49: 186-190.
2. Manzo C, Balducci M, Cappiello F (2009) Epidemiology of polymyalgia

- reumatica in the Massa Lubrense town. Trends in Med 9: 101-105.
3. Keith MP, Gilliland WR (2006) Polymyalgia rheumatica and breast cancer. J Clin Rheumatol 12: 199-200.
  4. Anton E (2007) More on polymyalgia rheumatica (PMR) as a paraneoplastic rheumatic syndrome in the elderly (bicytopenia and PMR preceding acute myeloid leukemia). J Clin Rheumatol 13: 114.
  5. Rindi G, Luinetti O, Cornaggia M, Capella C, Solcia E (1993) Three subtypes of gastric argyrophil carcinoid and the gastric neuroendocrine carcinoma: a clinicopathologic study. Gastroenterology. Apr 104: 994-1006.
  6. Bosman FT (2010) World Health Organization Classification of Tumors. Pathology and genetics. Tumor of the digestive system. IARC press, Lyon.
  7. Ji J, Liu X, Sundquist K, Sundquist J, Hemminki K (2010) Cancer risk in patients hospitalized with polymyalgia rheumatica and giant cell arteritis: a follow-up study in Sweden. Rheumatology (Oxford) 49: 1158-1163.
  8. Muller S, Hider S, Belcher J, Helliwell T, Mallen C (2014) Is cancer associated with polymyalgia rheumatica? A cohort study in the General Practice Research Database. Ann Rheum Dis 73: 1769-1773.
  9. Haga HJ, Eide GE, Brun J, Johansen A, Langmark F (1993) Cancer in association with polymyalgia rheumatica and temporal arteritis. J Rheumatol 20: 1335-1339.
  10. Myklebust G, Wilsgaard T, Jacobsen BK, Gran JT (2002) No increased frequency of malignant neoplasms in polymyalgia rheumatica and temporal arteritis. A prospective longitudinal study of 398 cases and matched population controls. J Rheumatol 29: 2143-2147.
  11. Dasgupta, B, Cimmino M, Kremers H, Schmidt W, Schirmer M, Salvarani C, et al. (2012) 2012 Provisional classification criteria for polymyalgia rheumatica: a European League Against Rheumatism/ American College of Rheumatology collaborative initiative. Arthritis Rheum 64: 943-954.
  12. Dasgupta B, Cimmino M, Maradit-Kremers H, Schmidt W, Schirmer M, et al. (2012b) 2012 provisional classification criteria for polymyalgia rheumatica: a European League Against Rheumatism/American College of Rheumatology collaborative initiative. Ann Rheum Dis 71: 484-492.
  13. Crosby DA, Donohoe CL, Fitzgerald L, Muldoon C, Hayes B, et al. (2012) Gastric neuroendocrine tumours. Dig Surg 29: 331-348.
  14. Li TT, Qiu F, Qian ZR, Wan J, Qi XK, et al. (2014) Classification, clinicopathologic features and treatment of gastric neuroendocrine tumors. World J Gastroenterol 20: 118-125.
  15. Delle Fave G, Kwekkeboom DJ, Van Cutsem E, Rindi G, Kos-Kudla B, et al. (2012) ENETS Consensus Guidelines for the management of patients with gastroduodenal neoplasms., Neuroendocrinology 95: 74-87.
  16. Manzo C (2009) La polimialgia reumatica: cosa è utile sapere per il geriatra territoriale? Ger Extraosp 7: 9-11.