

A Young Gentleman with Pancytopenia and Microfilariasis: Report of the First Case in Qatar

Shireen Suliman^{2*}, Mehdi Errayes^{1,2}, Aliaa Amer^{1,3}, Omar Alseed^{1,2}, Amna Gameil^{1,4}, Maisa Bashir^{1,5} and Anil Ellahie^{1,4}

¹Hamad Medical Corporation, Qatar

²Internal medicine Department, Qatar

³Hematology Laboratory, Qatar

⁴Hematology Department, Qatar

⁵Infectious Diseases department, Qatar

Abstract

Filariasis is an endemic disease in many countries of Asia and Africa. It results in disfiguring lymphedema. A young gentleman presented with dizziness and found to have pancytopenia; an RBC count of $1.2 \times 10^6/\mu\text{l}$, Hemoglobin (Hb) of 3.6 g/dl, Total Leucocyte Count (TLC) of $3.9 \times 10^3/\mu\text{l}$ and platelet count of $7.0 \times 10^3/\mu\text{l}$. Examination of the peripheral smear, revealed the presence of microfilaria which was identified as *Wuchereria bancrofti* with the characteristic sheath and tail devoid of nuclei. Bone marrow revealed a picture of hypoplastic marrow with no evidence of microfilaria parasite. He was started on Ivermectin 9 mg stat dose and Doxycycline 100 mg orally twice daily. His hemoglobin became stable after transfusion and platelets continued to drop. The patient continued to receive platelets transfusion till he decided to travel back to his home country and lost follow up after that. This is one of the few case reports demonstrating the rare association of pancytopenia and microfilariasis and it adds to the previous reports that it raises the awareness of both the physicians and the laboratory staff to the occurrence of this important association in a non-endemic area.

Keywords: Microfilariasis; Pancytopenia; Aplastic bone marrow

Introduction

Filariasis is a common endemic parasitic infestation in Asia and Africa. It is a disease group affecting humans and animals, caused by filariae; ie, nematode parasites of the order Filariidae.¹ Although transmission is restricted to the tropics and subtropics, imported infections sometimes occur in Europe and North America among immigrants and refugees from endemic countries, and rarely among long-term travelers. Demonstration of the parasite in the peripheral smear of a patient with pancytopenia was reported in few case reports. This raised the association between pancytopenia and microfilariasis. This represents the first case to be reported in a non-endemic area. It raises the awareness of the both the physicians and the laboratory staff to that rare association in a non-endemic region.

Case Presentation

We present a 19 years old Nepalese gentleman who was previously healthy, newly arrived to Qatar eight months prior to his presentation. He presented with history of dizziness and fatigue and generalized weakness for one week prior to admission. Upon presentation, he was found to be sick, very pale, and febrile. There was no lymphadenopathy or hepatosplenomegaly. A full blood count was requested. The sample was processed by the hematology analyzer (Sysmex XE-5000, Siemens, Germany) and thin smears were prepared. The haemogram reflected pancytopenia with an RBC count of $1.2 \times 10^6/\mu\text{l}$, Hb of 3.6 g/dl, TLC of $3.9 \times 10^3/\mu\text{l}$ and platelet count of $7.0 \times 10^3/\mu\text{l}$. Examination of the peripheral smear, (Figure 1) revealed the presence of microfilaria which was identified as *Wuchereria bancrofti* with the characteristic sheath and tail devoid of nuclei. Bone marrow aspiration and biopsy were then attempted to resolve the cause of pancytopenia. This was however done 4 days after of initiation of anti-parasitic treatment. A total of 20 Wright-stained aspirate smears were examined but none could demonstrate microfilaria. Increased eosinophil precursors were noted. Bone marrow biopsy sections reflected markedly reduced cellularity to almost 5% with increased fat spaces and small islands of hemopoietic cells consisting mainly of lymphocytes, plasma cells and few residual granulocytic and erythroid precursors. Megakaryocytes

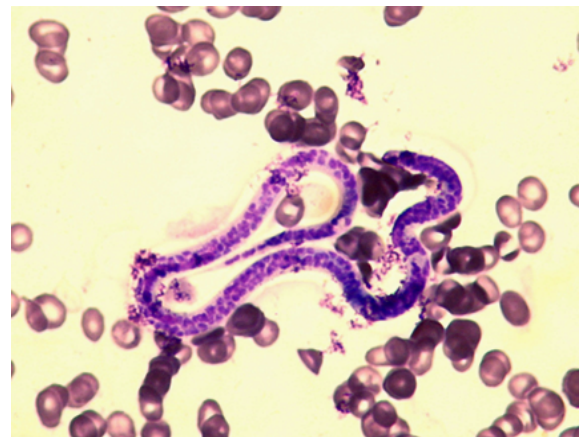


Figure 1: Peripheral smear showing microfilaria.

were absent. Blast cells were not increased. Accordingly, a diagnosis of hypoplastic marrow was made. Failure to demonstrate the parasite in marrow aspirates and the accompanied peripheral blood smears is probably related to earlier initiation of treatment. Coagulation profile, serum electrolytes, renal function, Vitamin B12 were normal. Blood culture and viral panel were negative. The patient was admitted with pancytopenia and Filariasis. He was started on packed red blood cells

*Corresponding author: Shireen Sulimann, Hamad Medical Corporation, Qatar, Tel: +974 44395777; E-mail: ssulima1@jhu.edu

Received September 11, 2015; Accepted November 06, 2015; Published November 13, 2015

Citation: Suliman S, Errayes M, Amer A, Alseed O, Gameil A, et al. (2015) A Young Gentleman with Pancytopenia and Microfilariasis: Report of the First Case in Qatar. J Clin Case Rep 5: 629. doi:10.4172/2165-7920.1000629

Copyright: © 2015 Suliman S, et al. This is an open-access article distributed under the terms of the Creative Commons Attribution License, which permits unrestricted use, distribution, and reproduction in any medium, provided the original author and source are credited.

and platelet transfusion. His symptoms improved dramatically. He was received on Ivermectin 9 mg stat dose and Doxycycline 100 mg po twice daily. His Hb became stable after transfusion and platelets continued to drop. He required platelets transfusion every 3 days in the day care. The case was managed by the medical, hematology and infectious diseases team. The patient decided to travel back to his home country and lost follow up thereafter.

Discussion

More than 150 million people, mainly in developing countries, are affected by filarial nematode infections that cause debilitating and disfiguring diseases. Although transmission is restricted to the tropics and subtropics, imported infections sometimes occur in Europe and North America among immigrants and refugees from endemic countries, and rarely among long-term travelers [1]. Of the hundreds of described filarial parasites, only 8 species cause natural infections in humans. More than 90 percent of these infections are due to *Wuchereria bancrofti*, while the remainders are due largely to *Brugia malayi*. In an interesting study the overall prevalence of lymphatic filariasis in Nepal from a 4,488-sample population was 13% and that 33/37 districts studied were found to be endemic [2].

Those who develop symptoms usually present with lymphatic obstruction resulting in lymphedema. The diagnosis of microfilaria in blood is commonly coincidental since in endemic areas, this may be completely asymptomatic. Diagnosis of filariasis includes demonstration of microfilaria in stained or unstained blood films, circulating filarial antigen detection and demonstration of organism in histopathological sections. Fluid cytology or Fine Needle Aspiration Cytology (FNAC) is rarely applied for routine diagnosis of clinically suspected filariasis. Rare presentation was demonstration of these parasites in some body fluids and tissues. The site of aspiration included one case each of thyroid, breast, bone marrow, cervical lymph node, and subcutaneous nodule [3]. One study showed the existence of *Microfilaria* in the pericardial effusion in a lady who presented with cardiac tamponade [4]. Microfilariasis had been also identified in bone marrow smears since 1976 [5]. Microfilariasis has been shown to be associated with many hematological malignancies like leukemia and lymphoma [6-8]. It has also been reported in association with various benign and malignant tumors [9]. Pancytopenia is the most common manifestation of bone marrow failure. It is a triad of decrease in the three cell lines: red blood cells, white blood cells, and platelets. There are many causes for pancytopenia and infection is a well-known cause. Few case reports have demonstrated the relation between microfilariasis and pancytopenia [10-13]. The etiology of marrow suppression in filariasis is unclear. It has been assumed that pancytopenia is the result of filarial infection mediated toxic depression of bone marrow [13].

Conclusion

There are few case reports demonstrating the association of filariasis with pancytopenia. However our case is the first to be reported in Qatar which is not an endemic area for Filariasis. Qatar is a multinational and

multicultural community with a population of 2,035,000. This case has raised the awareness of both the physicians and the laboratory staff of such a rare association in a non-endemic area. Accordingly, microfilaria has to be thought of in all patients originally from endemic areas who present with pancytopenia and treatment should be initiated once the parasite is demonstrated. Whether bone marrow hypoplasia will resolve on anti-parasitic treatment is not guaranteed and more intensive therapy must follow after exclusion of all possible underlying factors.

References

1. Knopp S, Steinmann P, Hatz C, Keiser J, Utzinger J (2012) Nematode infections: filariases. *Infect Dis Clin North Am* 26: 359-381.
2. Sherchand, Jeevan B (2015) "Mapping of Lymphatic Filariasis in Nepal." *Filaria Journal* 2: 7.
3. Gupta S, Gupta R, Bansal B, Singh S, Gupta K, et al. (2010) Significance of incidental detection of filariasis on aspiration smears: a case series. *Diagn Cytopathol* 38: 517-520.
4. Reddy GS, Balasundaram S (1977) Filarial pericardial effusion. *J Indian Med Assoc* 68: 125-126.
5. Pradhan S, Lahiri VL, Elhence BR, Singh KN (1976) *Microfilaria* of *Wuchereria bancrofti* in bone marrow smear. *Am J Trop Med Hyg* 25: 199-200.
6. Jain S, Sharma M, Jasmita Tyagi (2011) Common Parasite with Uncommon Associations. *Mediterranean Journal of hematology and Infectious Diseases* 3: e2011015.
7. Sharma P, Tyagi S (2010) An unusual cause of eosinophilia in AML-M4 without the Inv (16) abnormality. *J Blood Disord Transfus* 1: 104.
8. Arundhati, Kumar A, Kumar R (2011) Acute lymphoblastic leukaemia with microfilaria: a rare coincidence in bone marrow aspirate. *Indian J Hematol Blood Transfus* 27: 111-112.
9. Gupta S, Sodhani P, Jain S, Kumar N (2001) Microfilariae in association with neoplastic lesions: report of five cases. *Cytopathology* 12: 120-126.
10. Sharma S, Rawat A, Chowhan A (2006) Microfilariae in bone marrow aspiration smears, correlation with marrow hypoplasia: a report of six cases. *Indian J Pathol Microbiol* 49: 566-568.
11. Sinha D (2014) Filariasis presenting with Pancytopenia diagnosed by *Microfilaria* from Bone marrow aspirate: report of rare entity from India. *Int J Med Sci Public Health* 3: 638-639.
12. Umashankar T, Yaranal PJ (2012) Microfilariae in Bone Marrow Aspirates: Report of a Case. *J Clin Diagn Res* 6: 1294-1295.
13. Rajput R, Siwach SB, Singh S, Singh U, Meena (2002) Young male with pancytopenia: an unusual cause. *Postgrad Med J* 78: 300-30, 304-5.