

A Typical Penetrating Ocular Trauma – Case Report

Ricardo Luz Leitão Guerra¹, Igor Sandes Pessoa da Silva^{2,3}, Otacílio de Oliveira Maia Jr^{2,3} and Roberto Lorens Marback^{2,3}

¹Ophthalmologist at Clínica de Olhos Leitao Guerra, Salvador (BA), Brazil

²Ophthalmologist at Hospital Sao Rafael (Fundacao Monte Tabor), Salvador (BA), Brazil

³Retina and Vitreous service of the Hospital São Rafael - Monte Tabor Foundation, Salvador, Bahia, Brazil

Abstract

Purpose: Describing a case of an atypical ocular perforation by a daily use object, the treatment performed and the outcome after treatment. **METHOD:** Case report by reviewing medical data.

Case report: A twenty-five female that had an atypical penetrating ocular trauma evolving to a symptomatic peripheral vitreous traction, that was successful treated by pars plana 23 gauge vitrectomy.

Conclusion: Penetrating ocular trauma is an important cause of monocular blindness. Prompt diagnoses and treatment, are essential for the best possible prognoses

Keywords: Ocular trauma; Vitrectomy; Surgery; Trauma

Introduction

Despite all advances in medicine and technology employed in clinical practice, ocular trauma remains a risk of blindness and decreased vision. The injuries most frequently occurred in actively working people, and men are five times more affected than women [1,2].

About 30% of all eye injuries occurs in the domestic setting, and 'Do it yourself', car repairs and gardening have been shown to be a common cause of ocular trauma especially amongst males [3].

Wood, sharp objects and glass are the most common agents of penetrating ocular trauma [1,4,5].

The aim of this paper is to describe a case of an atypical ocular perforation by a daily use object, the treatment performed and the outcome after treatment.

Case Report

A twenty five years old female from Salvador was referred to the Retina and Vitreous service of the Hospital São Rafael - Monte Tabor Foundation - relating trauma with a head band (Figure 1) in the left eye fifteen days before. There was no relevant data on medical history and family.

Ophthalmologic examination revealed right eye best corrected visual acuity (BCVA) of 20/20, biomicroscopy, tonometry and funduscopy unchanged. The left eye BCVA was counting fingers at 2 meters, the biomicroscopy showed adherent leucoma in the central area of the cornea, corneal edema, and localized opacity of the lens (Figure 2).

Indirect ophthalmoscopy showed reduction in transparency due opaque media (cornea and lens), mild vitreous haze, optic disc and macula without modifications and, in extreme inferior temporal periphery there was the presence of increased turbidity of the vitreous, focal hemorrhage, and rounded hypochromic lesion (Figure 3). Penetrating trauma was diagnosed in the left eye extending from the cornea to the peripheral retina.

Expectant management was maintained using topical corticosteroids (prednisolone) four times a day. Upon her return thirty days after the initial evaluation, she complained of floaters and flashes. BCVA had improved to 20/100, there was no corneal edema, remained adherent leukoma, and there was an improvement in vitreous haze.



Figure 1: Head band.

Vitreous hemorrhage was slightly reduced and partially organized attached to the distal hypochromic lesion (Figure 4).

Twenty-three gauge sutureless pars plana vitrectomy was performed aiming to remove vitreous traction and endolaser was performed around peripheral lesions. Moxifloxacin and dexamethasone drops were used in the postoperation period.

On the thirtieth postoperative day the patient had no complaints and reported improvement in vision (BCVA was 20/40). The retina remained attached and endolaser scars surrounding retinal tears could be seen (Figure 5).

Discussion

Penetrating ocular trauma is an important cause of monocular

***Corresponding author:** Ricardo Luz Leitao Guerra, Ophthalmologist at Clínica de Olhos Leitao Guerra, Rua Catarina Paraguaçu n08, Graça, Salvador, Bahia CEP: 40150-200, Brazil, Tel: +557188228813; Fax: +557135256555; E-mail: ricardo@leitaoguerra.com.br

Received September 25, 2015; **Accepted** February 10, 2016; **Published** February 18, 2016

Citation: Guerra RLL, da Silva ISP, de Oliveira Maia Jr O, Marback RL (2016) A Typical Penetrating Ocular Trauma – Case Report. J Gen Pract 4: 234. doi: 10.4172/2329-9126.1000234

Copyright: © 2016 Guerra RLL, et al. This is an open-access article distributed under the terms of the Creative Commons Attribution License, which permits unrestricted use, distribution, and reproduction in any medium, provided the original author and source are credited.

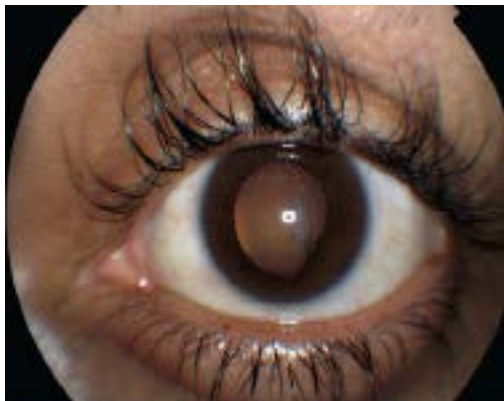

Figure 2: Left eye biomicroscopy showing adherent leucoma in the central area of the cornea.

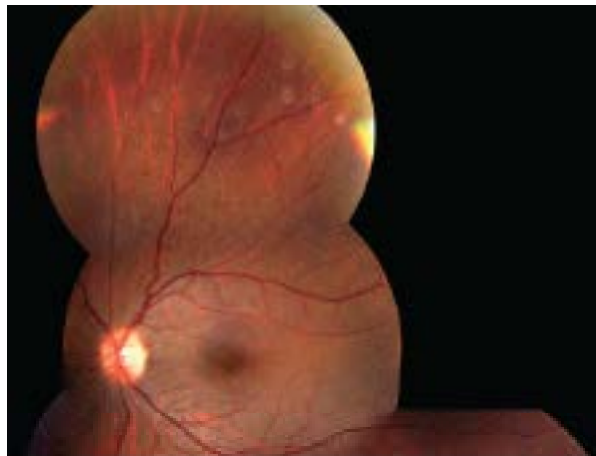

Figure 5: Final aspect of the patient: Two lesions in the inferior temporal at the extreme periphery surrounded by laser marks already pigmented.

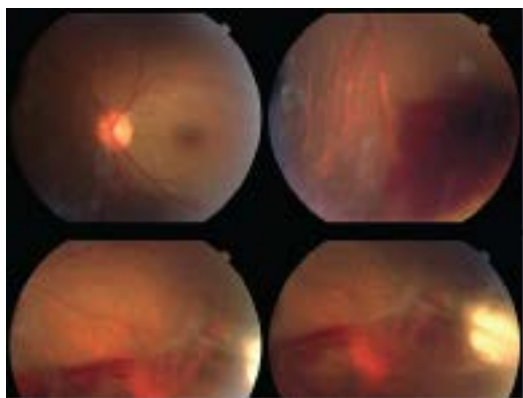


Figure 3: Initial evaluation: Focal hemorrhage and rounded hypochromic lesion inferior temporal at the extreme periphery.

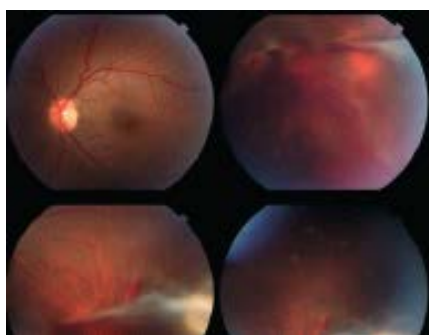


Figure 4: Thirty days after the initial evaluation: Slight reduction of hemorrhage and parcial viterous organization beam attached to the distal hypochromic lesion.

blindness. Prompt diagnoses and treatment, preferably within the first twenty-four hours, are essential for the best possible prognoses [1].

This kind of trauma occurs frequently in men, especially at work due the absence of protective eye equipment. At home, the children are the most affected. Pens, pencils, scissors and knives are common agents [4,5].

In the present case we describe a twenty-five female that had an atypical penetrating ocular trauma evolving to a symptomatic peripheral vitreous traction that was successful treated by pars plana 23 gauge vitrectomy.

References

1. Jovanovic M, Stefanovic I (2010) Mechanical injuries of the eye: incidence, structure and possibilities for prevention. *Vojnosanit Pregl* 67: 983-990.
2. Chattopadhyay SS, Mukhopadhyay U, Saurabh K (2010) An unusual case of penetrating ocular trauma with a pressure cooker. *Oman J Ophthalmol* 3: 89-90.
3. Khaw PT, Shah P, Elkington AR (2004) Injury to the eye. *BMJ* 3: 36-38.
4. Bhaduri G, Chattopadhyay SS, Ghosh RP, Saurabh K, Goyal M (2010) An unusual case of penetrating ocular trauma with metallic spoon. *Indian J Ophthalmol* 58: 330-331.
5. Fielden M, Hall R, Kherani F, Crichton A, Kherani A (2011) Ocular perforation by an acupuncture needle. *Can J Ophthalmol* 46: 94-95.