

A Striking Finding during Intraoperative Jugular Vein Sampling in a Case of Parathyroid Adenoma with Low-Normal Serum Intact Parathyroid Hormone Levels

Ilgin Yildirim Simsir^{1*}, Banu Pinar Sarer Yurekli¹, Hatice Ozisik¹, Murat Ozdemir², Mehmet Erdogan¹, Sevki Cetinkalp¹, Fusun Saygili L¹, Candeger Yilmaz¹, Yesim Ertan³, Ozer Makay² and Ahmet Gokhan¹

¹Endocrinology Department, Faculty of Medicine, Ege University, Turkey

²General Surgery Department, Faculty of Medicine, Ege University, Turkey

³Pathology Department, Faculty of Medicine, Ege University, Turkey

*Corresponding author: Ilgin Yildirim Simsir, Ege University Medical Faculty, Bornova, Izmir, Turkey, Tel: +90532 5126917; E-mail: ilginyildirim@hotmail.com

Rec date: Jun 06, 2016; Acc date: Jun 25, 2016; Pub date: Jun 30, 2016

Copyright: © 2016 Simsir IY, et al. This is an open-access article distributed under the terms of the Creative Commons Attribution License, which permits unrestricted use, distribution, and reproduction in any medium, provided the original author and source are credited.

Abstract

Aim: Primary hyperparathyroidism (PHP) is the most common cause of hypercalcemia based on outpatient clinic. The diagnosis of PHP is generally straightforward with high intact parathyroid hormone (iPTH) and hypercalcemia. But, PHP does not always exhibit those biochemical features. Less known phenotype of PHP is the hypercalcemia with normal level of iPTH. We report a case of parathyroid adenoma with low normal peripheral iPTH and high jugular PTH levels presenting as hypercalcemia. Our aim was to discuss the different mechanisms of such an entity with the guidance of the literature.

Case: A thirty-six year old woman who has type 2 diabetes mellitus was admitted to the hospital with the diagnosis of acute pancreatitis. On laboratory examination serum calcium and iPTH levels were as follows: 10.6, 10.7, 10.9 mg/dL and 28.8, 33.3, 31.7 pg/mL, respectively. Twenty-four hour calcium excretion was 403 mg/day; serum phosphor was 2.3 mg/dL. Based on the findings of hypercalcemia, hypercalciuria, positive sonographic and scintigraphic images, operation was performed with the possible diagnosis of PHP. PTH measurement was taken from the right jugular vein. Intraoperative PTH was 634 pg/mL. Histopathological examination revealed as parathyroid adenoma. Postoperative hypocalcemia didn't occur and postoperative calcium and iPTH levels were normal.

Conclusion: Clinicians should be aware of the presence of low-normal iPTH in PHP. If the clinical suspicion of PHP is high as in our case, surgery should be performed after exclusion of other causes of hypercalcemia.

Keywords: Hypercalcemia; Low-normal PTH; Parathyroid adenoma

Case Report

Introduction

Primary Hyper Parathyroidism (PHP) is the most common cause of hypercalcemia based on outpatient clinic. The prevalence of PHP in general population is 1%, in women older than 55 years of age; the prevalence reaches to 2% [1]. The diagnosis of PHP is generally straightforward with high intact parathyroid hormone (iPTH) and hypercalcemia. But, PHP does not always exhibit those biochemical features. Normocalcemic hyperparathyroidism was reported in the literature as a different phenotype of PHP [2,3]. Less known phenotype of PHP is the hypercalcemia with normal level of iPTH. Some case reports regarding to this issue were published [4-6]. It is difficult to claim true incidence of that phenotype of PHP but the incidence is approximately 10% (0.3-18%) according to the case series [7]. Herein, we report a case of parathyroid adenoma with low normal peripheral iPTH and high jugular PTH levels presenting as hypercalcemia. So, we aimed to discuss the different mechanisms of such an entity with the guidance of the literature.

A thirty-six year old woman who has type 2 diabetes mellitus was admitted to the hospital with the diagnosis of acute pancreatitis. She had no cholelithiasis in her past medical history and there was no hypercalcemia on admission. Serum amylase and lipase levels were high. Acute edematous pancreatitis was shown on computed tomography. She had hypertriglyceridemia in her past medical history. Serum of the patient was observed as lipemic. Hypertriglyceridemia was thought as the etiology for the pancreatitis. On laboratory examination at admission to the hospital; calcium level was 8.0 mg/dL (normal reference range 8.8-10.2 mg/dL) and 25-hydroxy vitamin D level was 6.5 ng/mL (normal reference range 30-80 ng/mL). Cholecalciferol was given intramuscularly as 300.000 IU. Acute pancreatitis subsided after two weeks. At that period, it was found that serum calcium levels were high. iPTH levels were measured to explain high calcium levels. Serum calcium and iPTH levels were as follows: 10.6, 10.7, 10.9 mg/dL and 28.8, 33.3, 31.7 pg/mL (normal reference range 10-88 pg/mL), respectively. In her past medical history, hypothyroidism and nodular goiter was present. Thyroid ultrasonography was performed. There was a hypoechoic solid nodule on right thyroid lobe sized as 7 × 3 mm. There was also 17 × 6 mm sized lesion at the lower part of right thyroid lobe revealed as possible

parathyroid adenoma. On Tc 99m MIBI scintigraphy, a lesion was seen at the lower part of right thyroid lobe (Figure 1).

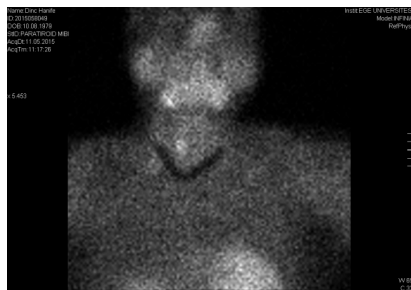


Figure 1: Scan of Tc 99 MIBI scintigraphy: Lesion at the lower part of right thyroid lobe.

This lesion was thought as parathyroid adenoma. There was no osteoporosis according to bone mineral densitometry. Twenty-four hour calcium excretion was 403 mg/day, serum phosphor was 2.3 mg/dL (normal reference range 2.5-3.5 mg/dL). iPTH measurement was repeated in another accredited laboratory and found as 27 pg/mL (normal reference range 10-65 pg/mL). iPTH was measured also by using dilution technique and obtained as 38 pg/mL. Hydration and furosemide treatment were performed, but calcium level was still high, which was 11.4 mg/dL. Beside to hypertriglyceridemia, we thought that hypercalcemia could precipitate the episodes of pancreatitis. Based on the findings of hypercalcemia, hypercalciuria, positive sonographic and scintigraphic images, operation was performed with the possible diagnosis of PHP. iPTH measurement was taken from the right jugular vein. Intraoperative iPTH was 634 pg/mL. Histopathological examination revealed as parathyroid adenoma. Postoperative hypocalcemia didn't occur and postoperative calcium and iPTH levels were normal (Figure 2).

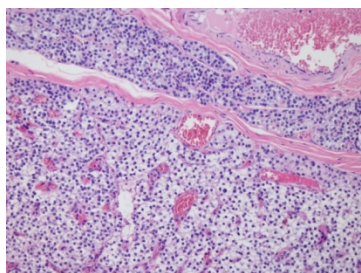


Figure 2: Picture of pathology specimen: Tumor tissue, in adenoma morphology, is separated by a thin capsule from compressed parathyroid tissue and made up of clear cells.

Discussion

Herein, we reported a case with low-normal serum iPTH level and surgically diagnosed parathyroid adenoma causing PHP. A few cases of PHP with low-normal serum iPTH levels have been reported in the literature [4,8]. Our case had hypercalcemia with low-normal iPTH level. In a study by Glendenning, 11 out of 60 patients (18%) had a serum level of iPTH within the reference range. Michis-Troussard et al. reported that 20 of 271 (7.4%) cases of PHP had normal level of iPTH

levels preoperatively [5,6]. When clinical features of PHP exist, the diagnosis of PHP should be kept in mind even if the iPTH levels were in normal range [5]. When iPTH level was in the upper part of the normal range, iPTH level was thought as inappropriate for a high calcium level. But suppressed or low-normal iPTH levels in PHP could be perplexing and this situation may suspend the clinician from making diagnosis of PHP. In the study of Wallace et al. PHP with normal levels of PTH cases were found to be 5.5% (46 out of 843 patients) [7]. According to the iPTH levels (normal reference range 10-60 pg/mL), they identified patients into three groups. In subgroup I, 7 patients (15%) had iPTH levels smaller than 40 pg/mL. 40% of normal PTH patients with hypercalcemia had iPTH levels between 10-60 pg/mL, classified as subgroup II. Subgroup III had 20 patients (44%) whose iPTH levels were greater than 60 pg/mL intermittently. Subgroup III could be interpreted as inappropriate high iPTH levels for the hypercalcemia [7].

There are several mechanisms leading to normal iPTH level in a case of PHP. Intact PTH degrades rapidly because of the heat labile property. Sample collection and sending to the laboratory should be performed in accordance with cold chain. We repeated measurement of iPTH many times to exclude the possibility of breakdown of cold chain [9]. Hypomagnesemia could be a reason for the low-normal iPTH levels. Magnesium is necessary for the action of PTH. So, in a case of hypercalcemia in PHP, there is no problem with the action of PTH even though level of PTH is normal [9]. Moreover, hypomagnesemia was not present in our patient. Our patient had hypocalcemia at the time period of acute pancreatitis. When pancreatitis began to subside, calcium levels increased and stayed at high levels. In case of hypercalcemia with normal iPTH level, malignancy, sarcoidosis should be excluded. High PTH related peptide (PTHrP) could be a reason explaining this kind of laboratory. PTHrP secretion by the parathyroid adenoma was shown in the literature [10]. Unfortunately, we couldn't measure PTHrP.

Assay variability could explain normal level of iPTH in case of hypercalcemia. IRMA (immunoradiometric assay) and ICMA (immunochemiluminometric assay) are two methods of measuring iPTH. In IRMA assay, "hook effect" can be observed. In two-site immunoassays, when analyte concentration is high, solid-phase antibody becomes inadequate and as a result of competitive reaction, false negative results known as hook effect are obtained. Hook effect is uncommon when ICMA assay is used [11]. In our case we measured iPTH by dilution method but the result did not change. Intact PTH was again in the low-normal range.

The other possibility may be the biologically active fragments secreted from the parathyroid adenoma. iPTH assays could not detect those fragments. In the study of Wallace et al, intraoperative PTH (IOPTH) was measured in 44 of 46 patients with normal PTH hypercalcemia patients [7]. In 36 of 44 patients pre-resection IOPTH levels were high (>60 pg/mL). The mean value for IOPTH levels was 279 pg/mL [7]. We also measured pre-resection IOPTH level at right jugular vein site. The result was remarkable as high level of iPTH that was 634 pg/mL. After secretion of PTH from the adenoma, PTH molecule could be subjected to posttranslational modification. In that way, PTH was measured as normal in peripheral vein.

One of the reason to explain normal iPTH in PHP could be pulsatile secretion of PTH. But this possibility could be ruled out by repeating the measurement easily. Lower set point for PTH may exist in some patients due to increased tissue sensitivity to iPTH [7]. Lastly, circulating inhibitor molecules could explain why the iPTH is normal

in PHP [7]. But in our case, high IOPTH level makes the posttranslational modification more probable when compared to circulating inhibitors.

In conclusion, clinicians should be aware of the presence of low-normal iPTH in PHP. If the clinical suspicion of PHP is high as in our case, surgery should be performed after exclusion of other causes of hypercalcemia. In this report, we discussed all possibilities of low-normal PTH in PHP. At the end, we speculate that posttranslational modification may be a reason for low-normal PTH levels in our case.

References

1. AACE/AAES Task Force on Primary Hyperparathyroidism (2005) The American Association of Clinical Endocrinologists and the American Association of Endocrine Surgeons position statement on the diagnosis and management of primary hyperparathyroidism. *Endocr Pract* 11: 49-54.
2. Siperstein AE, Shen W, Chan AK, Duh QY, Clark OH (1992) Normocalcemic hyperparathyroidism. Biochemical and symptom profiles before and after surgery. *Arch Surg* 127: 1157-1156.
3. Lowe H, McMahon DJ, Rubin MR, Bilezikian JP, Silverberg SJ (2007) Normocalcemic primary hyperparathyroidism: further characterization of a new clinical phenotype. *J Clin Endocrinol Metab* 92: 3001-3005.
4. Hollenberg AN, Arnold A (1991) Hypercalcemia with low-normal serum intact PTH: a novel presentation of primary hyperparathyroidism. *Am J Med* 91: 547-548.
5. Glendenning P, Gutteridge DH, Retallack RW, Stuckey BG, Kermode DG, et al. (1998) High prevalence of normal total calcium and intact PTH in 60 patients with proven primary hyperparathyroidism: a challenge to current diagnostic criteria. *Aust N Z J Med* 28: 173-178.
6. Mischis-Troussard C, Goudet P, Verges B, Cougard P, Tavernier C, et al. (2000) Primary hyperparathyroidism with normal serum intact parathyroid hormone levels. *QJM* 93: 365-367.
7. Wallace LB, Parikh RT, Ross LV, Mazzaglia PJ, Foley C, et al. (2011) The phenotype of primary hyperparathyroidism with normal parathyroid hormone levels: how low can parathyroid hormone go? *Surgery* 150: 1102-1112.
8. Lafferty FW, Hamlin CR, Corrado KR, Arnold A, Shuck JM (2006) Primary hyperparathyroidism with a low-normal, atypical serum parathyroid hormone as shown by discordant immunoassay curves. *J Clin Endocrinol Metab* 91: 3826-3829.
9. Bhadada SK, Cardenas M, Bhansali A, Mittal BR, Behera A, et al. (2008) Very low or undetectable intact parathyroid hormone levels in patients with surgically verified parathyroid adenomas. *Clin Endoc* 69: 382-385.
10. Gurrado A, Marzullo A, Lissidini G, Lippolis A, Rubini D, et al. (2008) Substernal oxyphil parathyroid adenoma producing PTHrP with hypercalcemia and normal PTH level. *World J Surg Oncol* 6: 24.
11. Tate J, Ward G (2004) Interferences in immunoassay. *Clin Biochem Rev* 25: 105-120.