

Case Report

Open Access

# A Rare Presentation of Abdominal Tuberculosis-Jejunojunal Intussusception

Shetty Prathvi\*, Tauro Leo F and Auti Anand

Department of Surgery, Father Muller Medical College and Hospital, Kankanady Mangalore, Karnataka, India

## Abstract

Abdominal tuberculosis continues to be a major problem in many regions of the world. The lack of specific signs and symptoms of abdominal tuberculosis involving the intestinal tract frequently leads to missed or delayed diagnosis. They are usually present with weight loss, abdominal pain and bowel disturbance or in severe complications like obstruction, perforation, and fistula formation. Though presenting as intussusceptions is uncommon hence we present such a case of Jejunojunal intussusceptions caused by abdominal tuberculosis in a 16 year old male since it is an extremely rare complication.

**Keywords:** Intussusceptions; Tuberculosis; Abdomen

## Introduction

Diagnosis of abdominal Tuberculosis (TB) is usually very difficult, due to nonspecific symptoms and signs as it includes TB of the gastrointestinal tract, peritoneum, omentum, mesentery, lymph nodes, and other solid intra-abdominal organs like liver, spleen, and pancreas [1]. They presenting as intussusception is very uncommon and in adults is very rare. Intussusceptions is a condition where segment of bowel 'telescopes' into the lumen of the immediately adjacent part and is commonly seen in children less than two years cause being idiopathic but associated with some pathology in older patients [2]. We report such a case jejunojunal intussusception caused by abdominal tuberculosis presenting with features of intermittent bowel obstruction.

## Case History

A 16 year old male from an average socioeconomic status presented with dull aching abdominal pain of one month duration and persistent vomiting for one week. He had no history of cough, fever, loss of weight or bowel disturbances. He was averagely built and moderately nourished. On general physical examination, no abnormality was detected and the abdominal examination revealed epigastric tenderness. There were no hepatosplenomegaly or any mass felt. His Rectal examination was normal and his past medical and family history did not shed any light.

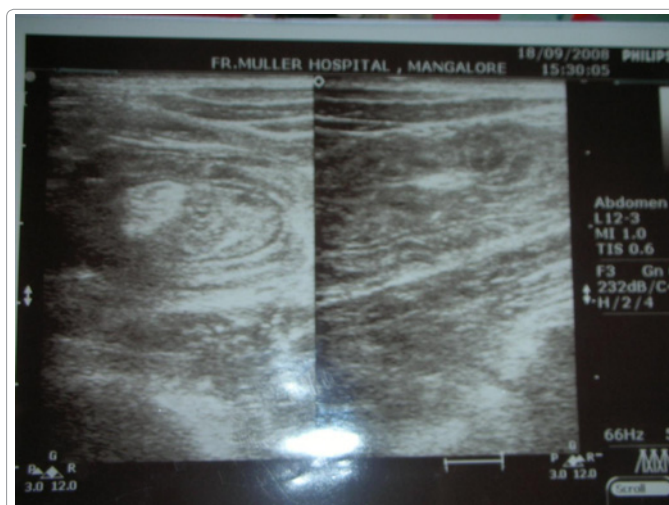His routine haematological investigations including ESR and urine analysis were within normal limits. Chest X- ray was normal. Abdominal ultrasonography revealed hypoechoic and hyperechoic layers with a hyperechoic centre showing as multiple concentric ring sign in left lumbar region denoting jejunojunal intussusception (Figure 1). Computerised tomography scan revealed an in homogenous soft tissue mass lesion that is target or sausage shaped with enlarged mesenteric lymph nodes and proximal oedematous jejunum suggestive of jejunojunal intussusception in the left lumbar region (Figure 2).

His abdomen was opened through lower midline incision. Oedematous jejunal loop was present with no intussusception and multiple mesenteric and paraaortic lymph node were present, representative mesenteric lymph node was biopsied. Histopathological examination of this lymph node showed reactive follicles of irregular shape and sinus histiocytes. A few foci of epithelioid granulomas with necrosis were also seen which were suggestive of tuberculous lymphadenitis (Figure 3). Polymerase chain reaction for microbacterium tuberculosis was positive. Post operative period was uneventful. Patient was started on Antitubercular medications for 6 months. In the first

2 months Rifampicin, Ethambutol, Isoniazid and Pyrazinamide were administered and then with isoniazid and rifampicin for the next 4 months. Patient was asymptomatic on 7 months follow up.

## Discussion

Abdominal tuberculosis accounts for 11%-16% of extra pulmonary TB [3]. Abdominal TB has diverse and non- specific symptomatology requiring a high index of clinical suspicion. Their usual presentation includes abdominal pain, weight loss, anemia, and fever with night sweats. Patients may present with symptoms of obstruction,



**Figure 1:** Abdominal ultrasound picture showing multiple concentric ring signs denoting Jejunojunal intussusception.

\*Corresponding author: Dr. Shetty Prathvi, Department of Surgery, Father Muller Medical College and Hospital, Kankanady, Mangalore-575002, Karnataka, India, Tel: +919886839423; E-mail: [prathviz@gmail.com](mailto:prathviz@gmail.com)

Received July 23, 2012; Accepted October 19, 2012; Published October 21, 2012

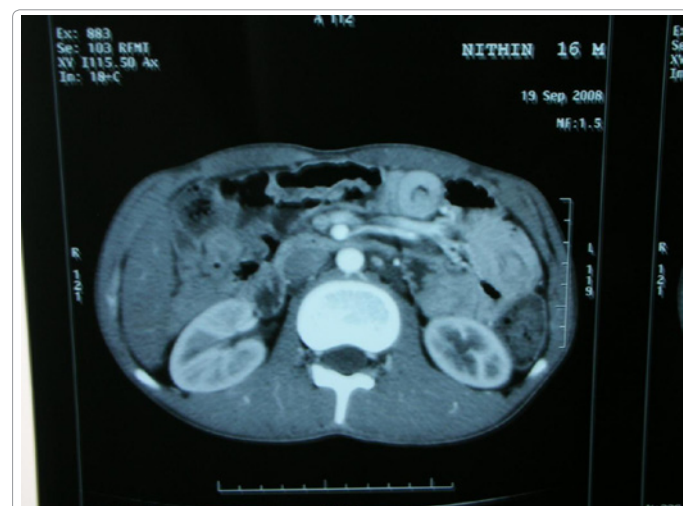**Citation:** Prathvi S, Tauro LF, Anand A (2012) A Rare Presentation of Abdominal Tuberculosis-Jejunojunal Intussusception. J Clin Case Rep 2:217. doi:10.4172/2165-7920.1000217

**Copyright:** © 2012 Prathvi S, et al. This is an open-access article distributed under the terms of the Creative Commons Attribution License, which permits unrestricted use, distribution, and reproduction in any medium, provided the original author and source are credited.

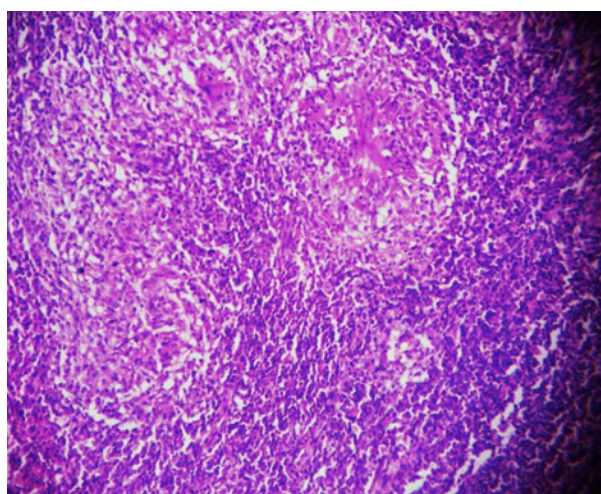
hemorrhage, perforation right iliac fossa pain, or a palpable mass in the right iliac fossa. Ileocecal involvement is seen in 80-90% of patients with abdominal TB and is attributed to the abundance of lymphoid tissue (Peyer patches) in the distal and terminal ileum. Jejunum is less commonly involved than ileum [4-6]. Few cases of abdominal TB presenting as ileocolic intussusception has been reported [7].

In contrast to childhood intussusception, which is idiopathic in 90% of cases, adult intussusception has a demonstrable lead point, which is a well-definable pathologic abnormality in 70%-90% of cases.

The clinical presentation of patients with intussusception also differs in these two age groups. The classic triad of conventional intussusception seen in children (sudden onset of intermittent colicky pain, bloody mucoid stools and a palpable mass) is not common in adulthood. In adults, the clinical findings are variable: acute intestinal obstruction is not common, and most have a history of episodes of intermittent abdominal pain and sometimes with nausea, vomiting and abdominal distension, as had happen in our case [8,9].



**Figure 2:** Abdominal CT scan picture depicting target sign specific of intussusception.



**Figure 3:** Photo microgram showing caseating granuloma with histiocytes, epithelioid cells and Langhans giant cells (H and E).

Investigations like Imaging (ultrasound, barium X-Rays and CT scan) and Mantoux test have only supportive value in abdominal TB. It has been reported that abdominal CT findings can help in making the diagnosis of intestinal tuberculosis. When the inflammatory process is mild, CT shows only slight and symmetric wall thickening and a few small regional lymph nodes, while in the advanced stage, CT shows asymmetric thickening of the ileocecal valve and medial wall of the cecum, and a heterogeneous soft-tissue mass that envelopes the terminal ileum. The location of the disease is also helpful in making the diagnosis of intestinal tuberculosis. Approximately 75% of intestinal tuberculosis patients have involvement of the distal small bowel and ileocecal region. In our case since the presentation was intussusception were abdominal CT has been reported to be the most useful tool for diagnosis with a diagnostic accuracy rate of 58-100% [8,9].

Response to antitubercular drugs is generally very good and surgical intervention in patients with abdominal tuberculosis is around 25%-75% [10].

To conclude, Abdominal TB is a complex disease with non specific and vague clinical presentation. We reported this case of intussusception caused by abdominal tuberculosis, discovered after surgery as an extremely rare complication of it.

#### References

1. Khan R, Abid S, Jafri W, Abbas Z, Hameed K, et al. (2006) Diagnostic dilemma of abdominal tuberculosis in non-HIV patients: an ongoing challenge for physicians. *World J Gastroenterol* 12: 6371-6375.
2. Azar T, Berger DL (1997) Adult intussusception. *Ann Surg* 226: 134-138.
3. Singhal A, Gulati A, Frizell R, Manning AP (2005) Abdominal tuberculosis in Bradford, UK: 1992-2002. *Eur J Gastroenterol Hepatol* 17: 967-971.
4. Rasheed S, Zinicola R, Watson D, Bajwa A, McDonald PJ (2007) Intra-abdominal and gastrointestinal tuberculosis. *Colorectal Dis* 9: 773-783.
5. Baloch NA, Baloch MA, Baloch FA (2008) A study of 86 cases of abdominal tuberculosis. *J Surg Pak* 13: 30-32.
6. Hu ML, Lee CH, Kuo CM, Huang CC, Tai WC, et al. (2009) Abdominal tuberculosis: analysis of clinical features and outcome of adult patients in southern Taiwan. *Chang Gung Med J* 32: 509-516.
7. Mahajan D, Nigam S, Kohli K (2007) Abdominal tuberculosis presenting as ileocolic intussusception in an infant. *Pediatr Dev Pathol* 10: 477-480.
8. Gayer G, Apter S, Hofmann C, Nass S, Amitai M, et al. (1998) Intussusception in adults: CT diagnosis. *Clin Radiol* 53: 53-57.
9. Begos DG, Sandor A, Modlin IM (1997) The diagnosis and management of adult intussusception. *Am J Surg* 173: 88-94.
10. Leone V, Misuri D, Fazio C, Cardini S (2007) Abdominal tuberculosis: clinical features, diagnosis and role of surgery. *Minerva Chir* 62: 25-31.