

A Rare Form of Ectopic Pregnancy on Mesoovarium; Case Report

Atis A*, Gunduz OD, Tolga Karacan and Kublay A

Kanuni Sultan Suleyman Training & Research Hospital Obstetrics & Gynecology, Turkey

*Corresponding author: Atis A, Kanuni Sultan Suleyman Training & Research Hospital Obstetrics & Gynecology, Tel: (212) 404-1500; E-mail: alevatis@mynet.com

Rec date: Mar 17, 2014, Acc date: Apr 20, 2014, Pub date: Apr 22, 2013

Copyright: © 2014 Atis A, et al. This is an open-access article distributed under the terms of the Creative Commons Attribution License, which permits unrestricted use, distribution, and reproduction in any medium, provided the original author and source are credited

Abstract

Broad ligament pregnancy also termed as interligamentous pregnancy is a rare form of ectopic pregnancy. Incidence is reported as 1 in 300 ectopic pregnancies. A broad ligament pregnancy usually results from trophoblastic penetration of tubal pregnancy through the tubal serosa and into the mesosalpinx, with secondary implantation between the leaves of broad ligament. It can also occur if a uterine fistula develops inbetween.

Keywords: Broad ligament pregnancy; Mesoovarium; Hemoperitoneum

Introduction

Broad ligament pregnancy also termed as intraligamentous pregnancy is a rare form of ectopic pregnancy. Incidence is reported as 1 in 300 ectopic pregnancies [1]. A broad ligament pregnancy usually results from trophoblastic penetration of tubal pregnancy through the tubal serosa and into the mesosalpinx, with secondary implantation between the leaves of broad ligament. It can also occur if a uterine fistula develops inbetween [1,2].

Case

A 34-year-old, multigravida with 3 previous cesarean section before presented at 8 weeks gestation with intermittent suprapubic pain and vaginal bleeding. She had undergone three cesarean sections 10, 6 and 3 years earlier. An abdominal ultrasound examination showed free fluid and 3x4 cm left adnexal mass in her abdomen. She was hospitalized for follow-up examination in gynecology clinic and β -hcg level was: 10290, the next day she had the symptoms of acute abdomen and a fall in hematocrit level so she was taken for laparotomy with the diagnosis of ectopic pregnancy under general anesthesia. Perop she was found to have a small intact uterus with bleeding from left mesoovarium, there was a 3cm ruptured mass on this side, the ectopic mass was implanted in the left broad ligament and extracted and sent to pathology. After removal the edges of the lesion were sutured (Figures 1-3). The adnexa seemed intact and had no relationship with the mass, so left in situ and tubal ligation was performed because of the family's desire. β -hcg levels decreased progressively and the mother was discharged home healthily on postoperative 4thday and was well at the 6-week follow up.

Discussion

A broad ligament pregnancy is an extremely rare condition; a rare form of ectopic pregnancy, and one type of abdominal pregnancy. The diagnosis is seldom established before surgery. We suggest the use of clinical and ultrasonographic findings for the suspicion of pregnancy in the broad ligament [3-6]. Broad ligament pregnancy is a rare event particularly with spontaneous conception. Apantaka and colleagues

reported a case of intraligamentum pregnancy following in-vitro fertilization in a patient with previous bilateral salpingectomy [7]. Twin gestation in the broad ligament following both spontaneous and in-vitro fertilization have also been reported [8,9].

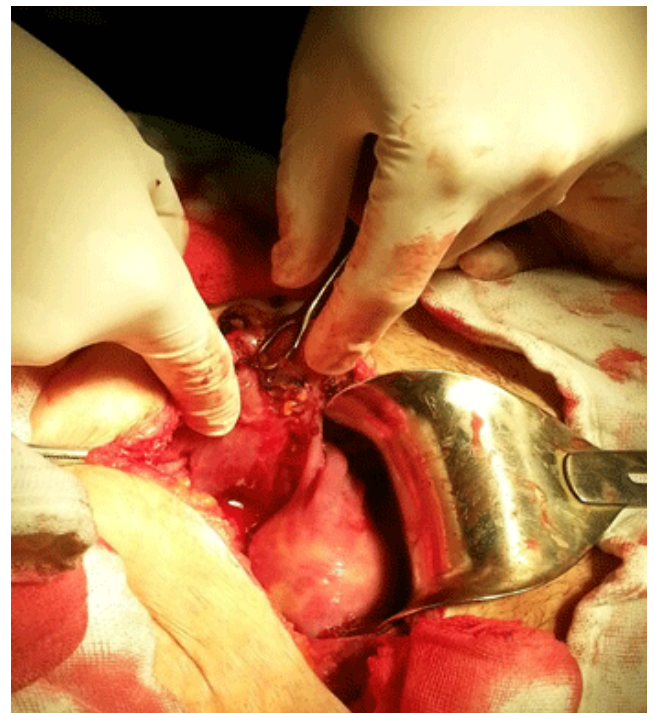


Figure 1: Perop ectopic mass- hemoperitoneum

Besides in-vitro fertilization it can also occur in spontaneous cycles like our case. Most cases of broad ligament pregnancy were diagnosed mostly in the first and early second trimester [3-5,10,11]. Deneke [10] reported a term broad ligament pregnancy associated with a live baby in Ethiopia [10]. Heterotopic pregnancy involving the broad ligament has also been reported [11].

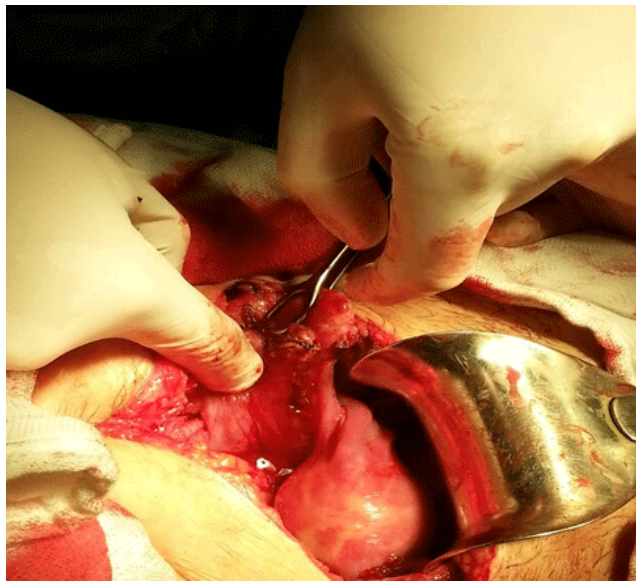


Figure 2: Broad ligament ruptured

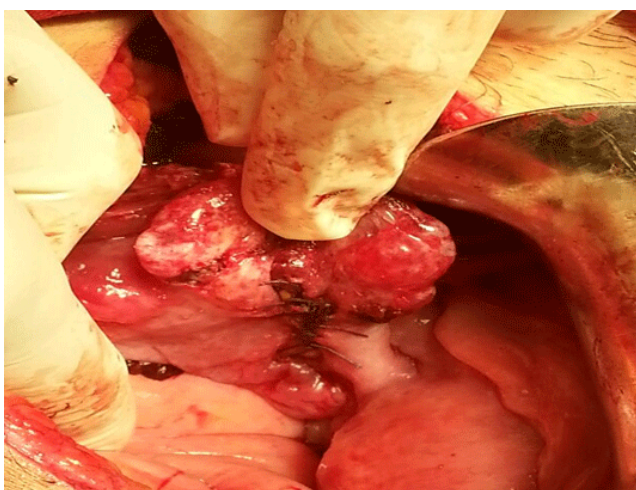


Figure 3: Broad ligament sutured

The relationship of ectopic pregnancies and IVF treatments is well known. We noted both in our case and also in literature that broad ligament pregnancies are most likely to be occurring in patients with previous cesarean sections and/or abdominal operations, may be intraabdominal adhesions are the underlying causes. Previous cesarean operations lead to many obstetric consequences like placenta accrete, previa. Increasing rate of abdominal pregnancies and broad ligament pregnancies in last years may be related to increasing cesarean rates. This theory must be analyzed details in large numbered studies.

Management of broad ligament pregnancies may be done by laparoscopy or laparotomy according to patient's clinic status and surgeon's experience [1,3,4].

References

1. Rahaman J, Berkowitz R, Mitty H, Gaddipati S, Brown B, et al. (2004) Minimally invasive management of an advanced abdominal pregnancy. *Obstet Gynecol* 103: 1064-1068.
2. Paternoster DM, Santarossa C (1999) Primary abdominal pregnancy. A case report. *Minerva Ginecol* 51: 251-253.
3. Morita Y, Tsutsumi O, Kuramochi K, Momoeda M, Yoshikawa H, et al. (1996) Successful laparoscopic management of primary abdominal pregnancy. *Hum Reprod* 11: 2546-2547.
4. Siow A, Chern B, Soong Y (2004) Successful laparoscopic treatment of an abdominal pregnancy in the broad ligament. *Singapore Med J* 45: 88-89.
5. Abdul MA, Tabari AM, Kabiru D, Hamidu N (2008) Broad ligament pregnancy: a report of two cases. *Ann Afr Med* 7: 86-87.
6. Phupong V, Lertkhachonsuk R, Triratanachai S, Sueblinong T (2003) Pregnancy in the broad ligament. *Arch Gynecol Obstet* 268: 233-235.
7. Apantaka O, Rana P, Inglis T (2006) Broad ligament ectopic pregnancy following in-vitro fertilization in a patient with previous bilateral salpingectomy. *J Obstet Gynaecol* 26: 474.
8. Phupong V, Tekasakul P, Kankaew K (2001) Broad ligament twin pregnancy. A case report. *J Reprod Med* 46: 144-146.
9. Deshpande N, Mathers A, Acharya U (1999) Broad ligament twin pregnancy following in-vitro fertilization. *Hum Reprod* 14: 852-854.
10. Deneke F (1997) Advanced abdominal pregnancy in an Ethiopian mother: case report. *East Afr Med J* 74: 535-536.
11. Atalla RK, Murphy PC, Balachandrar C (1997) Combined intrauterine and broad ligament ectopic pregnancy. *J Obstet Gynaecol* 17: 203.