

## A Rare Cause of Painless Haematuria- Adenocarcinoma of Appendix

Shantanu Kumar Sahu<sup>1\*</sup>, Shikhar Agarwal<sup>2</sup>, Sanjay Agrawal<sup>3</sup>, Shailendra Raghuvanshi<sup>4</sup>, Nadia Shirazi<sup>5</sup>, Saurabh Agrawal<sup>1</sup> and Uma Sharma<sup>1</sup>

<sup>1</sup>Department of General Surgery, Himalayan Institute of Medical Sciences, Swami Rama Himalayan University, Uttarakhand, India

<sup>2</sup>Department of Urology, Himalayan Institute of Medical Sciences, Swami Rama Himalayan University, Uttarakhand, India

<sup>3</sup>Department of Anesthesia, Himalayan Institute of Medical Sciences, Swami Rama Himalayan University, Uttarakhand, India

<sup>4</sup>Department of Radiodiagnosis, Himalayan Institute of Medical Sciences, Swami Rama Himalayan University, Uttarakhand, India

<sup>5</sup>Department of Pathology, Himalayan Institute of Medical Sciences, Swami Rama Himalayan University, Uttarakhand, India

### Abstract

Neoplasms of the appendix are rare, accounting for less than 0.5% of all gastrointestinal malignancies and found incidentally in approximately 1% of appendectomy specimen. Carcinoids are the most common appendicular tumors, accounting for approximately 66%, with cystadenocarcinoma accounting for 20% and adenocarcinoma accounting for 10%. Appendiceal adenocarcinomas fall into one of three separate histologic types. The most common mucinous type produces abundant mucin, the less common intestinal or colonic type closely mimics adenocarcinomas found in the colon, and the least common, signet ring cell adenocarcinoma, is quite virulent and associated with a poor prognosis. Adenocarcinoma of appendix is most frequently perforating tumour of gastrointestinal tract due to anatomical peculiarity of appendix which has an extremely thin subserosal and peritoneal coat and the thinnest muscle layer of the whole gastrointestinal tract. In addition to the risk of perforation, mucinous adenocarcinoma of appendix have peculiar tendency for fistula formation. Many of unusual presentations reported for primary appendicular carcinoma are the results of fistula formation into the adjacent viscera such as the urinary bladder, bowel or vagina as well as extraperitoneally into retroperitoneal tissues or directly to the skin surface.

**Keywords:** Adenocarcinoma; Appendix; Haematuria; Urinary bladder; Hemicolectomy

### Introduction

Neoplasms of the appendix are rare, accounting for less than 0.5% of all gastrointestinal malignancies and found incidentally in approximately 1% of appendectomy specimen. Carcinoids are the most common appendicular tumors, accounting for approximately 66%, with cystadenocarcinoma accounting for 20% and adenocarcinoma accounting for 10% [1]. We present a case of adenocarcinoma of appendix presenting only with a recurrent painless haematuria.

### Case Report

A 79 year male presented to our surgical clinic with history of recurrent attacks of painless haematuria since last 5 months. There was no history of any fever, pain abdomen or any other urinary complaints. Patient had history of similar attacks 5 months back for which he was investigated by routine haemogram and urine analysis. During that time his total leukocyte count was around 9000 cu/mm with urine analysis showed 15-20 red blood cells without any pus cells. He was taken up for cystoscopy which revealed a congested area in the bladder mucosa suggestive of cystitis. Then oral and intravenous contrast enhanced CT scan abdomen was planned which was reported to be acute appendicitis complicated by cystitis. Conservative management in the form Oshner Sherren's regiment with a plan of subsequent interval appendectomy was planned. Patient then had an uneventful recovery then with that conservative management. General physical examination at this time of presentation was unremarkable. Examination of abdomen showed mild tenderness in the suprapubic and right iliac fossa region without any palpable mass. Complete haemogram showed haemoglobin 13.23 g/dl, total leukocyte count- 7000 cu/mm with differential leukocyte count showing neutrophil- 72%, lymphocyte- 18%, monocyte- 10%. Routine urine test showed 5-7 red blood cells/high power fields. Liver function test and renal function test was within normal limits. Oral and intravenous contrast enhanced CT scan of abdomen was planned which showed a heterogeneously enhancing oblong mass lesion measuring

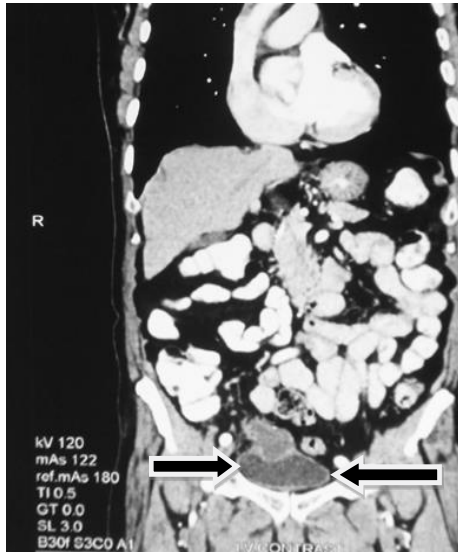approximately 6 × 2.5 cm replacing the appendix with the tip of the lesion having an ill-defined interface with the dome of the urinary bladder suggestive of infiltration. No evidence of intrinsic mass lesion was seen within the urinary bladder. No abdominal lymphadenopathy or free intraperitoneal free fluid was detected. Interface between the mass lesion with bowel loops, right iliac vessels and right ureter was well maintained (Figure 1). Patient was planned cystoscopy followed by exploratory laparotomy. On cystoscopy an external bulge in the anterior urinary bladder wall with an area of mucosal erosion showing mild bleeding was seen. No intrinsic mass lesion was detected in the urinary bladder (Figure 2). Exploratory laparotomy was done. Appendicular growth was seen invading the dome of the urinary bladder (Figures 3 and 4). Right hemicolectomy with en bloc resection of invasion in urinary bladder was done. Primary ileo transverse anastomosis with repair of the urinary bladder wall was done under the cover of suprapubic cystostomy. Patient had an uneventful postoperative recovery. On post operative day 16 cystogram was done which revealed no leakage of contrast from the urinary bladder. Suprapubic cystogram was removed on post operative day 19. Histopathology of the specimen was suggestive of moderately differentiated mucinous adenocarcinoma with regional nodal metastasis with 4/15 lymphnodes showing metastatic deposits with perinodal extension. All resected margins were free from tumor (Figure 5). Patient was discharged with a plan of subsequent adjuvant chemotherapy.

**\*Corresponding author:** Shantanu Kumar Sahu, Professor and Head, Department of General Surgery, Himalayan Institute of Medical Sciences, Swami Rama Himalayan University, Post Doiwala, Dehradun, Uttarakhand, India, Tel: +919412933868; E-mail: [lnshantanu@yahoo.co.in](mailto:lnshantanu@yahoo.co.in)

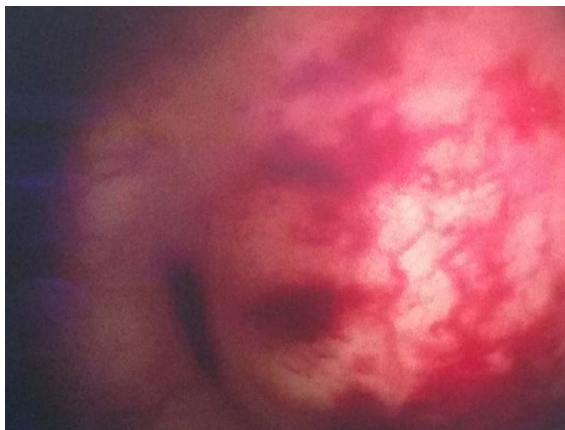
**Received** July 05, 2016; **Accepted** August 02, 2016; **Published** August 09, 2016

**Citation:** Sahu SK, Agarwal S, Agrawal S, Raghuvanshi S, Shirazi N. A Rare Cause of Painless Haematuria- Adenocarcinoma of Appendix. Journal of Surgery [Jurnalul de chirurgie]. 2016; 12(3): 117-119 DOI:[10.7438/1584-9341-12-3-6](https://doi.org/10.7438/1584-9341-12-3-6)

**Copyright:** © 2016 Sahu SK, et al. This is an open-access article distributed under the terms of the Creative Commons Attribution License, which permits unrestricted use, distribution, and reproduction in any medium, provided the original author and source are credited.



**Figure 1:** CECT abdomen showing a heterogeneously enhancing oblong mass lesion with the tip of the lesion having an ill defined interface with the dome of the urinary bladder suggestive of infiltration.

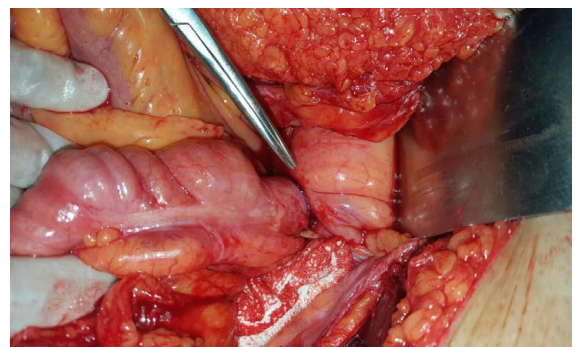


**Figure 2:** Cystoscopy showing an external bulge in the urinary bladder with a small area of mucosal congestion.

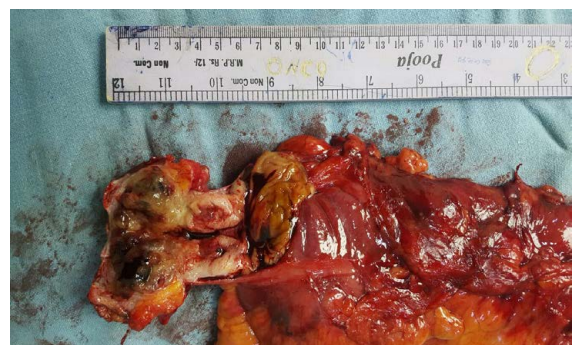## Discussion

A tumor of Appendix is a rare entity and was first reported by Berger in 1882. On review of literature only about 250 cases of appendicular adenocarcinoma have been reported since Berger first described it in 1882 [2]. Carcinoids are the most common appendicular tumors, accounting for approximately 66%, with cystadenocarcinoma accounting for 20% and adenocarcinoma accounting for 10%. Appendiceal adenocarcinomas fall into one of three separate histologic types. The most common mucinous type produces abundant mucin, the less common intestinal or colonic type closely mimics adenocarcinomas found in the colon, and the least common, signet ring cell adenocarcinoma, is quite virulent and associated with a poor prognosis [1,3]. Then there are the rare forms of cancers which include adenocarcinoid, non-Hodgkin's lymphoma, ganglioneuroma, and pheochromocytoma. Malignant tumour normally spreads intraperitoneally through lymphatic. Hematogenous spread is rare. Benign primary processes are mainly mucinous epithelial neoplasms, also called adenomas, cystadenoma, and benign neoplastic mucocele [3]. The majority of primary cancers of the appendix occur in 55-65 years of age, except for malignant carcinoid, which has a mean age of diagnosis of 38. Men and women seem to be at equal risk for all

appendiceal neoplasms except for malignant carcinoid which may have woman to man ratio in excess of 3: 1. Adenocarcinoma of the appendix is usually seen in the 6<sup>th</sup> to 7<sup>th</sup> decade with a male preponderance [2,4]. Appendicular adenocarcinoma usually presents as appendicitis with or without appendicular abscess, palpable abdominal mass, intestinal obstruction and pseudomyxoma peritonei [5]. Adenocarcinoma of appendix is most frequently perforating tumour of gastrointestinal tract due to anatomical peculiarity of appendix which has an extremely thin subserosal and peritoneal coat and the thinnest muscle layer of the whole gastrointestinal tract. In addition to the risk of perforation, mucinous adenocarcinoma of appendix have peculiar tendency for fistula formation [2]. Many of unusual presentations reported for primary appendicular carcinoma are the results of fistula formation into the adjacent viscera such as the urinary bladder, bowel or vagina as well as extraperitoneally into retroperitoneal tissues or directly to the skin surface. Extraperitoneal spread is associated with relatively good prognosis by preventing the development of peritoneal carcinomatosis [6,7]. Unusual presentation includes haematuria due to bladder infiltration, direct invasion of ascending colon detected on colonoscopy, intussusception, hydronephrosis due to ureteric infiltration, retroperitoneal abscess, vaginal bleeding, lower gastrointestinal bleed, epididymitis in case of metastases to the spermatic cord or testicles, ovarian mass due to Krukenberg tumor and cutaneous infiltration [5,8-14]. Management of appendiceal neoplasms should follow oncological principles same as colorectal adenocarcinomas. If the patient presents electively, routine tumour markers including CEA, CT scanning and colonoscopy should be performed. Soft-tissue thickening and irregularity and thickening of the appendix wall and surrounding fat infiltration are nonspecific findings that suggest malignancy of appendix in CT scan abdomen. Gonzalez-Moreno and Sugarbaker found that those patients with mucinous type cancer had no survival benefit from hemicolectomy versus appendectomy.

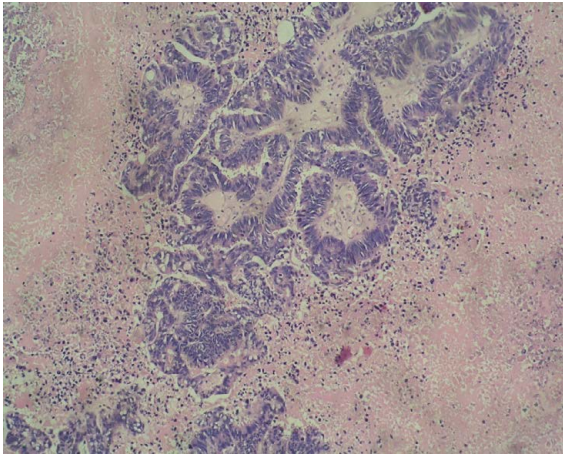


**Figure 3:** Intraoperative photo showing appendicular infiltration into the urinary bladder.



**Figure 4:** Specimen of right hemicolectomy with appendicular growth and wedge resected specimen of urinary bladder entoto.





**Figure 5:** Histopathology of the specimen suggesting moderately differentiated mucinous adenocarcinoma of Appendix.

They further mention that hemicolectomy is recommended in those patients where (1) it is necessary to clear the tumor or perform complete cytoreduction; (2) lymph node involvement is demonstrated by histopathological examination of the appendiceal or ileocolic lymph nodes; or (3) a nonmucinous subtype is identified by histopathological examination. In a study done by Pahlavan and Kanthan adenocarcinoid tumors, he states that even though Goblet cell carcinoma is an aggressive tumor, a simple appendectomy is appropriate in most cases. However, he further states that a right hemicolectomy should be performed in the following scenarios: (1) cellular undifferentiation, (2) increased mitotic activity, (3) involvement of the base of the appendix, (4) lymph node metastasis, or (5) tumor size greater than 2 cm.

Surgical treatment of appendicular adenocarcinoma with right hemicolectomy has been reported as the treatment of choice because it facilitates lymph node resection to enable accurate tumour staging. Post-operative histopathological diagnosis after appendectomy requires second surgery in form of right hemicolectomy. Several studies have showed significantly better 5 year survival rates in patients treated with right Hemicolectomy compared to appendectomy alone. In advanced disease, peritonectomy and intraperitoneal chemotherapy should be considered. Once pseudomyxoma peritonei secondary to the tumour occurs, patient requires aggressive surgical debriement of all deposits on peritoneum besides right hemicolectomy and excision of neighbouring compromised organs. Oophorectomy has been described in female patients with appendicular adenocarcinoma for the dual purpose of staging and removing a potential site of recurrence. Adenocarcinoma of appendix with extraperitoneal and intraperitoneal extensions to different organs requires partial or complete excision of the involved organ and fistulous truck besides right hemicolectomy. The presence of nodal involvement, systemic and intraperitoneal chemotherapy regimens should be used. Prognosis of adenocarcinoma of appendix depends on the subtype and extent of disease. Mucinous adenocarcinoma is considered to have a more favorable prognosis [14-20].

## Conclusion

Neoplasms of the appendix are rare, accounting for less than 0.5% of all gastrointestinal malignancies and found incidentally in approximately 1% of appendectomy specimen. Appendicular adenocarcinoma usually presents as appendicitis with or without appendicular abscess, palpable abdominal mass, intestinal obstruction and pseudomyxoma peritonei and is the most frequently perforating tumour of gastrointestinal tract due to anatomical peculiarity of appendix which has an extremely thin subserosal and peritoneal

coat and the thinnest muscle layer of the whole gastrointestinal tract. Management of appendiceal neoplasms should follow oncosurgical principles same as other colorectal adenocarcinomas. Adenocarcinoma of appendix should be kept in one of the rare differential diagnosis of any unexplained haematuria when all most common indications for the conditions are ruled out by investigations.

## Conflict of Interest

Authors have no conflict of interest to disclose.

## References

- Butte JM, García M, Huidobro MAG, Torres J, Salinas M, et al. (2007) Appendiceal tumors Retrospective review of 67 patients. *Rev Chil Cir* 59: 217-222.
- Mir R, Singh VP (2013) Adenocarcinoma of Appendix Presenting as Flank Fistula. *Indian Journal of Surgical Oncology* 4: 220-221.
- McCusker ME, Coté TR, Clegg LX, Sobin LH (2012) "Primary malignant neoplasms of the appendix: A population-based study from the surveillance, epidemiology and end-results program, 1973-1998. *Cancer* 94: 3307-3312.
- Misdraji J, Young RH (2004) Primary epithelial neoplasms and other epithelial lesions of the appendix (excluding carcinoid tumors). *Semin Diagn Pathol* 21: 120-133.
- Ahmed K, Hoque R, El-Tawil S, Khan MS, George ML (2008) Adenocarcinoma of the appendix presenting as bilateral ureteric obstruction. *World J Surg Oncol* 6: 23.
- Cerame MA (1988) A 25 year review of adenocarcinoma of the appendix A frequently perforating carcinoma. *Dis Colon Rectum* 31: 145-150.
- Nakao A, Sato S, Nakashima A, Nabeyama A, Tanaka N (2002) Appendiceal Mucocele of mucinous cystadenocarcinoma with a cutaneous fistula. *J Int Med Re* 30: 452-456.
- Arisawa C, Takeuchi S, Wakui M (2001) Appendiceal carcinoma invading the urinary bladder. *Int J Urol* 8: 196-198.
- Grover AS, Mittal S, Singla P, Singh P, Kapoor W (2005) Cystadenocarcinoma of appendix with cutaneous fistula- An unusual case presentation. *Indian J Surg* 67: 267-269.
- Murphy JA, Matar N (2009) An Unusual Case of Appendiceal Adenocarcinoma Presenting with Rectal Bleeding and Haematuria. *Case Reports in Gastroenterology* 3: 265-268.
- Parsons JK, Freeswick PD, Jarrett TW (2004) Appendiceal cystadenoma mimicking a cystic renal mass. *Urology* 63: 981-982.
- Liapis A, Michailidis E, Bakas P, Kondi-Pafiti A, Creatasas G (2004) Mucinous tumors of the appendix presenting as primary tumors of the ovary: report of two cases. *Eur J Gynaecol Oncol* 25: 113-115.
- Turaga KK, Pappas SG, Gamblin T (2012) Importance of histologic subtype in the staging of appendiceal tumors. *Ann Surg Oncol* 19: 1379-1385.
- Guraya SY, Almaramhy HH (2011) Clinicopathological features and the outcome of surgical management for adenocarcinoma of the appendix. *World J Gastrointest Surg* 3: 7-12.
- Flint FB, Kahn AM, Passaro E (1970) Adenocarcinoma of the appendix. *Am J Surg* 120: 707-709.
- Sugarbaker PH, Jablonski KA (1995) Prognostic features of 51 colorectal and 130 appendiceal cancer patients with peritoneal carcinomatosis treated by cytoreductive surgery and intraperitoneal chemotherapy. *Ann Surg* 221: 124-132.
- Nitecki SS, Wolff BG, Schlinkert R, Sarr MG (1994) The natural history of surgically treated primary adenocarcinoma of the appendix. *Ann Sur* 219: 51-57.
- Hartley JE, Drew PJ, Qureshi A, MacDonald A, Monson JRT (1996) Primary adenocarcinoma of the appendix. *Journal of the Royal Society of Medicine* 89: 111-113.
- González-Moreno S, Sugarbaker PH (2004) Right hemicolectomy does not confer a survival advantage in patients with mucinous carcinoma of the appendix and peritoneal seeding. *British Journal of Surgery* 91: 304-311.
- Pahlavan PS, Kanthan R (2005) Goblet cell carcinoid of the appendix. *World Journal of Surgical Oncology* 3: 36.