

A Rare Cause of Acute Abdomen in 3rd Trimester of Pregnancy: Isolated Tubal Torsion

Serdar Basaranoglu^{1*}, Elif Agaçayak², Senem Yaman Tunc² and Talip Gul²

¹Idil State Hospital, Department of Obstetrics and Gynecology, Şırnak, Turkey

²Dicle University Faculty of Medicine, Department of Obstetrics and Gynecology, Diyarbakır, Turkey

Abstract

Isolated tubal torsion is rare event during pregnancy. The clinical symptoms are often nonspecific and the diagnosis is difficult, especially in the pregnant abdomen. The diagnosis is usually established during the operation performed for acute abdomen. Early diagnosis and treatment is necessary and early gestational weeks laparoscopy may be a considerable diagnostic tool in these cases. We report a case of isolated tubal torsion in the third trimester of the pregnancy with pararectal incision.

Keywords: Pregnancy; Isolated tubal torsion; Acute abdomen

Introduction

Isolated tubal torsion is a rare gynecologic emergency, the incidence is reported to be approximately 1/1.500.000 [1]. The 12 to 20% of patients are observed in pregnancy [2]. In the evaluation of adnexal masses; ultrasonography (USG) is the gold standard although a definitive diagnosis is diagnosed after surgical exploration [3]. In this case; we aimed the presentation of which is operated with the diagnosis of adnexal torsion and intraoperative detected isolated tubal torsion in the third trimester of pregnancy

Case Report

A 26 years old, primigravid woman admitted to the emergency department with a sudden onset of severe right iliolumbar abdominal pain, nausea and vomiting. At abdominal examination, there were defense and tenderness but no vaginal bleeding or uterine contractility. Obstetric USG examination revealed an average of 30 weeks, single, viable fetus and in the field of right adnexal 74 mm size, anechoic structure cyst was detected. In Doppler, the periphery of the cystic was not identified blood flow. Operation was decided in patients being considered with Adnexal Torsion (AT). The risks and complications that may develop in the mother and fetus were explained to the family depending on the process to be made. After obtaining her family, the patient was operated. Right pararectal incision was made to reach adnexal field in a shorter time and for situated less uterine manipulation. The incision was applied parallel to the linea alba, 8 cm mediolateral of the umbilicus and approximately 5 cm in length. In observation of abdomen; right ovary was normal size and appearance, right fallopian tube approximately 8 cm in length, oedematous and counterclockwise, twice torsion were found (Figure 1). Right fallopian tube was detorsioned after than about 5 cm in length linear incision was made to antimesenteric area and tubal cyst was ekstip. Location of the incision was sutured (Figure 2). Maintenance tocolysis was not applied for about decreasing post-operative pain, without contractions in Non-Stress Test (NST) and cervical changes in gynecological examination. Post-operative pathology result was serous cystadenoma. She delivered vaginally a healthy baby, spontanuesly. The baby was 3150 g of weight, 48 cm of length and had an APGAR score of 8 and 9 at the first and fifth minute, respectively.

Discussion

Isolated tubal torsion is seen rarely in pregnancy and is important with due to non-specific acute abdominal pain symptoms [4]. Sorem et al. reported 1/1.500.000 years as the incidence in women [5]. The

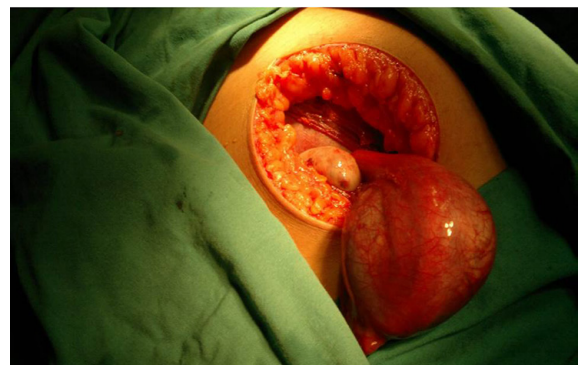


Figure 1: Isolated tubal torsion, intraoperative appearance and pararectal incision.

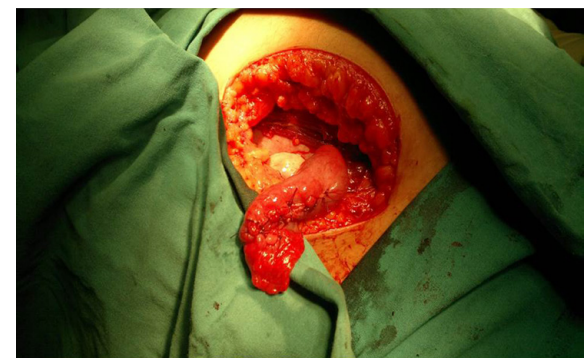


Figure 2: Post-operative appearance.

*Corresponding author: Serdar Basaranoglu, Idil State Hospital, Department of Obstetrics and Gynecology, Şırnak, Turkey, Tel: +905327891458, E-mail: drsbasaran@gmail.com

Received November 05, 2014; Accepted December 15, 2014; Published December 17, 2014

Citation: Basaranoglu S, Agaçayak E, Tunc SY, Gul T (2014) A Rare Cause of Acute Abdomen in 3rd Trimester of Pregnancy: Isolated Tubal Torsion. J Clin Case Rep 4: 472. doi:10.4172/2165-7920.1000472

Copyright: © 2014 Basaranoglu S, et al. This is an open-access article distributed under the terms of the Creative Commons Attribution License, which permits unrestricted use, distribution, and reproduction in any medium, provided the original author and source are credited.

80% of cases were observed in the reproductive period and 12% were in pregnant women [6]. Cause of tubal torsion is not known exactly but several theories have been proposed. Etiology factors include; long mesosalpinx, hydro/hematosalpenks, tubal mass/neoplasm, adnexal mass (ovarian/paraovarian), abnormal tubal peristalsis, periovarian spasm, adnexal venous congestion, Sellhe theory (pointing to a sudden change in body position), trauma, Pelvic Inflammatory Disease (PID), pelvic adhesions, tubal ligation and enlarging uterus / uterine mass [7,8]. The presence of adnexal masses in pregnancy is a risk factor known for torsion. Yen et al. have reported adnexal masses often due to torsion between 60-80 mm. and 94% of these occurred before the 20. gestational weeks [9]. In our case, risk factors that may cause torsion were the growing uterus due to pregnancy and the presence of tubal cyst. In patients, a blunt-continuous or paroxysmal, unilateral, pungent lower quadrant abdominal pain is the most common presenting symptom. However, nausea, vomiting and urinary symptoms such as urgency may be accompanied with together [10]. In the differential diagnosis ovarian cyst rupture or torsion, appendicitis, PID, fibroid degeneration, intestinal pathologies, maternal hydronephrosis, hepatobiliary pathology and placental abruption should be considered in pregnant women [11]. Tubal torsion is frequently seen on the right side than the left [2]. This condition is described the left fallopian tube have less mobility due to its proximity to the sigmoid mesentery, different venous flows of left and right sides and surgeons opening the abdominal pain on the right side with preliminary diagnosis of acute appendicitis [12]. In recent years, parallel to technological developments MRI imaging is seen as an alternative to surgery in advanced centers [13]. Despite the advanced imaging methods, if torsion is not excluded, early surgical intervention is recommended regardless of the gestational age. The preferred surgical technique is a major concern for pregnant abdomen. Suspicious pathology and depending on the skill of operator, laparoscopic (L/S) or an open approach (e.g., laparotomy) may be preferred [14]. Walsh et al. reported less length of hospital stay and risk of preterm birth in a meta-analysis who evaluated 637 patients underwent laparoscopic appendectomy in the first and second trimesters of pregnancy [15]. In the third trimester of pregnancy L/S experience is very limited. Laparoscopy is used in a safe manner in the first and second trimesters. But, there are no prospective studies of laparoscopy and laparotomy on the advantage over each other in the 3rd trimester of pregnancy [16]. Therefore, surgical technique were determined by the preference of the operator. In our case, pararectal incision was used as an alternative to midline incision and salpingotomi was performed. After the operation, any tocolysis was not applied and term delivery occurred.

In conclusion; in this case report pararectal section were mentioned be an alternative to a midline incision and L/S, early detection of isolated tubal torsion in the third trimester of pregnancy. Pararectal incision has some advantages such as less incision, intervention in less time, less uterine manipulation in the surgical area. However; there is also the disadvantage to evaluate the contralateral adnexae and to require surgical experience.

References

1. Antoniou N, Varras M, Akrivis C, Kitsiou E, Stefanaki S, et al. (2004) Isolated torsion of the fallopian tube: a case report and review of the literature. *Clin Exp Obstet Gynecol* 31: 235-238.
2. Phupong V, Intharasakda P (2001) Twisted fallopian tube in pregnancy: a case report. *BMC Pregnancy Childbirth* 1: 5.
3. <http://www.uptodate.com/contents/ovarian-and-fallopian-tube-torsion>
4. Isci H, Guducu N, Gonenc G, Basgu AY (2011) Isolated tubal torsion in pregnancy a rare case. *Clinical and Experimental Obstetrics and Gynecology* 38: 272-73.
5. Sorem KA, Bengtson JM, Walsh B (1991) Isolated fallopian tube torsion presenting in labor. A case report. *J Reprod Med* 36: 763-764.
6. Vierhout ME, Wallenburg HC (1986) Torsion of the fallopian tube; a case report of a bilateral non-simultaneous torsion and a review of the literature. *Eur J Obstet Gynecol Reprod Biol* 23: 111-115.
7. Ho PL, Liang SJ, Su HW, Chang CY, Hsu CS, et al. (2008) Isolated torsion of the fallopian tube: a rare diagnosis in an adolescent without sexual experience. *Taiwan J Obstet Gynecol* 47: 235-237.
8. Comerçi G, Colombo FM, Stefanetti M, Grazia G (2008) Isolated fallopian tube torsion: a rare but important event for women of reproductive age. *Fertil Steril* 90: 1198.
9. Yen CF, Lin SL, Murk W, Wang CJ, Lee CL, et al. (2009) Risk analysis of torsion and malignancy for adnexal masses during pregnancy. *Fertil Steril* 91: 1895-1902.
10. Krissi H, Shalev J, Bar-Hava I, Langer R, Herman A, et al. (2001) Fallopian tube torsion: laparoscopic evaluation and treatment of a rare gynecological entity. *J Am Board Fam Pract* 14: 274-277.
11. Duncan RP, Shah MM (2012) Laparoscopic salpingectomy for isolated fallopian tube torsion in the third trimester. *Case Rep Obstet Gynecol* 2012: 239352.
12. Gross M, Blumstein SL, Chow LC (2005) Isolated fallopian tube torsion: a rare twist on a common theme. *AJR Am J Roentgenol* 185: 1590-1592.
13. Ten Cate A, Han S, Vliegen AS, Lewi L, Verhaeghe J, et al. (2011) Conservative surgery for left-sided isolated tubal torsion in pregnancy. *JBR-BTR* 94: 212-213.
14. Kizer NT, Powell MA (2011) Surgery in the pregnant patient. *Clin Obstet Gynecol* 54: 633-641.
15. Walsh CA, Tang T, Walsh SR (2008) Laparoscopic versus open appendectomy in pregnancy: a systematic review. *International Journal of Surgery* 6: 339-344.
16. Yakasai IA, Bappa LA (2012) Diagnosis and management of adnexal masses in pregnancy. *J Surg Tech Case Rep* 4: 79-85.