

# A Rare Case of Gorhams Disease of the Third Finger Managed by Surgical Reconstruction

Mrutyunjaya M, Supreeth Nekkanti\*, Ravi Kiran, Pramod, Naveen N, Ganesh A, Arjun Markanday

Department of Orthopaedics, JSS Medical College and Hospital, Mysore, Karnataka, India

## Abstract

A 35 year old male presented with pain in right middle finger since 5 y associated with shortening of right middle finger since 3 y. He had dull aching pain and blackish discoloration of the finger since 5 y. Examination revealed painful, restricted movements at inter-phalangeal joint and shortening of the finger of about 4 cm. After a thorough work up of the patient, he was diagnosed to have Gorham's disease of the third metacarpal which was confirmed by histopathology reports. The patient was managed by surgical reconstruction to provide a functional and cosmetically acceptable hand.

**Keywords:** Gorhams disease; Hand; Metacarpal; Proximal phalanx; Surgical reconstruction

## Introduction

Gorham-Stout disease (vanishing or disappearing bone disease, phantom bone) is a rare disease of unknown aetiology that is characterized by massive osteolysis and excessive intra-osseous proliferation of small blood or lymphatic vessels, resulting in progressive resorption of bone [1]. The disease is often seen in children and young adults of either gender, and mainly affects bones that develop by intramembranous ossification (shoulder girdle, pelvis, jaw, ribs, and spine). Approximately 200 cases of vanishing bone disease have been reported in the literature (Table 1). Numerous names have been used in the literature to describe this condition such as phantom bone disease, massive osteolysis, disappearing or vanishing bone disease and acute spontaneous absorption of bone.

Gorham and Stout presented the first overview of vanishing bone disease in 1955 and reported 24 cases [2]. They concluded progressive osteolysis in those cases was associated with angiomatosis of blood or lymphatic vessels. This is now known as Gorham disease. The aetiology remains speculative, the prognosis is unpredictable.

## Case Report

A 35 year old male presented with pain in right middle finger since 5 y and shortening of middle finger since 3 yrs. He had dull aching pain and blackish discoloration of the finger since 5 y. Examination revealed painful, restricted movements at inter-phalangeal joint and shortening of the finger of about 4 cm (Figure 1).

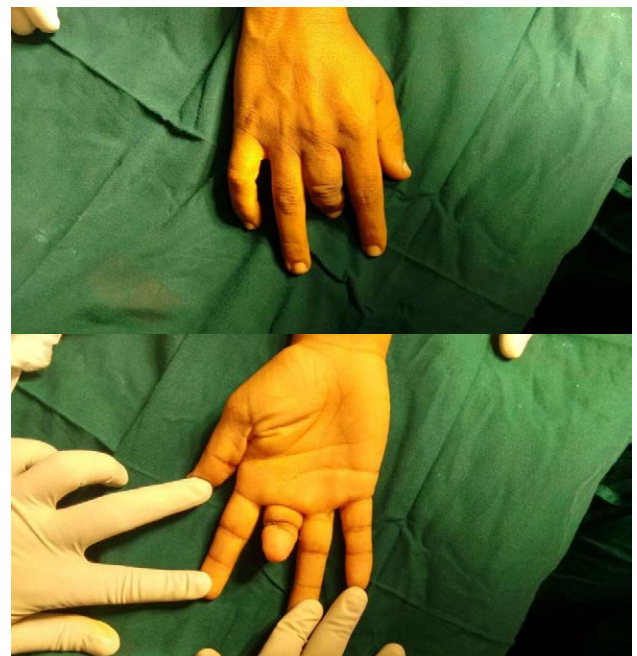


Figure 1: Pre-operative photo of the affected extremity.

Sites of involvement of vanishing bone disease reported in the literature	
Location	No of cases
Skull	8
Maxillofacial	42
Spine	18
Pelvis	14
Trunk (including clavicle and ribs)	35
Upper extremity (including scapula)	41
Lower extremity	22
Multicentric	11
Total	191

Table 1: Sites of involvement of vanishing bone disease reported in the literature.

## Investigations

### X-ray right hand

Showed absence of middle phalanx of middle finger and hazy borders of head of proximal phalanx.

\*Corresponding author: Supreeth Nekkanti, Senior Resident, Department of Orthopaedics, JSS Medical College and Hospital, Mysore, Karnataka, India, Tel: 91-9742551646; E-mail: [drsudreethn@gmail.com](mailto:drsudreethn@gmail.com)

Received June 27, 2015; Accepted July 17, 2015; Published July 24, 2015

Citation: Mrutyunjaya M, Supreeth Nekkanti, Ravi Kiran, Pramod, Naveen N, et al. (2015) A Rare Case of Gorhams Disease of the Third Finger Managed by Surgical Reconstruction. J Integr Oncol 4: 140. doi:10.4172/2329-6771.1000140

Copyright: © 2015 Supreeth N, et al. This is an open-access article distributed under the terms of the Creative Commons Attribution License, which permits unrestricted use, distribution, and reproduction in any medium, provided the original author and source are credited.

### MRI right hand

Suggestive of vascular malformation of the middle finger of the right hand with non-visualization of the middle phalanx, anterior subluxation of the distal phalanx with flexion deformity of the digit, acro-osteolysis and soft tissue thickening (Figure 2).

### Histopathology

Showed multiple sections of spicules of lamellar bone displaying many blood vessels in the bone marrow, stroma is loose with few occasional plasma cells and lymphocytes, which are suggestive of angiomatous hyperplasia (Gorham's disease).

### Diagnosis Gorham's Disease of Right Middle Phalanx

#### Surgical reconstruction

Ray amputation of right middle finger, 3<sup>rd</sup> metacarpal with stump closure and reconstruction of the hand.

**Incision:** 1. A 'Y' shape incision was made over dorsum aspect of the right hand from 2<sup>nd</sup> and 3<sup>rd</sup> web space extending proximally,

2. 'V' shape incision given over the palmar aspect at the base of the 3<sup>rd</sup> metacarpal.

**Soft tissue dissection:** Soft tissue released, phalanx explored and periosteum elevated till base of the 3<sup>rd</sup> metacarpal and excised extensor tendon at the same level, 'V' shape osteotomy done at base of the 3<sup>rd</sup> metacarpal and released distal part. Half of the interossei are excised on either side of the 3<sup>rd</sup> metacarpal and flexor digitorum profundus tendon was excised.

**Fixation:** The retained halves of the interossei were approximated and sutured. A 2 mm K-wire passed from head of 5<sup>th</sup> metacarpal to the 2<sup>nd</sup> head of metacarpal in a transverse manner (Figure 3).

**Immobilization:** Immobilised with below elbow slab.

#### Post-operative rehabilitation

**3 weeks:** K-wire removal

**6 weeks:** achieved full range of movements

**3 months:** 80% hand grip

**6 months:** 100% hand grip achieved (Figure 4).

### Discussion

Vanishing bone disease is a rare idiopathic disease leading to extensive loss of bony matrix, which is replaced by proliferating thin-walled vascular channels and fibrous tissue [3]. Although the disease can be monostotic or polyostotic, multicentric involvement is unusual

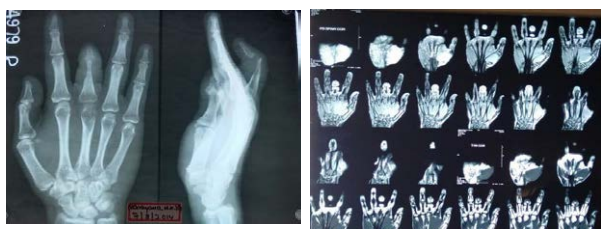

Figure 2: Pre-operative X-ray and MRI results.

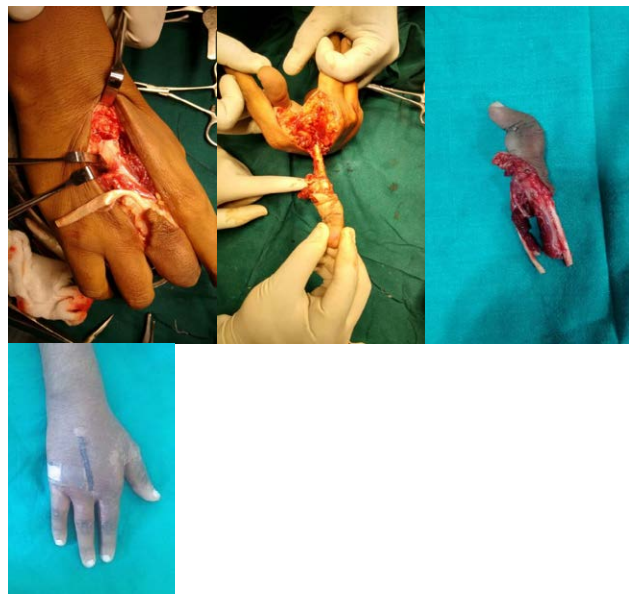


Figure 3: Intra operative picture .

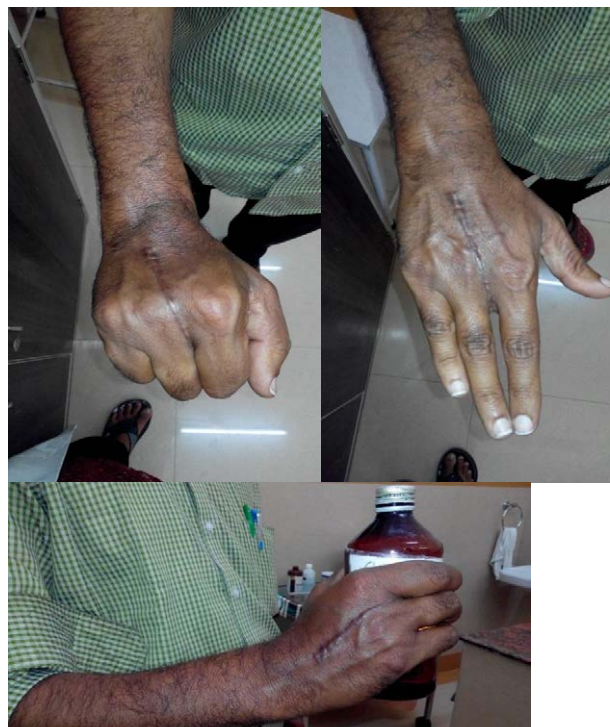

Figure 4: Post operative follow-up, demonstrating the grip strength.

[4]. The patients whom we present had monostotic pattern of the disease.

Gorham's disease may be associated with history of trivial trauma, although as many as half of the patients have no history of trauma. As with many other diseases, the role of trauma in vanishing bone disease may be to signal the presence of a pre-existing abnormality. Our patient also did not present with any history of trauma.

Most cases occur in children or in adults less than 40 years. The bones of the upper extremity and the maxillofacial region are the predominant osseous sites of the disease. Leriche’s hypothesised that post-traumatic arterial hyperaemia was responsible for bone resorption was rejected first by Mouchet, and later by Gorham et al. [5]. The same authors postulated that an angioma might act as a shunt increasing local oxygen tension [5]. The process may affect the appendicular or the axial skeleton. The shoulder and the pelvis are the most common sites of involvement. Gorhams disease affecting the hand is rare and we are presenting this case for its rarity.

Our search in English and international literature revealed only five cases of Gorham’s disease affecting the hand and wrist [2,6-9]. In all the described cases, the disease was unifocal and the phalanges were minimally affected (Table 2).

The diagnosis of vanishing bone disease is based on clinical examination, radiologic imaging studies and histo-pathological study of the affected bone. Vanishing bone disease is not accompanied by general symptoms. Dull aching, weakness in the affected extremity, swelling and skeletal deformities are the usual presenting symptoms [10]. The chief complaints presented by our patient were discolouration, shortening and dull aching pain of the third finger of the right hand since five years.

Radiographs are the best tools for detecting vanishing bone disease [11]. The radiographic appearance becomes diagnostic of vanishing bone disease when unilateral partial or total disappearance of contiguous bones, tapering of bony remnants, and absence of a sclerosing or osteoblastic reaction are observed. In our case, radiography revealed partial disappearance of the third metacarpal with absence of corresponding middle phalanx.

Histologically, the appearance depends on the phase in which the disease is diagnosed. In 1983, Heffez et al. [12] described two phases. The first phase represents increased vascular concentration in the bone-displacing fibrous tissue part; in the second phase, only fibrous tissue is found. The presence and number of osteoclasts vary significantly in vanishing bone disease. In most cases, osteoclastic activity is minimal or nonexistent, whereas in other cases, osteoclasts are easily identifiable [13]. If present, osteoclastic activity is concentrated in the interface between the vascular channels and the cortex [14]. Our patient’s biopsy

report was in concurrence with the literature by the fact that there were multiple bone spicules with increased blood vessels in bone marrow. This suggests that there was increased vascularity (angiomatous hyperplasia) and was probably in the first phase of the disease.

The differential diagnosis should exclude other causes of osteolysis such as skeletal angiomas, essential osteolysis, hereditary osteolysis, infection, trauma (Sudeck atrophy), endocrinal abnormalities, rheumatoid arthritis and tumours [15].

Various modalities of treatment have been described for Gorhams disease. We chose to surgically reconstruct his hand because he wanted to perform his activities of daily living. His main requirements were good hand grip and pincer grip.

### Conclusion

Gorham disease is a combined clinical, radiographic and histological entity. It is characterized by a nonfamilial, histologically benign vascular proliferation originating in bone and producing complete lysis of all or a portion of the bone [16]. Usually, the prognosis depends on complications, such as neurological deficits or pleural effusion. It has been reported that more than 15% of patients die as a result of this disease. Life expectancy is not affected if the extremities are involved. The treatment of vanishing bone disease is controversial. A review of the literature led to the conclusion that there is no consensus about the most efficacious treatment. Synergistic action of zoledronic acid and Interferon is a powerful antiangiogenic therapy, which is currently giving the best results [17-19].

Radiotherapy acts by accelerating sclerosis of the proliferating blood vessels and prevents regrowth of these vessels. Although the use of total doses from 30 Gy to 45 Gy has been reported to be effective, some authors reported excellent results while using a total dose of 15 Gy in a case that involved the upper extremity [20-23].

Surgical intervention has been suggested as the method of choice when feasible and involves local resection of the affected bone, with or without replacement prostheses or bone grafts [24].

### References

- Gorham LW, Stout AP (1955) Massive osteolysis (acute spontaneous absorption of bone, phantom bone, disappearing bone); its relation to hemangiomas. J Bone Joint Surg Am 37-37A: 985-1004.
- Devlin RD, Bone HG 3rd, Roodman GD (1996) Interleukin-6: a potential mediator of the massive osteolysis in patients with Gorham-Stout disease. J Clin Endocrinol Metab 81: 1893-1897.
- Vinée P, Tanyü MO, Hauenstein KH, Sigmund G, Stöver B, et al. (1994) CT and MRI of Gorham syndrome. J Comput Assist Tomogr 18: 985-989.
- Vélez A, Herrera M, Del Rio E, Ruiz-Maldonado R (1993) Gorham’s syndrome. Int J Dermatol 32: 884-887.
- Gorham LW, Wright AW, Shultz HH, Maxon FC Jr (1954) Disappearing bones: a rare form of massive osteolysis; report of two cases, one with autopsy findings. Am J Med 17: 674-682.
- Loppnow H, Libby P (1990) Proliferating or interleukin 1-activated human vascular smooth muscle cells secrete copious interleukin 6. J Clin Invest 85: 731-738.
- Dickson GR, Hamilton A, Hayes D, Carr KE, Davis R, et al. (1990) An investigation of vanishing bone disease. Bone 11: 205-210.
- Lehnhardt M, Steinau HU, Homann HH, Steintraesser L, Druecke D (2004) [Gorham-Stout disease: report of a case affecting the right hand with a follow-up of 24 years]. Handchir Mikrochir Plast Chir 36: 249-254.

Previous cases reported in the international literature with hand and wrist involvement by Gorham’s disease		
Author	Description	Treatment
Tunon and Gonzalez [34]	24 y old man with angiomas of the right hand and complete destruction of the second, third and fourth metacarpals.	The affected metacarpals with the distal row of the carpals were excised, and remaining defect was filled with a bone graft taken from the iliac crest.
Carneiro and Steglich [2]	13 y old girl with extensive metacarpal bone osteolysis of the right hand	Corticocancellous bone grafting(failed),Radiotherapy
Dikson et al. [6]	13 y old girl with extensive metacarpal bone osteolysis of the right hand	Corticocancellous bone grafting (failed), radiotherapy
Lehnhardt et al. [27]	30 y old woman with osteolysis of the right hand	Radiotherapy and repeated bone grafting

**Table 2:** Previous cases reported in the international literature with hand and wrist involvement by Gorham’s disease.

9. Tunon JB, Gonzalez FP (1977) Angiomatosis of the metacarpal skeleton. *Hand* 9: 88-91.
10. Möller G, Priemel M, Amling M, Werner M, Kuhlmei AS, et al. (1999) The Gorham-Stout syndrome (Gorham's massive osteolysis). A report of six cases with histopathological findings. *J Bone Joint Surg Br* 81: 501-506.
11. Naden BA (1995) When bone disappears. *RN* 58: 26-28.
12. Heffez L, Doku HC, Carter BL, Feeney JE (1983) Perspectives on massive osteolysis. Report of a case and review of the literature. *Oral Surg Oral Med Oral Pathol* 55: 331-343.
13. Dickson GR, Mollan RA, Carr KE (1987) Cytochemical localization of alkaline and acid phosphatase in human vanishing bone disease. *Histochemistry* 87: 569-572.
14. Hvos AG (1980) Bone tumours, diagnosis, treatment and prognosis. *J Clin Pathol* 33: 415.
15. Holroyd I, Dillon M, Roberts GJ (2000) Gorham's disease: a case (including dental presentation) of vanishing bone disease. *Oral Surg Oral Med Oral Pathol Oral Radiol Endod* 89: 125-129.
16. Hagberg H, Lamberg K, Aström G (1997) Alpha-2b interferon and oral clodronate for Gorham's disease. *Lancet* 350: 1822-1823.
17. Hammer F, Kenn W, Wesselmann U, Hofbauer LC, Delling G, et al. (2005) Gorham-Stout disease--stabilization during bisphosphonate treatment. *J Bone Miner Res* 20: 350-353.
18. Mawk JR, Obukhov SK, Nichols WD, Wynne TD, Odell JM, et al. (1997) Successful conservative management of Gorham disease of the skull base and cervical spine. *Childs Nerv Syst* 13: 622-625.
19. Fontanesi J (2003) Radiation therapy in the treatment of Gorham disease. *J Pediatr Hematol Oncol* 25: 816-817.
20. Dunbar SF, Rosenberg A, Mankin H, Rosenthal D, Suit HD (1993) Gorham's massive osteolysis: the role of radiation therapy and a review of the literature. *Int J Radiat Oncol Biol Phys* 26: 491-497.
21. Hanly JG, Walsh NM, Bresnihan B (1985) Massive osteolysis in the hand and response to radiotherapy. *J Rheumatol* 12: 580-582.
22. Listewnik MJ, Marzecki Z, Kordowski J (1986) Disappearing bone disease: massive osteolysis of the ribs treated with radiotherapy. Report of a case. *Strahlenther Onkol* 162: 338-341.
23. Grätz KW, Prein J, Remagen W (1987) [A reconstruction attempt in progressive osteolysis (Gorham disease) of the mandible. A case report]. *Schweiz Monatsschr Zahnmed* 97: 980-984.
24. Picault C, Comtet JJ, Imbert JC, Boyer JM (1984) Surgical repair of extensive idiopathic osteolysis of the pelvic girdle (Jackson-Gorham disease) *J Bone Jt Surg Br* 66: 148-149.