

A Painful Groin Pseudotumor Mimicked an Incarcerated Hernia

Wei-Chun Lin¹, I-Hsuan Huang² and Sheng-Der Hsu^{3*}

¹Department of Surgery, Song-Shan Branch, Tri-Service General Hospital, National Defense Medical Center, Taipei, Taiwan

²Division of Gastroenterology, Department of Internal Medicine, Tri-Service General Hospital, National Defense Medical Center, Taipei, Taiwan

³Division of General Surgery, Department of Surgery, Tri-Service General Hospital, National Defense Medical Center, Taipei, Taiwan

Abstract

Incarcerated inguinal hernia is one of the emergency operations for delay diagnosis may cause serious dreadful effects such as bowel obstruction, bacterial translocation with sepsis, intestinal wall necrosis, bowel perforation, or even death. On the other hand, inflammatory pseudotumors (IPTs) were first described by Brunn, but their cause remains unknown. These benign lesions are common in children and young adults, but they can also occur in elderly adults. An 88-year-old Chinese man was referred to our hospital with a painful mass in his right inguinal region for 3 days. The patient complained about abdominal fullness, poor appetite, and right groin painful and an enlarged lesion in his groin site since five days ago. Physical examination revealed a tender, painful, untouchable, and non-pulsatile mass lesion in the right groin area. Non-specific bowel gas and stool impaction in the KUB. Ultrasound and color Doppler images showed a laminated and well-defined mass on the right inguinal region with a hypoechoic center without blood flow signals and increased peripheral vascularity, which was similar to a bowel loop through the inner ring into the inguinal canal. Computed tomography revealed a soft tissue mass-like lesion in right inguinal area. We performed an emergent exploratory laparotomy under a tentative diagnosis of an incarcerated hernia, but just found a mass in the hernia sac during the operation. Histopathologic examination showed typical findings of the IPT. The patient was followed for 6 months without evidence of local recurrence or distant metastasis. As it is nearly impossible to make a correct judgment prior to operation, surgical resection is usually required for diagnosing IPTs.

Keywords: Inflammatory pseudotumor; Groin; Inguinal hernia; Incarcerated hernia

Key Clinical Messages

IPTs have no specific signs or symptoms and can present as benign or malignant diseases in clinical examinations. It can be found on both intrapulmonary and extrapulmonary sites, but extremely rare in the groin. Physicians should take operation into consideration, as symptoms or images mimic an abdominal emergency such as incarcerated hernia.

Introduction

Inflammatory pseudotumors (IPTs) of the lungs were first described by Brunn in 1939. Currently, physicians believe that IPTs, a rare group of benign tumors of unknown etiology, are an inflammatory process secondary to previous infection, trauma, surgery, or autoimmune disease [1]. IPTs predominately involve the lungs, orbits, abdominopelvic region, and retroperitoneum, with extremely rare cases involving other anatomic sites [2]. Clinical imaging studies have shown that this group of tumors can mimic malignancy [3], but post-resection histopathology typically reveals normal or benign lesions of the involved tissue. Pseudotumors have many appellations, such as plasma cell granulomas, plasma cell pseudotumors, inflammatory myofibrohistiocytic proliferation, omental-mesenteric myxoid hamartomas, histiocytomas, and xanthomas [4,5], because they share similar histologic patterns with granulation, nodular fasciitis, histiocytomas, smooth muscle neoplasms, fibromatosis, and scars. IPT is the most commonly used term for describing these conditions. The etiology of these lesions remains unclear, although there are several possible explanations such as infectious, inflammatory or autoimmune processes, and possible foreign body reactions [6-8]. According to our research, pseudotumors in the inguinal region are extremely rare, particularly in relation to the hernia sac. Here, we report a case of a groin mass that presented both clinically and radiologically as an incarcerated hernia, but was found to be a pseudotumor in the hernia sac.

Case Report

An 88-year-old Chinese man was referred to our hospital 3 days after noting a painful mass in his right inguinal region. He presented

a 3-day history of nausea, anorexia, and a palpable tender, painful, and enlarged inguinal mass. He had no history of intra-abdominal surgery, unexplained fever, night sweating, or body weight loss, but complained of constipation for 4 days and had a right inguinal hernia that had been untreated for years. A physical examination revealed that the abdomen exhibited fullness without tenderness. A non-reducible, tender, untouchable, and fixed mass approximately 3 × 2 cm in size was observed in the right inguinal region. Laboratory evaluation revealed anemia (hemoglobin: 6.9 g/dL), elevated serum creatinine (3.3 mg/dL), a low white blood cell count (3500 cells/μL), and normal C-reactive protein (0.60 mg/dL). Other physical and basic paraclinical examinations returned normal results. Ultrasound (US) and color Doppler US scans of the groin and scrotum (Figures 1 and 2) revealed a laminated mass approximately 3.9 × 2.2 cm in size on the right inguinal region, exhibiting central lower echogenicity, wall thickness, and vascularity in the peripheral region. Abdominal computed tomography (CT) without contrast (since he was a chronic kidney disease patient) revealed a soft tissue mass-like lesion in the right inguinal area (Figures 3 and 4). The patient underwent emergency repair surgery with suspicious of incarcerated inguinal hernia. During the operation, a huge hernia sac protruding out along with the spermatic cord was found. We dissected the soft tissue above the inguinal region carefully and the weak posterior wall (thin and loose transversalis fascia) with bulging mass was found. Then, we opened the sac and a firm yellowish mass lesion (Figures 5 and 6), which was not compatible with ours initial impression. The tumor was resected and then sent to

***Corresponding author:** Sheng-Der Hsu, Division of General Surgery, Department of Surgery, Tri-Service General Hospital, National Defense Medical Center, Taipei, Taiwan, Tel: +866-2-8792-3311; Fax: +866-2-8792-7139; E-mail: f108396@gmail.com

Received January 07, 2016; **Accepted** February 19, 2016; **Published** February 23, 2016

Citation: Lin W, Huang I, Hsu S (2016) A Painful Groin Pseudotumor Mimicked an Incarcerated Hernia. J Clin Case Rep 6: 728. doi:10.4172/2165-7920.1000728

Copyright: © 2016 Lin W, et al. This is an open-access article distributed under the terms of the Creative Commons Attribution License, which permits unrestricted use, distribution, and reproduction in any medium, provided the original author and source are credited.

department of pathology for frozen section, and it showed mixed acute and chronic inflammation with fibrosis and focal abscess formation, then a hernioplasty with mesh was performed. The final pathology exhibited mixed acute and chronic inflammation with fibrosis and a

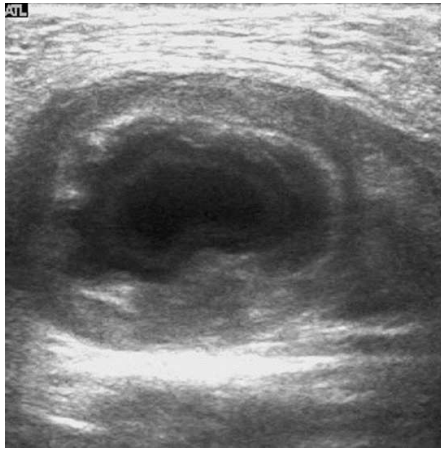


Figure 1: Ultrasound scan of the right inguinal mass revealed a 3.9×2.2 cm laminated mass.

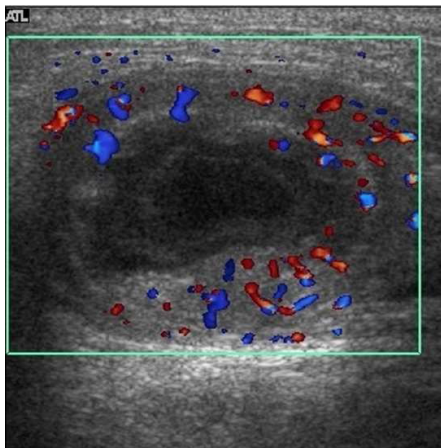


Figure 2: Color doppler image exhibiting central lower echogenicity, wall thickness, and vascularity in the peripheral region.

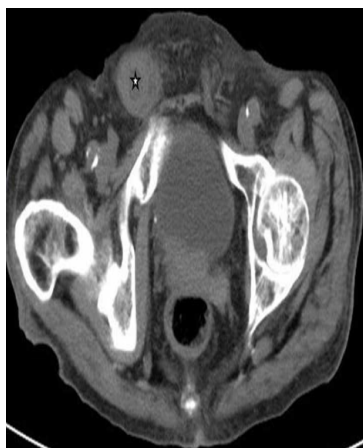

Figure 3: Abdominal CT image without contrast showing a soft tissue mass-like and heterogeneous lesion (asterisk) with a central lower signal in the right inguinal area.

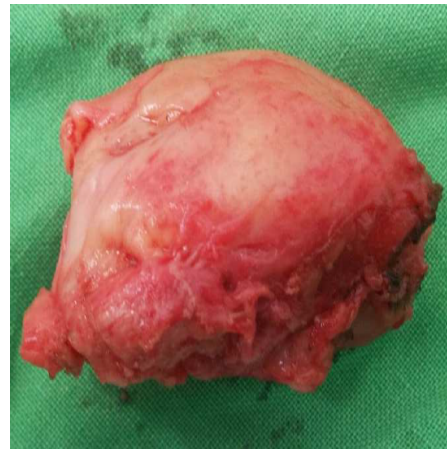

Figure 4: Firm yellowish mass approximately 4×2.5 cm in size in the inguinal hernia sac.

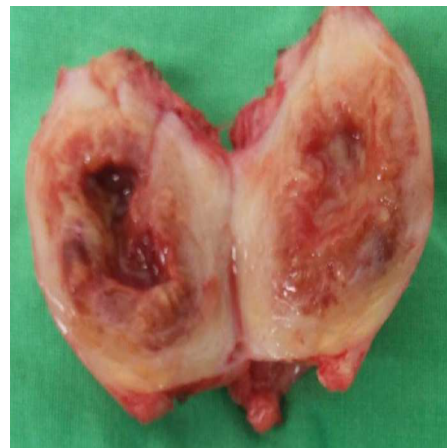

Figure 5: Dissected mass with central necrosis.

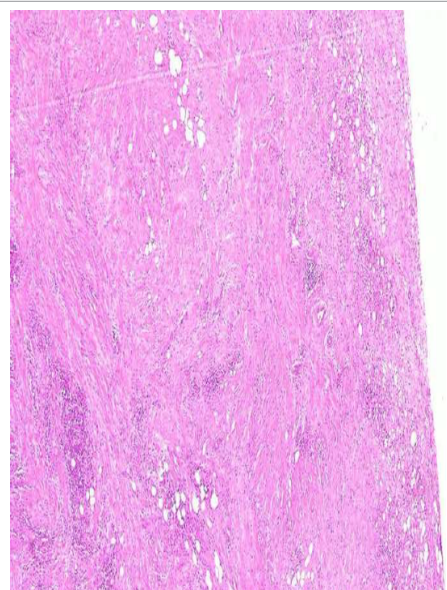


Figure 6: Pathology exhibited mixed acute and chronic inflammation with fibrosis and central abscess formation within the collagenous stroma (hematoxylin and eosin stain, original magnification X40).

central abscess formation of the soft tissue, which was compatible with IPT. We prescribed intravenous antibiotics for 7 days and analgesics for pain control. The postoperative course was uneventful and there was no recurrence or distant metastasis after 6 months of follow-up.

Discussion

Incarcerated hernia is one of the emergency operations because of delay diagnosis may cause bowel perforation and life threatening. Incarcerated inguinal hernia is an irreducible hernia in which a protrusion of abdominal-cavity contents is accompanied with bowel loops through the inguinal canal occurs, because of the narrow opening of the canal. At first, the patients would be asymptomatic and only figure out a mass lesion over their inguinal region. Later, they would feel severe pain and tenderness of the area when the ischemia change of the intestine got worse [9,10]. Thus we need to early diagnose and arrange emergent surgery for this serious condition. Indeed, a careful history taking, physical examinations, and radiological images can help us make a correct diagnosis and treatment of the patients.

IPTs are lesions that are clinically and radiologically similar to neoplastic processes [7,8], and they are difficult to diagnosis accurately before surgery. In our case, the IPT presented as if bowel loops were trapped in the hernia sac on the US, and subsequent CT scans revealed a soft tissue lesion in the right inguinal area. Because the clinical symptoms persisted and got worse, we performed an emergent operation on a suspected incarcerated hernia. However, we only found a groin mass in the hernia sac [11,12].

Although IPTs were first mentioned by Brunn in 1939, it was Umiker et al. [9] who coined the term “inflammatory pseudotumor” to describe these neoplastic lesions in 1954. Subsequently, numerous synonyms have been coined to describe these lesions because of the complexity, variable histologic characteristics, and behavior of pseudotumors [13]. IPTs can present with single or multiple and discrete or indistinct masses that have been reported in many anatomic sites. They predominately occur in the lungs and orbits, with fewer reports in other anatomic areas such as the heart, head and neck, abdomen, pelvis, and soft tissue of the trunk and extremities [4,8,14,15]. According to Shadbolt et al., groin masses can be classified into the following groups according to their pathologic conditions (ie, congenital disease, noncongenital diseases, neoplasms, hematomas and inflammation), and each group of diseases presents specific characteristics on image examinations; however, occasionally, these radiological findings overlap, thereby increasing the uncertainty for detecting the lesions [6,8]. Moreover, IPTs can affect both genders and all races equally [16,17], and they are a group of benign tumors that seldom invade adjacent anatomic structures, have a low recurrence rate, and rarely undergo distant metastasis [8,18]. This case was identified in an elderly Chinese man with previous inguinal hernia left untreated. Because of the likelihood of an incarcerated hernia with limited radiologic and clinical information, surgical resection was performed.

The etiology of IPTs remains unclear, and some possible explanations include trauma, infection, autoimmune disease, and even foreign body-induced inflammation [19-21] were mentioned. The clinical symptoms of IPTs are nonspecific and depend on the growth region of lesions and its relations with neighboring structures. Common clinical manifestations of those lesions include a mass-like lesion, fever, pain, gastrointestinal discomfort, and loss of body weight [2,4,6,8]. The radiologic findings of IPTs are vary and are nonspecific; these characteristics are related to the degree of infiltration or amount of fibrotic tissue [8,22,23]. US scans reveal a diverse pattern of echogenicity, and CT scans may also reveal variable density or contrast-

enhanced images of the lesion [22]. Moreover, magnetic resonance imaging usually has low signals on T1- and T2-weighted images, and these characteristics are related to IPT fibrosis [8,24,25]. Conclusive clinical and radiological diagnosis is nearly impossible because these lesions can mimic many kinds of diseases like malignant tumors. Surgical resection of the mass or recurrent lesions is the first choice of treatment for almost all IPTs, except orbital IPTs. Steroids may play a role in treating IPTs, particularly for orbital pseudotumors. Other treatment options, such as chemotherapy, radiotherapy, and COXII inhibitors for IPTs, may have an unpredictable response [2,3,26,27]. Some studies have reported local recurrence, distant metastasis, or even regression with conservative treatment [10,15].

In summary, IPTs are a group of firm, well-defined, tan-texture, soft, and brown-skin color mass-like lesions, and there have been a few cases of focal necrosis, hemorrhage, or even calcification of varying sizes [4,6,8]. Our histopathological findings were consistent with both acute and chronic inflammation with various degrees of infiltration and fibrosis [2]. Coffin et al. [4] in 1995 raised three basic histological patterns that can appear in the same tumor depending on the degree of spindle cell proliferation, the stroma background, and the infiltration of inflammatory cells [4,6]. The first is the myxoid or vascular pattern, which is characterized by loosely arranged spindle cells in the myxoid or edematous stroma with irregularly net-like and dilated small vessels; hence, it often resembles nodular fasciitis and contains more polymorphonuclear leukocytes, such as neutrophils and eosinophils, and fewer plasma cells compared with the other patterns. The second is the compact spindle cell pattern, which is identified by the proliferation of spindle cells with dominant plasma cell infiltration. When the amount of collagen increases in the stroma, the differential diagnosis should include fibrous histiocytoma, fibromatosis, or smooth muscle neoplasm. The final one is the hypocellular fibrous pattern, which is characterized by its relatively hypocellular density with elongated spindle cells and a higher density of collagen and focal calcification or metaplastic bone formation; hence, it can appear similar to a scar or desmoid fibromatosis [4,6].

According to immunohistochemistry, vimentin is positive in the spindle cells in most IPT cases; smooth muscle actin, muscle-specific actin, and desmin are positive in most cases; CD30, CD68, cytokeratin, p53, and KP-1 are positive in some cases; and CD15, CD-30, CD-245, and β -catenin are negative [2].

In conclusion, the groin masses are not common in the inguinal region. The image studies may give us much useful information but the appearance of those lesions would be nonspecific and thus increase the uncertainty. If we could not exclude the emergent condition like incarcerated hernia after careful history taking, physical examinations, or even radiologic studies, then surgical intervention should be considered, even if there are some possibilities of lesions in which are not required urgent surgery. We reported the rare case of IPTs clinically presented as incarcerated inguinal hernia. Post operation the patient recovered well and uneventful.

References

1. Abdelhak K, Youness A, Mohammed FT, Hinde E, Elmehdi T (2011) Inflammatory pseudotumor of the kidney: a case report. *Journal of Medical Case Reports* 5: 411.
2. Queiroz IN, Penna RMM, Mota EBR, Mota RT, Mota VT (2013) Inflammatory pseudotumor of the posterior mediastinum: *J bras pneumol* 39: 113-115.
3. Narla LD, Newman B, Spottswood SS, Narla S, Kolli R (2003) Inflammatory Pseudotumor. *RadioGraphics* 23: 719-729.
4. Coffin CM, Watterson J, Priest JR, Dehner LP (1995) Extrapulmonary

- inflammatory myofibroblastic tumor (inflammatory pseudotumor). A clinicopathologic and immunohistochemical study of 84 cases. *Am J Surg Pathol* 19: 859-872
5. Ryan GB, Cliff WJ, Gabbiani G, Irie C, Montandon D, et al. (1974) Myofibroblasts in human granulation tissue. *Human Pathology* 5: 55-67.
6. Gleason BC, Hornick JL (2008) Inflammatory myofibroblastic tumours: where are we now? *J Clin Pathol* 61: 428-437.
7. Constantino GDTL, Sasaki F, Tavares RA, Voegels RL, Butugan O (2008) Inflammatory pseudotumors of the paranasal sinuses. *The Brazilian Journal of Otorhinolaryngology* 74: 297-302.
8. Patnana M, Sevrukov AB, Elsayes KM, Viswanathan C, Lubner M, et al. (2012) Inflammatory Pseudotumor: The Great Mimicker 198: W217-227.
9. Umiker WO, Iverson L (1954) Postinflammatory tumors of the lung; report of four cases simulating xanthoma, fibroma, or plasma cell tumor. *J Thorac Surg* 28: 55-63.
10. Narla LD, Newman B, Spottswood SS, Narla S, Kolli R (2003) Inflammatory Pseudotumor. *RadioGraphics* 23: 719-72.
11. Coffin CM, Humphrey PA, Dehner LP (1998) Extrapulmonary inflammatory myofibroblastic tumor: a clinical and pathological survey. *Semin Diagn Pathol* 15: 85-101.
12. Coffin CM, Dehner LP, Meis-Kindblom JM (1998) Inflammatory myofibroblastic tumor, inflammatory fibrosarcoma, and related lesions: an historical review with differential diagnostic considerations. *Semin Diagn Pathol* 15: 102-110.
13. Gorospe L, Fernández-Gil MA, Torres I, Tovar J, García-Miguel P, et al. (2000) Misleading lead: inflammatory pseudotumor of the mediastinum with digital clubbing. *Med Pediatr Oncol* 35: 484-487.
14. Topçu S, Taştepe I, Alper A, Özgülger A, Albayrak M, et al. (2000) Inflammatory pseudotumors of the lung: a clinical study of eleven patients. *J Thorac Cardiovasc Surg* 119(1):180-182.
15. Medina AC, Gutiérrez DLPC, Gómez, Menchero J, Gutiérrez CE, et al. (2007) Multicentric inflammatory pseudotumor *Cir Esp* 81: 150-152.
16. Arber DA, Weiss LM, Chang KL (1998) Detection of Epstein-Barr virus in inflammatory pseudotumor. *Semin Diagn Pathol* 15:155-160.
17. Fernández VA, Mosteiro AM, Corbacho AD, Acuña FA, Piñero AL (1997) Pulmonary inflammatory pseudotumor: report of 2 cases and review of the literature *An Med Interna* 14: 469-472.
18. Lim D, Jeremiah C, Altuntas A, Sinnappu R, O'Sullivan R, et al. (2015) Pseudotumor After Metal-on-Metal Hip Arthroplasty. *J Am Geriatr Soc* 63: 1274-1276.
19. Park SB, Lee YS, Kim AY, Baik YH (2007) Inflammatory Pseudotumor of the Inguinal Lymph Node: A Case Report. *J Korean Radiol Soc* 57: 459-462.
20. Park SB, Cho KS, Kim JK, Lee JH, Jeong AK, et al. (2008) Inflammatory pseudotumor (myoblastic tumor) of the genitourinary tract. *AJR* 191:1255-1262.
21. Flisak ME, Budris DM, Olson MC, Zarling EJ (1994) Inflammatory pseudotumor of the liver: appearance on MRI. *Clin Imaging* 18: 1-3.
22. Materne R, Van Beers BE, Gigot JF, Horsmans Y, Lacrosse M, et al. (1998) Inflammatory pseudotumor of the liver: MRI with mangafodipyrtrisodium. *J Comput Assist Tomogr* 22: 82-84.
23. Kim JH, Cho JH, Park MS, Chung JH, Lee JG, et al. (2002) Pulmonary inflammatory pseudotumor-a report of 28 cases. *Korean J Intern Med* 17: 252-258.
24. Alongi F, Bolognesi A, Gajate AM, Motta M, Landoni C, et al. (2010) Inflammatory pseudotumor of mediastinum treated with tomotherapy and monitored with FDG-PET/CT: case report and literature review. *Tumori* 96: 322-326.
25. Shadbolt CL, Heinze SBJ, Dietrich RB (2001) Imaging of Groin Masses: Inguinal Anatomy and Pathologic Conditions Revisited. *RadioGraphics* 21: S261-S271.
26. Miserez M, Alexandre JH, Campanelli G, Corcione F, Cuccurullo D, et al. (2007) The European hernia society groin hernia classification: simple and easy to remember. *Hernia* 11: 113-116.
27. Fitzgibbons RJ, Forse RA "Clinical practice. Groin hernias in adults." *The New England journal of medicine* 372: 756-763.